

EXPERIENCE WITH THIRTEEN CASES OF RESECTION OF ANEURYSMS OF THE DESCENDING THORACIC AORTA

LAURENCE K. GROVES, M.D.

Department of Thoracic Surgery

THE fifteen years since the end of World War II have seen an unprecedented extension of knowledge and development of technics in virtually all fields of surgery. In no area has this development been more dramatic than in that of surgery of the great vessels. In this brief time, for all practical purposes, is encompassed the entire history of aortic surgery as we know it today. This paper discusses surgical experience with aneurysms in the descending thoracic aorta. Ten years ago, such aneurysms were hopeless problems and eventually were fatal. Now, definitive surgical cure is possible.

Many surgeons have made significant contributions to this field; however, the major credit for the technics described in this paper must go solely to the surgical group in Houston, Texas, under the leadership of Dr. Michael E. DeBakey. Each important phase of the technics described has been reported in every essential detail by this group.^{1,2}

Surgical resection for coarctation of the aorta, a procedure that is now more than 15 years of age, first established the feasibility of anastomotic procedures on this vessel; but resection, with either direct anastomosis or insertion of a graft, for coarctation differs from resection for aneurysm in one basic condition—the patient with coarctation is born with his aorta “clamped,” and with excellent collaterals around the obstruction. He thus can tolerate additional clamping of this area of the aorta for unhurried anastomotic procedures without significant hazard of ischemic problems to the spinal cord or to other vital organs distally distributed in the arterial tree. The patient with an aneurysm does not have comparable collaterals, and hence cannot tolerate protracted interruption of aortic flow. In the infancy of the surgery for aneurysm, this problem was partially overcome by the use of hypothermia, which significantly increases tissue tolerance to anoxia; but ‘racing the clock’ is apt to be hard for the surgeon as well as the patient. Sudden clamping of the thoracic aorta also imposes an abrupt increase in work on the heart, which may not be well tolerated if significant heart disease is present.

The current means of defeating the time problem are shunt procedures to bypass a portion of the circulating blood around the obstruction during the operative procedure. Some of these shunts are taken down at the completion of the operative procedure; in other instances the shunts are left in situ to function as the new aortic channel after the aneurysm has been resected and the remaining aortic ends have been closed.

Our experience at the Cleveland Clinic Hospital is confined to one particular type of shunt with which we are eminently satisfied, and with which we have had no technical difficulties. This shunt was developed by Doctor DeBakey and his colleagues.^{1,2} The shunt runs from the left atrium to a common femoral artery. The left atrium contains oxygenated blood; no oxygenator is necessary. A simple pump is needed to maintain a flow of blood from the low-pressure left atrium into the peripheral arterial circuit.

Technically, we have found it simplest to insert a plastic cannula retrograde into a common femoral artery through a small incision in the groin before commencing the operative procedure. This necessitates heparinizing the blood of the patient at this time. As soon as the chest is opened, a pericardial incision is made to expose the left atrial appendix, and a similar cannula is inserted into the left atrium through a purse-string suture around the tip of its appendix. These cannulae are then connected through a pump, and all is in readiness to perfuse the lower half of the body should circumstances dictate rapid occlusion of the aorta proximal to the aneurysm (*Fig. 1*).

We have confirmed the experience of others² that a flow of 20 ml. per kilogram of body weight per minute through this shunt is adequate, and have seen no evidence of ischemic changes to the nervous system or the kidneys. The operator of the pump has some control over the patient's blood pressure, proximal to the aortic clamp, by varying the pump speed and thus controlling the volume of blood that is "bled-off" from the heart. In our experience, a flow of 30 ml. per kilogram of body weight will lower the arm blood pressure below normal. This shunt is out of the way of the operative field and is readily taken down when the need for it has passed. The only possible objection to it is that the operation must be performed on a heparinized patient, though this has not proved to be a technically important drawback. We discontinue the shunt flow and neutralize the heparin with protamine immediately upon re-establishing aortic continuity with a graft.

Aneurysms involving the ascending aorta and the take-off of the major aortic branches in the arch pose a perfusion problem and a technical problem that are much more complicated than those involving aneurysms occurring distally to the take-off of the left common carotid artery. The shunt system described above allows the patient's normal circulation to perfuse the brain when the aorta is clamped to the left common carotid artery origin. Any aortic aneurysm proximal to the left subclavian artery, unless it is a lateral saccular aneurysm that can be treated by simple aneurysmorrhaphy after cross-clamping its base, necessitates the use of additional shunts to the carotid arteries with or without the use of a pump and an oxygenator, and total cardiac bypass. After the perfusion problems the excision and the graft replacement also may be extremely complicated.

Surgical mortality in such cases is high, and successfully treated cases con-

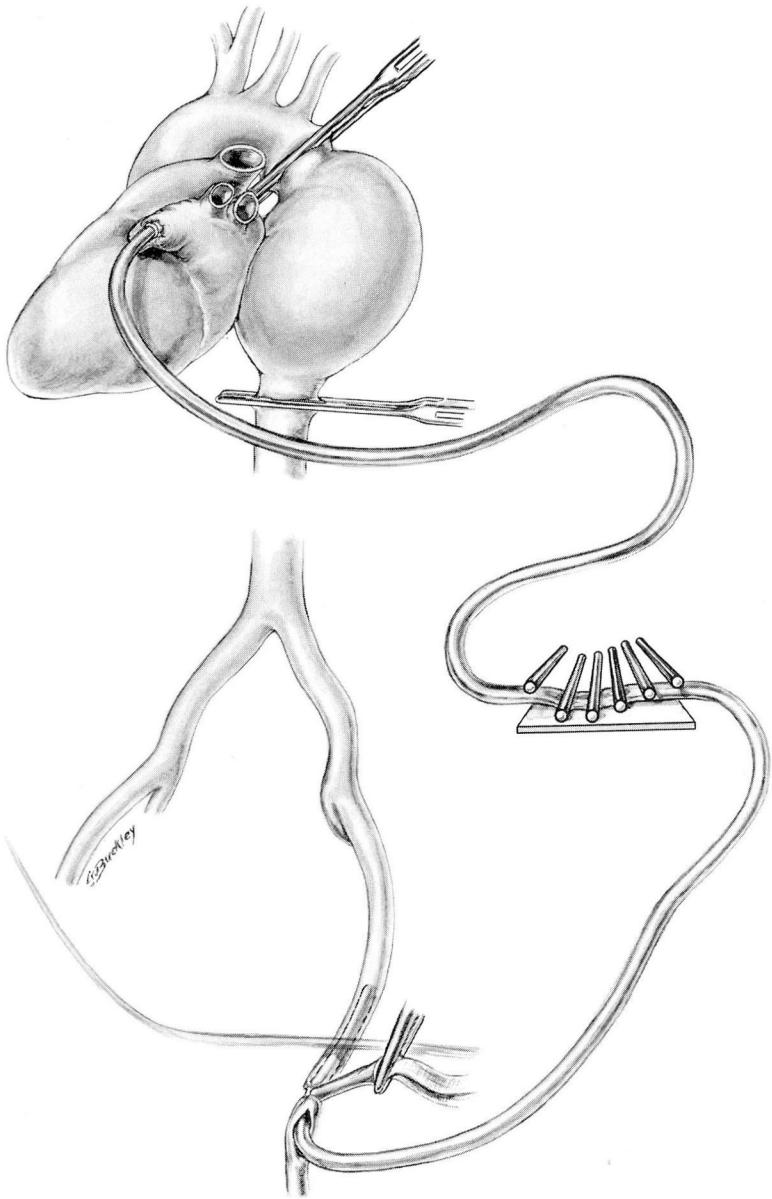


Fig. 1. Graphic demonstration of the left-sided shunt bypass used in the cases described. It is readily seen how oxygenated blood withdrawn from the left atrium is pumped into the distal arterial tree to make indefinite periods of aortic occlusion tolerable.

stitute only isolated case reports.³⁻⁹ As opposed to the gratifying salvage that may be anticipated like those discussed below, the factors mitigating against success in an aortic arch aneurysm must be carefully evaluated before accepting an individual case for surgery. I should like to make a plea, however, for exceedingly careful delineation of the extent of almost every aortic aneurysm, as frequently an aneurysm that appears to fill the mediastinum and almost certainly to involve the arch, when it is delineated by contrast medium study, is found in actuality to arise in a favorable location distally to the origin of the cerebral circulation (*Fig. 2*).

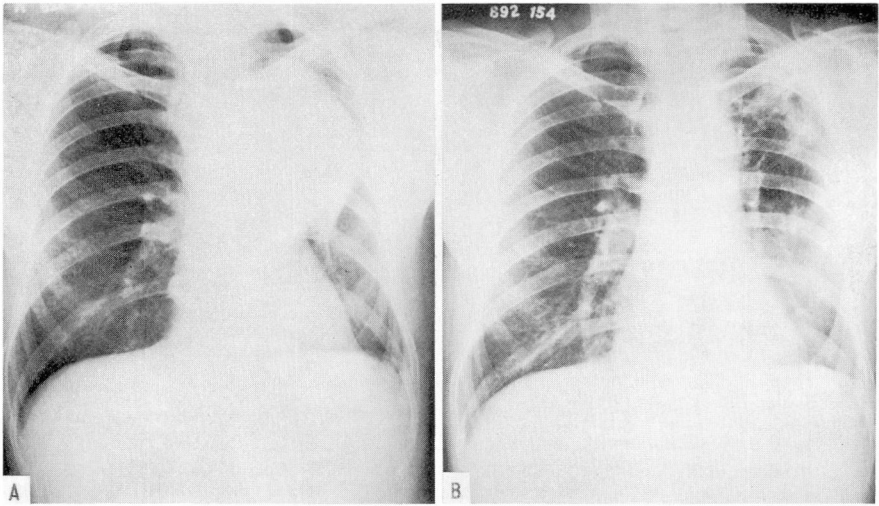


Fig. 2. A, Preoperative, and B, postoperative roentgenograms of a 52-year-old man who had severe respiratory obstruction. Bronchoscopically the terminal tracheal region was greatly narrowed and distorted. Selective cineangiographic visualization of the aortic arch in this patient proved the aneurysm to arise distally to the left subclavian artery, and therefore it was eminently suitable for resection. The resection was complicated by distortion of the left pulmonary hilar structures over the aneurysmal wall; the left main pulmonary artery was traumatized, but could be reconstructed.

Surgical Experience

Within the past four years the author has had personal experience with 13 patients (*Table 1*) in whom the left atrial-femoral arterial shunt was utilized exactly as described. In each patient the shunt was prepared for function as the initial stage of the operative procedure, and in every patient its use proved necessary. To date no patient was misjudged insofar as the indications for this shunt are concerned. That is to say, no patient underwent exploration without the shunt's being available and found to be necessary, nor has the shunt been set up and not been needed. If one maintains a high index of suspicion of aneurysm in the differential diagnosis of mediastinal masses, he will avoid exploration of unsuspected aneurysms (*Fig. 3*).

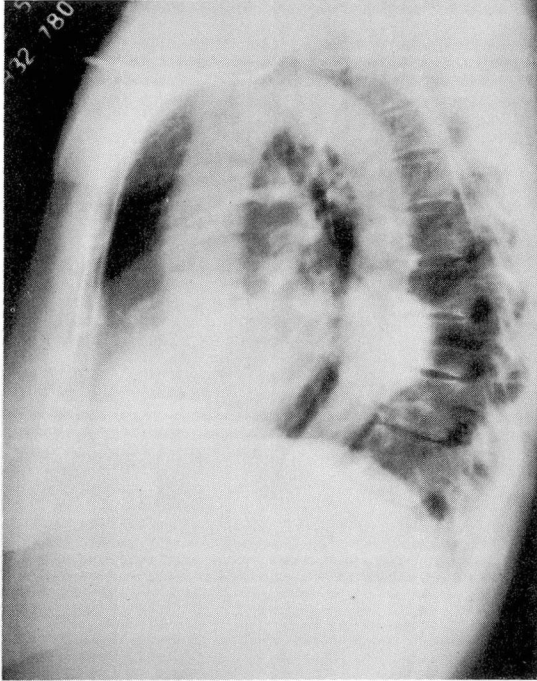


Fig. 3. This venous angiographic film demonstrates an asymptomatic descending aortic aneurysm. On a conventional film this shadow appeared as evidence of an undiagnosed posterior mediastinal mass. In case of doubt, studies of this kind are valuable, in order to avoid exploring an undiagnosed aneurysm.

No aneurysm in the thoracic aorta distal to the left common carotid artery has been encountered which did not require aortic occlusion and the use of a shunt, although such aneurysms do occur.

From histopathologic evidence, 10 of the 13 aneurysms are considered to have been of arteriosclerotic origin. Of the 10, two were dissecting aneurysms sufficiently localized so that the entire dissection was resected in each case. An additional two patients of the group had positive serologic tests and fairly conclusive evidence of syphilis; however, the histopathologic findings were solely those of arteriosclerosis. Of the other three aneurysms, one was syphilitic (*Fig. 4*), and two were posttraumatic in origin. One posttraumatic aneurysm was related to a remote history (10 years) of chest trauma in an automobile accident, the significance of which was fully appreciated only when the aortic specimen was examined and showed a smooth circumferential discontinuity of the aortic intima a short distance distal to the left subclavian artery take-off. This is the typical location for such aortic aneurysms.¹⁰

Of the 13 patients, 10 survived to leave the hospital. Of these 10 patients,

three subsequently died. One died three years after surgery; a chain of aneurysms involving the entire aorta and femoral arterial system had developed. His death was associated with massive hematemesis, presumably representing rupture of an aneurysm into the gastrointestinal tract. One death after the patient was discharged from the hospital was associated with upper gastrointestinal hemorrhage two months after operation. An autopsy at another hospital is said to have shown the graft to be completely intact and that the bleeding was unrelated to it, but was associated with a hiatus hernia. We had known of the presence of a hiatus hernia; however, it was believed at the time of his aortic surgery to be unwise to increase the scope of the operation. One late death occurred eight weeks after operation; the patient was an extremely cachectic 69-year-old man who was readmitted to the hospital because of deficient wound healing and inanition. A tracheotomy wound was larger than when the tube had been removed six weeks previously. An empyema developed in the operative field, and at postmortem, after exsanguination via the site of empyema drainage, the empyema was found to extend to the graft and to the localized leak at the distal anastomosis. We do not consider this a case of primary graft failure.

There were three postoperative hospital deaths in this series of patients. One death occurred eight hours after operation in a 33-year-old man, the youngest in the group, who had a posttraumatic aneurysm. It became apparent that he was having massive hemorrhage into the operated left hemithorax. He was returned to the operating room and the chest was rapidly reopened. The hemithorax was full of blood. It was impossible to resuscitate the circulation, which failed coincident with reopening the chest. We were unable to demonstrate the point of this bleeding satisfactorily either at the time of the reoperation or at the postmortem. The aortic suture lines were intact. The second death in the hospital was due to an acute enteritis, and occurred one week after operation. The patient was treated intensively with novobiocin;* and at postmortem no staphylococci could be cultured, but presumably they were the infecting organisms. The third death in the hospital occurred in an abrupt fashion approximately one-half hour after the completion of the operation. The patient was a 68-year-old woman with a dissecting aneurysm (*Fig. 5*). During resuscitative efforts a left hemothorax was encountered. At postmortem she was found to have a new and separate acute full-thickness dissection approximately 1 cm. above the proximal anastomosis. Probably her degenerative (atherosclerotic) aortic disease did not tolerate the occlusive clamp that lay at approximately this level during the operative procedure.

In addition to these three fatal complications, three other major postoperative complications occurred which were successfully overcome. In one patient, approximately 10 days postoperatively, roentgen evidence of a localized hemothorax was

* *Albamylin (novobiocin sodium)*, *The Upjohn Company*.

Table 1.—*Data in thirteen cases of resection of aneurysms of the descending thoracic aorta—Cleveland Clinic Hospital*

Case number	Age, years	Sex	Symptoms	Cause	Date of operation, month/year	Type of graft
1	59	M	Pain	Arteriosclerosis	7/57	Homograft
2	33	M	None	Trauma	8/57	Homograft
3	56	F	None	Arteriosclerosis	6/58	Homograft
4	49	M	None	Arteriosclerosis	6/58	Homograft
5	53	M	None	Arteriosclerosis	10/58	Homograft
6	58	M	Acute back pain	Dissecting arteriosclerosis	10/58	Dacron
7	50	M	Pain	Arteriosclerosis (positive serologic test)	3/59	Dacron
8	57	M	Severe pain	Arteriosclerosis (positive serologic test)	4/59	Dacron
9	49	M	Pain	Syphilis	2/60	Homograft
10	68	F	Pain	Dissecting arteriosclerosis	5/60	Dacron
11	52	M	Respiratory obstruction	Arteriosclerosis	9/60	Dacron
12	69	M	Pain	Arteriosclerosis	2/61	Dacron
13	47	F	None	Trauma	3/61	None, end-to-end anastomosis

seen, indicative of a late anastomotic leak. This was the first patient in the series and, although probably now he should undergo reoperation, his only treatment was several needle aspirations. It was gratifying to see the hemothorax progressively shrink and eventually disappear. Another patient had to be returned to the operating room 18 hours after the completion of his operation because of persistent bleeding. The bleeding was from veins in the posterior mediastinum related to the hemi-azygos system.

The third major complication was a hemorrhagic diathesis first noticed coincident with the completion of the operative procedure. This man bled not only from the wound but also from the upper gastrointestinal tract and the tracheobronchial tree. Early postoperative roentgenograms showed evidence of diffuse bilateral parenchymal pulmonary hemorrhage. Laboratory study revealed no hemolysis; his clotting time was normal; fibrinogen was normal. The prothrombin time was moderately prolonged. He was given eight direct fresh-blood transfusions immediately after surgery, which solved the bleeding problem; however, it was necessary to support his respiration artificially via a cuffed tracheotomy tube for five days while pulmonary changes resolved.

Table 1.—*Concluded*

Case number	Complications	Result	Follow-up
1	Late leak	Good	Died 3 yr. postoperatively
2	Postoperative bleeding	Postoperative death	—
3	None	Good	Living and well
4	None	Good	Living and well
5	Enteritis staphylococcus (?)	Died 1 wk. postoperatively	—
6	Reoperation for bleeding	Good	Died 2 m. postoperatively, gastrointestinal bleeding
7	None	Good	Living and well
8	None	Good	Living and well
9	Hemorrhagic diathesis	Good	Living and well
10	Postoperative dissection, chemothorax	Postoperative death	—
11	None	Good	Living and well
12	Late empyema		Died 2 m. postoperatively
13	None	Good	Living and well

Comments on Technic

The major hazard in aneurysm surgery is that of hemorrhage, which will usually be from the aneurysm itself. To minimize this hazard we believe that it is important before actual dissection of the aneurysm to attempt to mobilize and to encircle with tapes the aorta proximally and distally to the pathologic area. As has been discussed, the shunt's having already been prepared, one is ready to occlude the aneurysm from the circulation and to utilize the shunt at a moment's notice. With the situation under control in this fashion, dissection of the aneurysm proper can be carried out with relative safety, and frequently the entire aneurysm can be mobilized before occluding the aorta. When the aneurysm proves to be adherent to the hilum of the lung, or it invades the vertebral bodies, the surgeon should early abandon circumferential dissection, should occlude the aorta, should divide the aneurysm at one or both ends, and should excise it from above downward leaving in situ any segment of wall the removal of which seems unusually hazardous.

This approach may greatly reduce operating time and, with the bulk of the aneurysm removed, more delicate dissection of critical areas can be readily carried out.

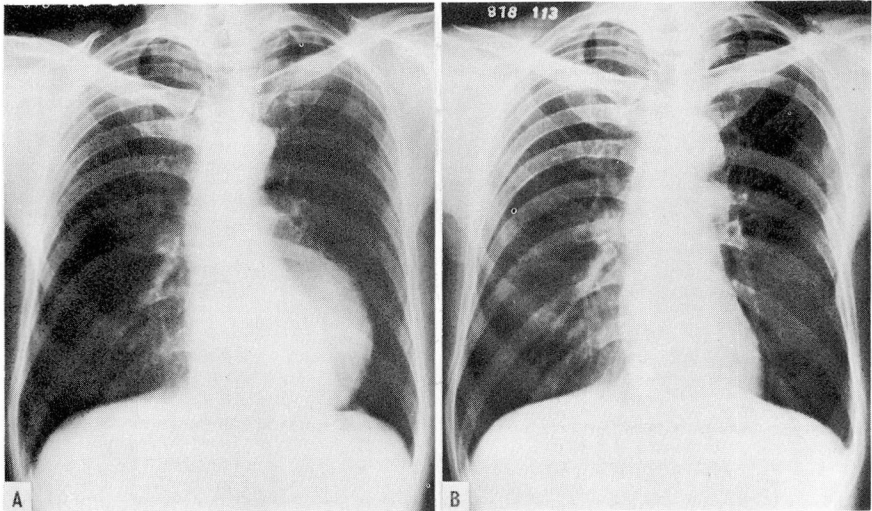


Fig. 4. A, Preoperative, and B, postoperative roentgenograms of the only definitely syphilitic aneurysm in the reported series of patients. Syphilitic aneurysms do occur distally to the aortic arch. Radicular back pain was this patient's only significant symptom.

An area where extremely troublesome bleeding can occur lies between the aorta and the vertebral bodies. This area is traversed by the hemi-azygos venous system, which is highly variable and seems to dilate in these cases, as if obstructed by the aneurysmal mass. Bleeding from this area necessitated reoperation in one patient and may have been the cause of one postoperative death. Ideally the surgeon should keep his plane of dissection close enough to the aneurysm to avoid these veins, but unfortunately what amounts to a venous lake may be inadvertently entered. Pressure in these channels is low, and bleeding can be readily controlled by packing; but before completion of surgery, all tributaries to such a lake must be carefully suture ligated.

This operative experience covers the time interval during which there has been transition from freeze-dried homografts to the use of woven crimped Dacron prostheses at the Cleveland Clinic. In six patients a homograft was used and in six patients Dacron was used. To date, both have been equally satisfactory. There have been no early or late graft failures.

One case of traumatic aneurysm was treated by direct end-to-end anastomosis without graft. On opening this aneurysm the two ends of the aorta were readily apparent, separated by more than 2 inches, and connected by a fusiform false aneurysm. After trimming away the false sac, there was sufficient residual elasticity to the aorta (one year after an auto accident) to permit direct suture approximation (*Fig. 6*).

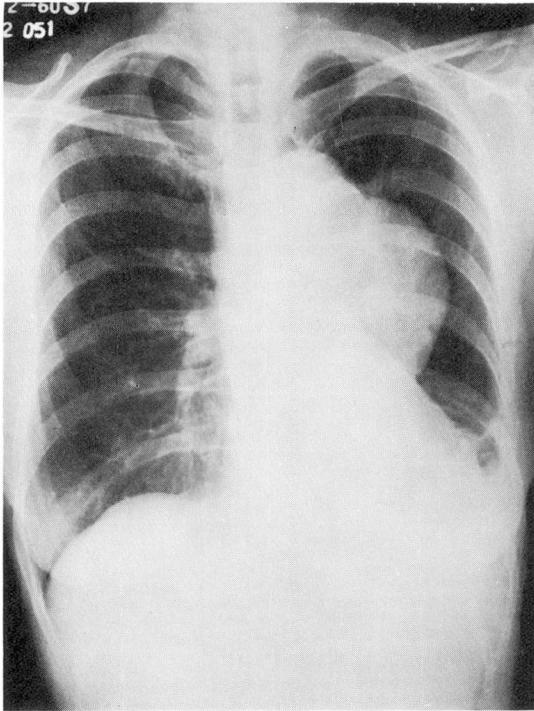


Fig. 5. Roentgenogram of what proved to be a localized dissecting aneurysm in a 68-year-old woman. Operative removal and graft were uneventful, but in the immediately postoperative period in this patient a fresh full-thickness dissection developed immediately above the upper anastomotic line, and she died.

Discussion

The ultimate fate of any untreated aneurysm in the chest, as elsewhere, is steady enlargement and eventual rupture. This sequence may require a varying time and may be delayed by laminar mural thrombus. The life history of an aneurysm may be complicated by pain from bone erosion, mechanical interference with adjacent viscera, and rarely peripheral emboli from intraaneurysmal thrombus.

Evidence of an aneurysm may be an incidental finding in a roentgenogram of the chest. Such an asymptomatic aneurysm is apt to be the simplest to deal with technically, as the lack of symptoms suggests absence of encroachment on adjacent structures. Once an aneurysm becomes symptomatic, the symptoms tend to become progressive and intractable, and the surgical indications become urgent (*Fig. 7*).

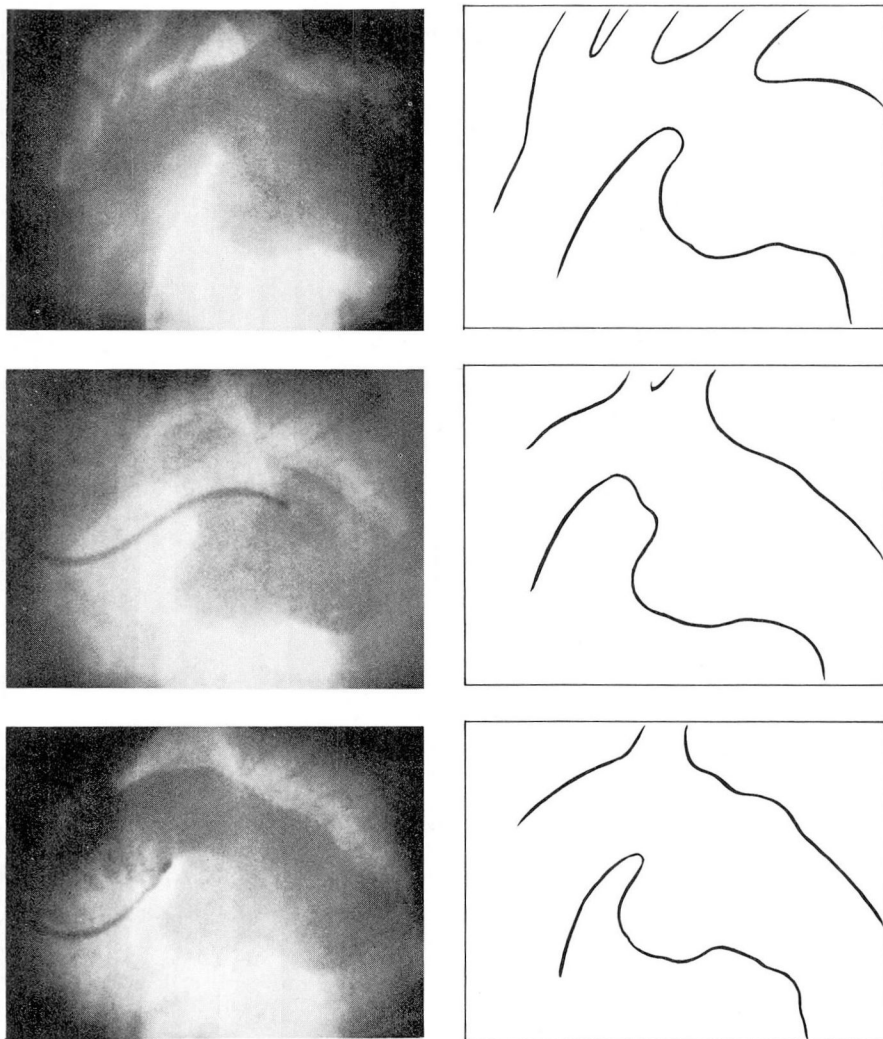


Fig. 6. The three photographs on the left represent enlargements of individual frames of 35-mm. motion picture films of selective cineangiographic studies in a 47-year-old woman, one year after an automobile accident. The line drawings on the right are tracings from the same frames to orient the findings. This is the typical location for traumatic aneurysm of the thoracic aorta. When this aneurysm was opened it was found to be a false aneurysm containing the two ends of aorta separated by just more than 2 inches. The false aneurysm was trimmed away and a direct end-to-end anastomosis was made.

The initial formation of an aneurysm requires the presence of a weak area in the aortic wall, which bulges or fractures under the pressure of the contained

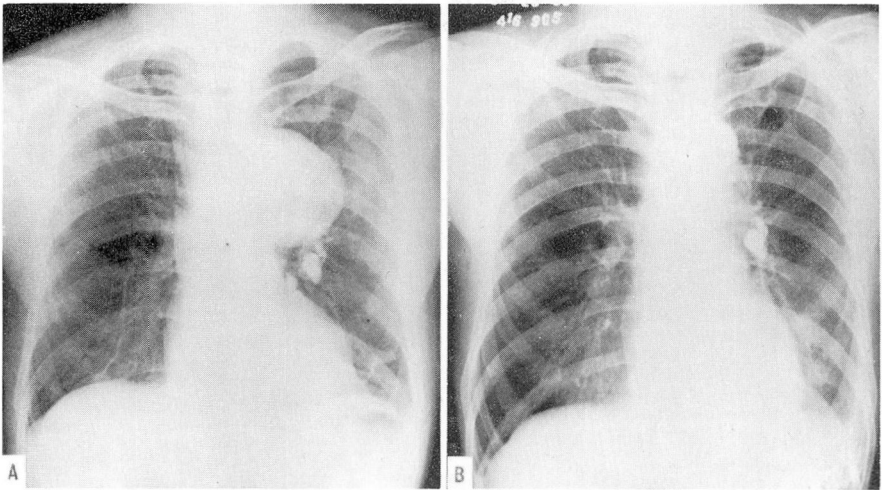


Fig. 7. A, Preoperative, and B, postoperative roentgenograms in a 57-year-old professional golfer. The patient's hospitalization was precipitated by severe, progressive, chest pain, and this aneurysm is known from serial roentgenograms to have enlarged rapidly. At operation there were several areas of extreme thinness, and rupture was imminent.

blood. The pathogenesis of this weak area may be due to diseases such as arteriosclerosis or syphilis, or to trauma; however, once the enlarging has commenced, physical principles readily explain why steady progression will then occur. Bernoulli's principle states that in a flowing hydraulic system the pressure is inversely proportional to the speed of flow. An aneurysmal segment of vessel has an increased cross-sectional area; therefore, flow velocity is lowered, and the pressure is higher than in the vessel of normal caliber at either side. LaPlace's law states that with equal pressure the tension in the wall of a vessel is proportional to its radius; hence, if the aneurysm has double the radius of the host aorta, the tension in its wall will be double that in the aorta per se. Thus, when a weak area commences to dilate, hydraulic principles place a steadily increasing stress on the wall, and a vicious cycle is initiated.

The facts discussed above give strong objective arguments for resection of aneurysms. The surgeon knows, however, that in most instances he is operating on an elderly patient with degenerative vascular disease. He is entitled to use his discretion in accepting patients for this type of surgery, as patients will be seen in whom there is extremely small "salvage value." However, one is obliged to offer surgery to most of these patients, and, in view of the demonstrated success in the present relatively small series, we expect to be increasingly confident in advising operation for such patients in the future.

Summary and Conclusions

Surgical experience with 13 patients with aneurysms of the descending thoracic aorta is reviewed. Of these 13, seven are still living. Three patients died post-operatively in the hospital, and three deaths occurred late, as long as three years after operation. A bypass from the left atrium to the femoral artery for the maintenance of distal aortic circulation during occlusion was used in all of these patients, and has been proved to be highly satisfactory.

Inasmuch as most of the patients were elderly, and underwent operation for degenerative (atherosclerotic) disease, the over-all results are gratifying.

References

1. Cooley, D. A.; DeBakey, M. E., and Morris, G. C., Jr.: Controlled extracorporeal circulation in surgical treatment of aortic aneurysm. *Ann. Surg.* 146: 473-485, 1957.
2. DeBakey, M. E.; Cooley, D. A.; Crawford, E. S., and Morris, G. C., Jr.: Aneurysms of thoracic aorta; analysis of 179 patients treated by resection. *J. Thoracic Surg.* 36: 393-420, 1958.
3. Stranahan, A.; Alley, R. D.; Sewell, W. H., and Kausel, H. W.: Aortic arch resection and grafting for aneurysm employing external shunt. *J. Thoracic Surg.* 29: 54-65, 1955.
4. Cooley, D. A.; Mahaffey, D. E., and DeBakey, M. E.: Total excision of aortic arch for aneurysm. *Surg. Gynec. & Obst.* 101: 667-672, 1955.
5. DeBakey, M. E.; Crawford, E. S.; Cooley, D. A., and Morris, G. C., Jr.: Successful resection of fusiform aneurysm of aortic arch with replacement by homograft. *Surg. Gynec. & Obst.* 105: 657-664, 1957.
6. Miller, W. H., Jr.; Warren, W. D., and Blanton, F. S., Jr.: Method for resection of aortic arch aneurysms. *Ann. Surg.* 151: 225-230, 1960.
7. Ellison, R. G.; Cope, J. A., and Moretz, W. H.: Technical problems in surgical repair of intra-thoracic aneurysms. *J. Thoracic & Cardiovas. Surg.* 39: 486-499, 1960.
8. Bahnson, H. T., and Spencer, F. C.: Aneurysms of ascending aorta with prosthetic replacement during cardiopulmonary bypass. *Ann. Surg.* 151: 879-890, 1960.
9. Spiekerman, R. E., and McGoon, D. C.: Aneurysm of ascending aorta with obstruction of superior vena cava: report of case with resection using extracorporeal circulation. *Dis. Chest* 37: 675-679, 1960.
10. Spencer, F. C.; Guerin, P. F.; Blake, H. A., and Bahnson, H. T.: Report of fifteen patients with traumatic rupture of thoracic aorta. *J. Thoracic & Cardiovas. Surg.* 41: 1-22, 1961.