

RENAL ARTERIOVENOUS FISTULA: OCCURRENCE IN RENAL-CELL CARCINOMA

Report of a Case

C. EDWARD B. ABBOTT, M.D.,* and EUGENE F. POUTASSE, M.D.

Department of Urology

RENAL arteriovenous fistula is a disorder of exceptional clinical interest because it is rare and produces unusual physical and roentgenographic findings. Of the 15 cases of arteriovenous fistula of the kidney reviewed by Scheifley, Daugherty, Greene, and Priestley,¹ in only three cases was there associated renal-cell carcinoma. We are reporting a (fourth) case in which an intra-renal fistula occurred in a renal-cell carcinoma, with the typical clinical features of the renal-vascular syndrome.

Clinical Features

Scheifley² states that there are four outstanding clinical features that comprise the renal-vascular syndrome typical of this unusual disease. These are: (1) *continuous bruit* heard diffusely over the upper abdomen or flank; (2) *hypertension*;† (3) *cardiomegaly*, which was present in 12 of the 15 patients; and (4) *heart failure*, which occurred in 10 patients. He points out that because of these clinical features a renal arteriovenous fistula is distinguishable from a peripheral arteriovenous fistula.

Report of a Case

A 62-year-old woman was referred to us by Dr. Adib H. Karam of Canton, Ohio, because of his diagnosis of arteriovenous fistula of the right kidney. In January, 1960, the patient experienced the sensation of a mass in the upper abdomen, but physical examination revealed only an increased resistance in this region on palpation. Ten months later she was re-examined by Doctor Karam because of a similar complaint, and at that time a mass was palpable in the right upper quadrant and flank. Further examination revealed a blood pressure of 206/110 mm. of Hg, cardiomegaly, with an apical systolic murmur, crepitant rales in both lung fields, and a loud continuous bruit over the right flank and the anterior upper abdomen.

An intravenous urogram revealed evidence of a massive right kidney with two elongated and distorted calyces (*Fig. 1*). Retrograde pyelography confirmed the presence of a large right renal mass with dilatation of all calyces and the renal pelvis, which were displaced medially along with the ureter by the mass that occupied the normal renal fossa. The chest roentgenogram revealed the heart size to be 40 per cent above

*Fellow in the Department of Urology.

†It is not clear to us what type of hypertension is characteristic of the syndrome.

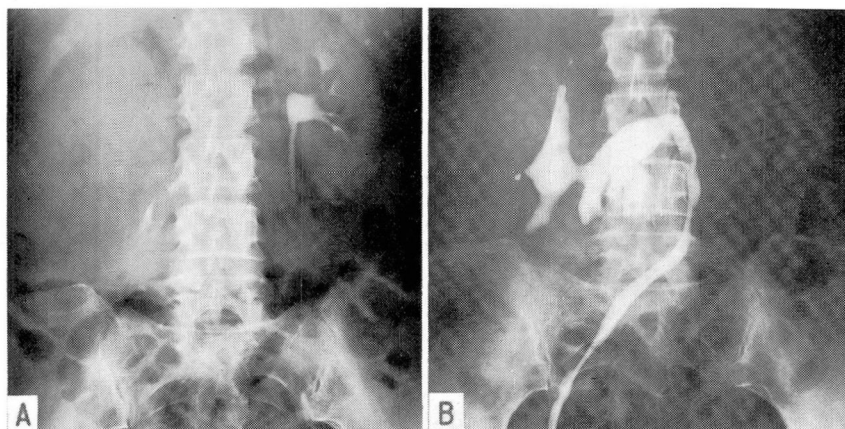


Fig. 1. A, Intravenous pyelogram showing evidence of a massive right kidney with two elongated and distorted calyces. B, Retrograde pyelogram demonstrating evidence of dilatation of all calyces and the renal pelvis with medial displacement of the right kidney and the ureter. (Courtesy of Dr. Adib H. Karam, Canton, Ohio.)

average. While in the hospital in Canton the patient received a transfusion of blood in preparation for surgical treatment, but severe pulmonary edema developed after only 200 ml. of blood had been administered; the operation was postponed. A second intravenous pyelogram in December, 1960, revealed evidence of further enlargement of the right renal mass and, because of the diagnosis of arteriovenous fistula in the kidney, she was referred to the Cleveland Clinic for angiography and possible surgery.

The main physical findings were hypertension (blood pressure ranged from 198/104 to 195/80 mm. of Hg); cardiomegaly; a large, rounded, somewhat soft mass in the right upper quadrant; and a loud continuous bruit heard most distinctly over the upper abdomen and the right flank. Examination of the ocular fundi revealed a grade 1 constriction and grade 2 sclerosis of the retinal arterioles. Results of pertinent laboratory procedures were: blood volume determination (Evans blue method)—total plasma volume of 57.2 ml. per kilogram of body weight (normal range, 37 to 39 ml.), total blood volume of 95.8 ml. per kilogram of body weight (normal range, 65 to 69 ml.), total red blood cell volume of 38.6 ml. (normal range, 27 to 29.9 ml.), and cell volume of 42 ml.; a decreased circulation time; electrocardiographic evidence of left ventricular hypertrophy. Renal angiography demonstrated evidence in the right kidney of a large mass traversed by numerous dilated vessels, and a large pool of contrast medium in the center, which was believed to represent an arteriovenous fistula within a renal tumor (Fig. 2).

The patient underwent operation on January 12, 1961. Through a right subcostal incision the abdomen was examined transperitoneally, and a large retroperitoneal mass was found underneath the liver. With the hepatic flexure retracted to the midline, and the retroperitoneum open, a large, tense, renal mass covered with dilated vessels was exposed. Two large renal veins were dissected free, also an unusually large renal artery. When the renal veins, and what appeared to be the only renal artery, were

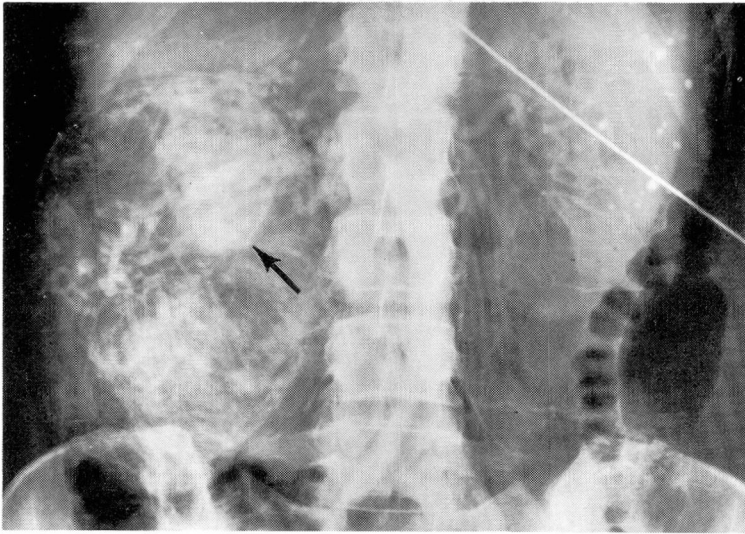


Fig. 2. Renal angiogram showing evidence of numerous dilated vessels traversing the large renal mass, and a large pool of contrast medium (arrow) representing an arteriovenous fistula.

divided, the neoplastic mass suddenly enlarged, indicating the presence of collateral circulation. The tumor was quickly removed intact and all bleeding was controlled. The patient required a transfusion of three units of whole blood to maintain a steady blood pressure during the operative procedure.

Pathologic examination revealed a kidney that weighed 640 gm., 17 cm. by 11 cm. by 6 cm., with a 7-cm. segment of ureter. In the upper pole of the kidney there was a tumor 14 cm. by 10 cm. by 5 cm. On section (*Fig. 3*) the tumor was orange, and contained cystic areas in the center of which was a rectangular-shaped cavity, 4 cm. by 5 cm. by 4 cm., lined with endothelium. It was partly filled with organized blood clot and soft tumor. Upon removal of the clot the renal artery and the renal vein were seen to enter directly into this cavity. Microscopic examination confirmed the diagnosis of renal-cell carcinoma, well differentiated, with gross intravenous invasion.

On follow-up examination the patient's blood pressure ranged from 160/100 mm. to 155/95 mm. of Hg; the bruit had disappeared; there was a noticeable decrease in cardiac size (now only 30 per cent above average) according to the chest roentgenogram; and all signs of heart failure had disappeared. Eight months postoperatively the patient is well and shows no sign of recurrent tumor.

Comment

Since our patient had the syndrome described by Scheifley² the diagnosis of arteriovenous fistula of the kidney was apparent from the physical examination alone. Although the intravenous urogram showed a large renal mass, the exact nature of the enlargement was not clear until the angiogram showed evidence

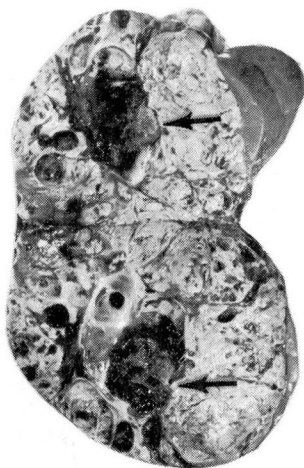

Fig. 3. Section of the neoplastic mass with an endothelial-lined cavity in the center (arrows) representing the arteriovenous fistula, and partly filled with tumor and organized blood clot.

typical of a renal tumor. The preoperative blood pressures showed a wide range of pulse pressures, from 94 to 115 mm. of Hg with variable diastolic pressures from normal to slightly elevated.

In the cases reviewed by Scheifley, Daugherty, Greene, and Priestley,¹ a considerable range of blood pressures was observed in the 12 patients whose preoperative blood pressures were recorded. Systolic hypertension without any diastolic elevation was present in seven patients, and just two of these patients were over 42 years of age. Diastolic hypertension occurred in five patients all of whom were under 40 years of age. Because the diastolic hypertension was relieved in all five patients postoperatively, as reported by Scheifley,² and systolic hypertension was reported in the other seven patients as in our patient, there does seem to be a relationship between hypertension and arteriovenous fistula of the kidney. However, to date there seems to be no characteristic form of hypertension in patients with renal arteriovenous fistula.

Cardiomegaly and heart failure are not peculiar to renal arteriovenous fistula, as these features can occur in a patient with a large arteriovenous fistula anywhere in the body, or with renal arterial occlusive disease and hypertension. In a patient with renal arterial occlusive disease and hypertension, a systolic bruit, heard best in or near the epigastric region, is often present. Therefore, it is important, as Scheifley² points out, to recognize the continuous character of the abdominal bruit, with systolic accentuation, as this appears to be the only distinctive feature associated with arteriovenous renal fistula. It would seem that the renal vascular syndrome is not such a clear-cut clinical entity as emphasized by Scheifley.²

The intravenous urogram is of great value in the diagnosis of arteriovenous

fistula. In all but one of the reported cases in which intravenous urography was used, evidence of an abnormality was revealed on the urogram. Renal angiography is the procedure that should establish the diagnosis beyond a doubt. In our patient not only was there evidence of urographic deformity and angiographic vascularity of a renal tumor, but also angiographic evidence of a large central pool that could result only from an abnormal arteriovenous communication. Specific laboratory tests can be used to substantiate further this diagnosis; they are: (1) blood volume determination, which should show a significant increase; (2) circulation time, which should show a decrease; and (3) catheterization of the vena cava and renal vein to demonstrate arterialization of the venous blood.

There are several varieties of arteriovenous fistula of the kidney, and they are classified according to etiopathogenesis. The *intrarenal* type is found within the kidney, and either is of congenital origin, or is acquired from direct trauma to the kidney or from breakdown of a tumor with formation of an abnormal arteriovenous communication. The *extrarenal* type is found outside the kidney, and also is either of congenital origin, possibly the result of erosion into the vein of a congenital aneurysm of a renal artery, or from traumatic injury to the renal artery and renal vein, which results in a fistula. A *postnephrectomy* type of arteriovenous fistula occurs occasionally in the stump of the renal artery and renal vein, probably where a single ligature was used to secure the renal pedicle. A search of the literature has revealed seven reported instances of this type of fistula.³⁻⁸ All of these types of fistula are rare,¹⁻⁹ as shown by the data in *Table 1*, but the recent

Table 1.—*Renal arteriovenous fistula. Cases include twenty-three reported,¹⁻⁹ and one case from the Cleveland Clinic Hospital*

Type of fistula	Number of cases	
	Total	Subtotal
Intrarenal	9	
Congenital		3
Acquired		6
Trauma		(3)
Neoplasm		(3)
Extrarenal	8	
Congenital		4
Acquired		4
Trauma		(3)
Neoplasm		(1)
Postnephrectomy	7	

use of diagnostic aortography accounts for the fact that most of the documented cases have been discovered during the last decade.

Summary

A case report is presented of a patient who had an intrarenal arteriovenous fistula of the kidney, found within a renal-cell carcinoma, which produced a continuous abdominal bruit, systolic hypertension, cardiomegaly, and heart failure. Three other case reports of fistulas that occurred in renal tumor have been found in the literature. In our opinion the only really distinctive feature of an arteriovenous renal fistula is the continuous bruit heard over the renal area, and therefore must be differentiated from the systolic bruit of occlusive renal artery disease, of aneurysms, or of partial occlusive disease occurring in other intraabdominal vessels. The renal vascular syndrome at the present time is not a clear-cut clinical entity, particularly since the blood pressure may be only mildly elevated in the majority of cases.

References

1. Scheifley, C. H.; Daugherty, W.; Greene, L. F., and Priestley, J.: Arteriovenous fistula of kidney; new observations and report of three cases. *Circulation* 19: 662-671, 1959.
2. Scheifley, C. H.: New clinical syndrome producing hypertension—arteriovenous fistula of kidney. *J.A.M.A.* 174: 1625-1627, 1960.
3. Muller, W. H., Jr., and Goodwin, W. E.: Renal arteriovenous fistula following nephrectomy. *Ann. Surg.* 144: 240-244, 1956.
4. Schwartz, J. W.; Borski, A. A., and Jahnke, E. J.: Renal arteriovenous fistula. *Surgery* 37: 951-958, 1955.
5. Hollingsworth, E. W.: Arteriovenous fistula of renal vessels. *Am. J.M.Sc.* 188: 399-403, 1934.
6. Elliott, J. A.: Post-nephrectomy arteriovenous fistula. *J. Urol.* 85: 426-427, 1961.
7. Poutasse, E. F.: Renal artery aneurysm: report of 12 cases, two treated by excision of aneurysm and repair of renal artery. *J. Urol.* 77: 697-708, 1957.
8. Shirey, E. K.: Cardiac disease secondary to postnephrectomy arteriovenous fistula; report of case. *Cleveland Clin. Quart.* 26: 188-200, 1959.
9. Grace, J. T.; Staubitz, W.; Lessmann, F., and Egan, R.: Intrarenal arteriovenous fistula. *Arch. Surg.* 81: 718-722, 1960.