

SUPERIOR PULMONARY SULCUS TUMOR OR PANCOAST SYNDROME

Report of Twelve Patients Treated with Surgery and Radiation*

LAURENCE K. GROVES, M.D.

Department of Thoracic Surgery

THE term "superior pulmonary sulcus tumor" and the eponym "Pancoast syndrome" are used almost interchangeably. In 1932, Pancoast¹ coined the former term to describe a malignant neoplasm, at the extreme apex of the pleural cavity, characterized by four features: (1) pain, (2) Horner's syndrome, (3) destruction of bone, and (4) atrophy of hand muscles. This symptom complex quite naturally has come to be called the "Pancoast syndrome."

As to the etiopathogenesis of this tumor, Doctor Pancoast¹ wrote: "One can practically rule out primary lung cancer." Although he believed the superior pulmonary sulcus tumor to be a fatal malignant neoplasm, he did suggest the use of radon-seed implants.

It is now generally agreed that the clinical picture is usually caused by a peripherally located bronchogenic carcinoma; and it seems likely that a histologic re-evaluation of Pancoast's¹ original cases, as well as those in other early reports,² would bear out this finding. Over the years, students of pulmonary disease have found that the tumors and the symptom complex are rather common.

Several years ago we were investigating the palliative value of radon-seed implantation in patients with extensive bronchogenic carcinoma. In January, 1954, I operated upon a man with intractable pain, in the right shoulder girdle, caused by a rather large apical cavitating squamous-cell bronchogenic carcinoma (*Fig. 1*). The neoplastic mass was avulsed from the apical pleura, and the upper and middle lobes were resected. The entire region of pleural involvement was then coagulated with the Bovie-Davis unit, and fifteen 1-mc. radon seeds were implanted. Though this patient was having the usual postoperative incisional discomfort, the day after operation he volunteered the statement that his preoperative shoulder-girdle pain had disappeared. He is still alive and pain-free more than seven years after the operation.

As this unexpected gratifying result was lengthening to several years' duration, it became apparent to us that this technic should be given additional trial, to evaluate both pain relief and longevity. Accordingly, this paper summarizes our experience with the surgical and irradiation treatment of 12 patients who had superior pulmonary sulcus tumors.

*The radioactive materials mentioned in this study were obtained on authorization of the United States Atomic Energy Commission.

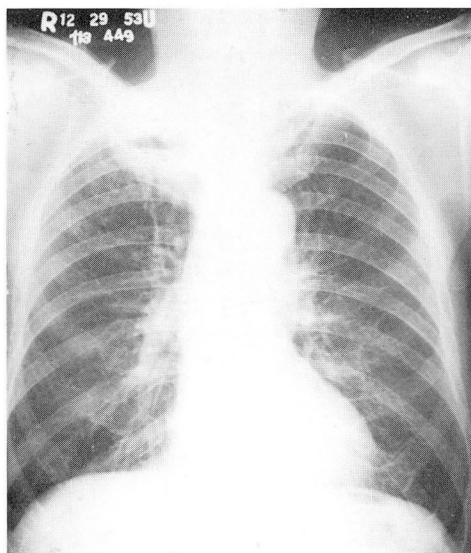


Fig. 1. Preoperative roentgenogram of a 63-year-old man who underwent surgery in January, 1954. The lesion at the right pleural apex proved to be a cavitating squamous-cell carcinoma with gross direct invasion of the apical pleura. To mobilize the lung it was avulsed from the pleura in the region of the first rib circle, and the upper and middle lobes were resected. Fifteen 1-mc. radon seeds were inserted into the region of pleural involvement. The patient has had no subsequent treatment and is still alive and well more than seven years later.

Clinical Features and Diagnosis

The correct diagnosis of superior sulcus tumor is easily made when the pathognomonic features are kept in mind. Because the usual first symptom is one of discomfort in the shoulder-girdle region, the patient most frequently consults first the orthopedist, or occasionally the neurosurgeon. Roentgenographic evidence of the pulmonary component of the tumor may appear as only a slight pleural cap (*Fig. 2*); it may be readily overlooked and a futile course of physio-medical treatment may be instituted.

The meagerness of pulmonary changes as evidenced on roentgenograms may sometimes cause even the physician experienced in pulmonary disease to be reluctant to make the diagnosis of carcinoma. However, the combination of roentgen evidence though meager, and the characteristic constant aggravating pain permit a firm clinical diagnosis even in the absence of Horner's syndrome or frank rib destruction.

Experience with the patients discussed in this paper has made it clear to us that the only sure way to obtain a tissue diagnosis on these patients is via a thoracotomy. No evidence is seen grossly through the bronchoscope, and in only one instance were we able to obtain a positive cytologic preparation. One might expect, from tumors invading the chest wall in this region, a high incidence of positive results of

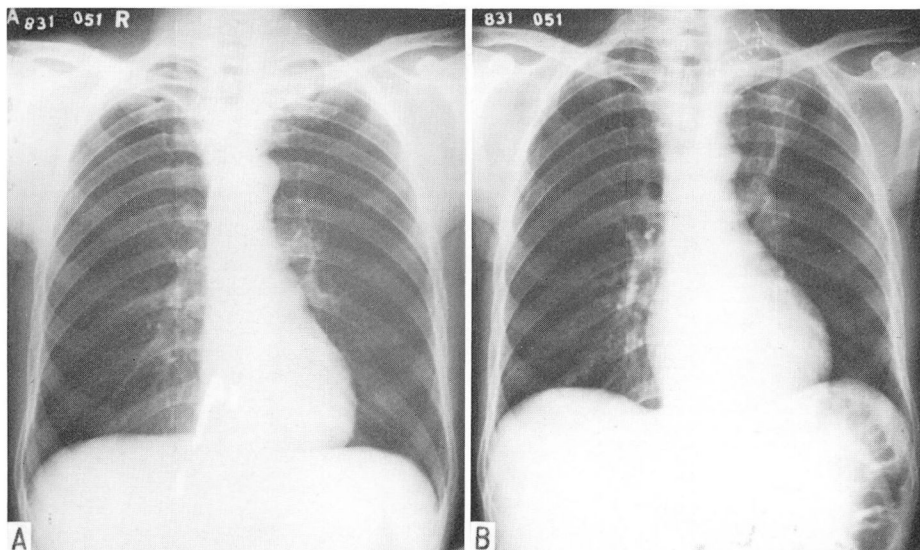


Fig. 2. A, Preoperative roentgenogram of a 52-year-old man who had constant left-shoulder girdle pain for two months, intermittent pain in the inner aspect of the upper left arm, and left Horner's syndrome. This roentgenogram is shown so as to stress the paucity of changes that may be apparent on a roentgen film. B, Shows the position of the radon seeds, and thus identifies the precise location of the tumor.

biopsies of lymph nodes in the scalene region. The incidence may well be high when cases are limited to advanced disease with extensive involvement of the brachial plexus and the base of the neck. However, in five of the patients in this group of 12, scalene biopsy procedures were performed and none gave positive results, probably because a peripheral tumor of this nature has to metastasize via lymphatics all the way into the hilum of the lung, and then up the mediastinal chain to the neck, before it appears as a positive scalene lymph node. This is a much longer route than metastasis from the usual central bronchogenic carcinoma has to travel. Another reason for the low yield of positive results of scalene biopsies may lie in the histologic character of the tumors. The commonest tumor in this series is an adenocarcinoma. Clinical experience with other bronchogenic adenocarcinomas indicates that they are much more likely to metastasize via the blood stream than via the lymphatic channels.

Strictly speaking, the term "Pancoast syndrome" should be reserved for those cases having Pancoast's¹ original tetralogy of findings. Much more commonly the physician will be consulted early in the disease process, before the complete syndrome has developed. Inasmuch as the tumors are extremely peripheral in the lung, pulmonary symptoms are usually absent, and pain is the chief complaint. A Horner's syndrome and frank radiologic evidence of bone destruction have usually been absent when our patients were first examined (*Table 1*). Furthermore, although pain radiating down the arm is common, neurologic deficits in the brachial plexus

GROVES

Table 1.—*Tabular summary of twelve cases of superior pulmonary sulcus tumors*

Case no.	Age, years	Sex	Symptoms	Pain		Horner's syndrome	Bone destruction
				Site	Duration		
1	63	M	Pain, weight loss, hemoptysis	Right shoulder	1 yr.	Absent	Absent
2	46	M	Pain	Right shoulder and arm	5 mo.	Absent	Absent
3	52	M	Pain	Left shoulder and arm	2 mo.	Present	Absent
4	57	M	Pain	Left, back and shoulder and arm	1 yr.	Absent	Minor
5	46	M	Pain	Right, chest and arm	4 mo.	Absent	Absent
6	66	M	Pain	Right shoulder and arm	9 mo.	Absent	Absent
7	45	M	Pain	Right shoulder and arm	9 mo.	Absent	Absent
8	48	M	Pain	Left shoulder	3 mo.	Absent	Absent
9	52	M	Pain	Right shoulder	7 mo.	Absent	Absent
10	49	M	Pain, phlebitis	Right shoulder and arm and hand	2 mo.	Present	Absent
11	44	M	Pain	Right shoulder and arm	4 mo.	Absent	Absent
12	60	M	Pain	Left shoulder and arm	1½ yr.	Absent	Present, severe

distribution have usually not been demonstrable. The pain may also be referred to the distribution of the intercostobrachial nerve in the upper arm.

Two additional features, frequently seen, are worthy of mention. (1) Destruction of the sympathetic chain by the tumor may be manifested not only by a Horner's syndrome, but also or instead by an asymmetry of the perspiration pattern in the upper extremities. The pain experienced by these patients is impressive, not so much because of its severity as its tormenting constancy. Most patients are able to

PANCOAST SYNDROME

Table 1.—concluded

Case no.	Therapy	Pathologic diagnosis	Pain relief		Survival status
			Onset	Duration	
1	Right upper middle lobectomy; 15 radon seeds (1-mc. each)	Squamous-cell carcinoma	Immediate	To date, 7 yr.	Living, 7 yr. postoperatively
2	Wedge resection; 20 radon seeds; x-ray 1 yr. postop.	Adenocarcinoma	Immediate	1 yr.	Died, 27 mo. postoperatively
3	Wedge resection; 20 radon seeds	Adenocarcinoma	Immediate	4 mo.	Died, 4 mo. postoperatively
4	Wedge resection; 20 radon seeds	Adenocarcinoma	Immediate	3 mo.	Died, 7 mo. postoperatively
5	Right upper lobectomy; 25 radon seeds	Adenocarcinoma	Immediate	2 mo.	Died, 2 mo. postoperatively
6	Wedge resection; 25 radon seeds	Adenocarcinoma	Unsatisfactory	—	Died, 7 mo. postoperatively
7	Local resection; 20 radon seeds	Adenocarcinoma	Immediate	To date, 18 mo.	Living, 18 mo. postoperatively
8	Left upper lobectomy; 25 radon seeds	Undifferentiated carcinoma	Immediate	To date, 18 mo.	Living, 18 mo. postoperatively
9	Right upper lobectomy; 25 radon seeds; 3,700 r cobalt ⁶⁰ postop.	Adenocarcinoma	Immediate	5 mo.	Died, 5 mo. postoperatively
10	Right upper lobectomy; 25 radon seeds	Adenocarcinoma	Immediate	4 mo.	Died, 6 mo. postoperatively
11	Cobalt ⁶⁰ x 2 8,000 r tumor dose	No tissue	1 wk.	To date, 4 yr.	Living, 4 yr. postoperatively
12	Cobalt ⁶⁰ 5,100 r tumor dose	No tissue	2 wk.	To date, 2 yr.	Living, 2 yr. postoperatively

obtain satisfactory relief of pain with relatively mild drugs: salicylates or codeine. (2) A most important feature to this pain from a clinical standpoint is the frequency with which the patients apply heat to obtain relief: the greater the heat the more the relief. Burns in the scapular area from hot-water bottle or heating pad are so common in these patients as to be of great diagnostic value.

The lung itself has no nerve fibers to transmit pain; hence the pain associated with these tumors is indicative of neoplastic extension through the parietal pleura

and involvement of the chest wall. From a surgeon's point of view, chest-wall involvement, particularly in the apical region, is a strong criterion of incurability and, hence, though radical resection has been reported,^{3,4} the thoracic surgeon has shown little interest in treating these unfortunate patients.

Clinical Experience

Shaw, Paulson, and Kee⁴ recently reported an encouraging length of survival in a group of patients of this type treated with preoperative radiation followed by radical en-bloc chest-wall and pulmonary resection. Our approach is considerably more conservative. It is too soon to evaluate either series. We can, however, now contradict their statement that: "There are no reports of successful eradication of a superior sulcus tumor following partial resection and subsequent treatment with implantation of radium needles, radon seeds, or deep irradiation therapy."

The cases reviewed here represent a highly select group of 12 "favorable" patients whom we have elected to treat. No statistical significance is attached to them and, inasmuch as all patients with superior pulmonary sulcus tumors of this type have malignant neoplasms that extend beyond their organ of origin, the over-all prognosis is extremely grave. The ultimate survival in any one patient must depend largely upon the character of the malignancy of the individual tumor. The 12 cases summarized here represent only an undetermined small fraction of the total number of patients with this syndrome seen at this institution.

As opposed to this "early" group who were in good general condition when selected for treatment, the majority of such patients have had rapidly progressive and far-advanced disease in which treatment such as described here would obviously have been futile. Even among the patients under discussion, four died of the carcinoma in less than six months, and two others died in less than one year after treatment. An important point is that the response of several of these patients to treatment indicates that the tumor sometimes does not metastasize distantly until late in its course, and may respond to appropriate local treatment with gratifying palliation. In none of the patients upon whom thoracotomy was performed was major rib dissolution by the tumor noted grossly at thoracotomy or detected on preoperative roentgenograms. However, in each patient at operation, frank tumor remained on the chest wall after the lung had been mobilized.

In the series reported here, histologic study revealed eight adenocarcinomas, one squamous-cell carcinoma and one undifferentiated carcinoma, all considered primary tumors of the lung. Histologic material was not available in two additional patients treated only with cobalt 60 teletherapy.

Although the main purpose of this paper is to discuss the treatment of this problem by means of pulmonary resection and the implantation of radon seeds in the chest wall (10 patients), for interest we also report two survivors, currently

for four, and for two years, who were treated only with cobalt 60 teletherapy. Two of the 10 patients also received teletherapy: one patient, who lived twenty-seven months after operation, received supervoltage roentgentherapy one year post-operatively; and another patient, alive and in good condition one year after operation, received cobalt 60 teletherapy during his postoperative convalescence.

Of the 12 patients discussed, one is living and well seven years after receiving treatment. As already mentioned, the two patients treated only with cobalt 60 teletherapy, are living four years and two years after treatment. A fourth patient died twenty-seven months after operation. Two patients are living more than one year after operation. It has been stated that 6 patients died less than one year after treatment.

Of comparable importance to survival in a group of this type is the relief from pain which was obtained. Eleven of the twelve patients received immediate and full relief of pain; included in this group of 11 are the patients treated only with cobalt 60 teletherapy. One of these patients obtained relief within approximately one week after the start of therapy, the other within two weeks. The only unsatisfactory pain relief occurred in a patient whose steady deterioration terminated in death seven months after operation. It was difficult to assess his relief of pain, because of discomfort in the incisional area. Pain relief has lasted seven years in one patient, two years or more in two patients, and more than one year in three patients.

The surgical technics have been comparable in the 10 patients operated upon. Inasmuch as these tumors are out of bounds as far as the chest wall is concerned, it has seemed contraindicated to perform radical pulmonary or hilar resections. The resections have been extremely conservative; the only attempt having been to excise all gross pulmonary neoplasm. The most radical operation performed was a right bilobectomy; the usual procedure was a wedge resection or lobectomy. The pulmonary resection is accomplished after the lung has been mobilized from the chest wall through the region of tumor adherence by scissor or fingertip avulsion. The two raw neoplastic surfaces thus exposed are thoroughly coagulated with the Bovie-Davis unit to minimize neoplastic-cell dissemination on the pleural surfaces.

The region of chest-wall involvement is next implanted with radon seeds (*Fig. 3*). The seeds used are calibrated for 1 mc. at the scheduled time of operation. They are inserted into the region of chest-wall involvement so that each seed is about 1 cm. from its nearest neighbor. This area will usually overlie a portion of the first rib and, frequently, an innominate vein or subclavian artery. It may prove impossible to implant radon seeds securely over the rib; assuredly, seeds occasionally have been injected into the lumen of the major blood vessels and have been carried away. The regions to be irradiated vary in size, but usually are not extensive. It is our current practice to have available 25 radon seeds, which has been a sufficient number when used as described.

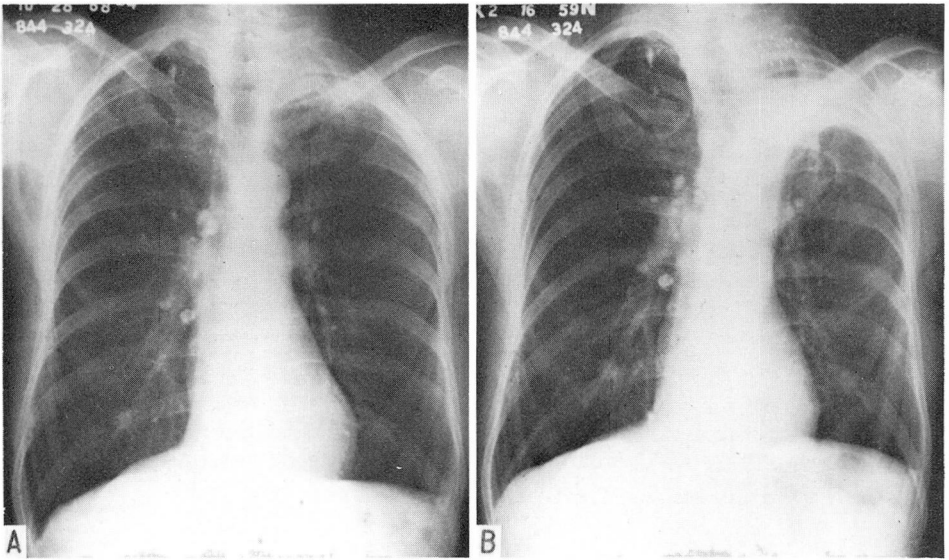


Fig. 3. A, A typical roentgenogram with evidence of a bronchogenic carcinoma (Pancoast syndrome) at the left pleural apex. The patient had constant pain in the left posterior thorax and shoulder girdle for one year. B, Shows the position of the radon seeds three months after a local wedge-type of resection of the tumor and involved tissue. The patient had total relief of pain from the time of operation until the time of this roentgenogram taken three months post-operatively. Soon, thereafter, evidence of generalized neoplastic dissemination developed, and he died six months after the operation.

Comment

As mentioned, the degree of relief from pain attained by this technic has been extremely gratifying. We have become intrigued by the mechanism of the pain and the virtually immediate relief obtained by this method. On the day after operation, at which time the patient has fully recovered from the effects of anesthesia and medication, he will usually remark that his previous pain is gone. If the pain were due to direct neoplastic involvement of intercostal nerve fibers or the brachial plexus, it is inconceivable that superficial coagulation of the parietal pleura, and radon-seed implantation could cause prompt relief. No good explanation for this observation is offered. It is well accepted that bronchogenic carcinoma may cause peculiar distant humoral effects such as osteoarthropathy, neuropathy, and myasthenia. One wonders whether or not with chest-wall involvement there may be a local humoral effect on adjacent nerve tissue. Regardless of the mechanism, the constancy of this prompt relief has encouraged us to continue to treat selected patients in this manner. We have not accepted for this type of operation patients with major rib destruction apparent by roentgenography, believing that this finding indicated extension of tumor beyond the bounds of such local irradiation therapy. It is our current practice in "early" superior pulmonary sulcus tumor suspects to

PANCOAST SYNDROME

advise thoracotomy. One can then affirm the diagnosis, and our experience indicates that at the time of thoracotomy on such a patient, radon seeds should be available for insertion. The symptomatic benefit to the patient has been so prompt that we customarily withhold additional irradiation (currently cobalt 60 teletherapy) until such a time as it may be needed.

If one is prepared to accept a purely clinical diagnosis of superior sulcus bronchogenic carcinoma, external irradiation with cobalt 60 may be equally satisfactory, as exemplified by the two cases mentioned here. However, we have not had other comparable results with this therapy. One of these two patients had obvious destruction of his left second rib which has completely regenerated according to evidence on recent roentgenograms. He was treated through two portals with a tumor dose of 5,100 r. The other patient, who is now symptom-free four years after treatment, has had two courses of treatment for a total tumor dose of 8,100 r. A second course of treatment, instituted because of the appearance of induration in the supraclavicular region, only increased the wooden hardness of this induration, which presumably represents irradiation reaction.

Summary and Conclusion

Clinical experience with a small group of 12 cases of superior pulmonary sulcus carcinoma or Pancoast syndrome is presented. Although the lesion is usually considered surgically incurable, experience indicates that the addition of radon-seed implantation to conservative pulmonary resection, or the intensive treatment of the lesion with cobalt 60 teletherapy, will on occasion give gratifying relief of pain as well as lengthen survival time.

References

1. Pancoast, H. K.: Superior pulmonary sulcus tumor; tumor characterized by pain, Horner's syndrome, destruction of bone, and atrophy of hand muscles. *J.A.M.A.* **99**: 1391-1396, 1932.
2. Herbut, P. A., and Watson, J. S.: Tumor of thoracic inlet producing Pancoast syndrome; report of 17 cases and review of literature. *Arch. Path.* **42**: 88-103, 1946.
3. Chardack, W. M., and MacCallum, J. D.: Pancoast tumor; five-year survival without recurrence or metastases following radical resection and postoperative irradiation. *J. Thoracic Surg.* **31**: 535-542, 1956.
4. Shaw, R. R.; Paulson, D. L., and Kee, J. L., Jr.: Treatment of superior sulcus tumor by irradiation followed by resection. *Ann. Surg.* **154**: 20-40, 1961.