

TRANSURETHRAL REMOVAL OF PAPILLOMA OF THE BLADDER

WILLIAM J. ENGEL, M. D.

Several years ago, a chance experience focused my attention on the possibilities of a new method for intravesical excision of papillary tumors of the bladder. A patient who was to have a transurethral resection for prostatic hypertrophy also had a small papilloma of the bladder. The tumor was approximately one centimeter in diameter and the pedicle was attached just above the right ureteral orifice. It occurred to me that this growth could be removed with the resectoscope at the time of operation on the prostate gland. Hence, when the prostatic resection was completed, the papilloma was engaged in the loop of the instrument. Two or three bites removed the tumor cleanly down to the bladder mucosa, and the base then was coagulated thoroughly. Cystoscopic examination several months later demonstrated that the growth had been removed completely, and there was no evidence of recurrence. These observations stimulated my interest in this method of treatment and, as a consequence, smaller pedunculated tumors of the bladder have been excised intravesically in this fashion in twenty-six instances during the last three years. A technic has been evolved which is applicable to tumors as large as 5 centimeters in diameter or, roughly, the size of a golf ball.

SYMPTOMS

It is pertinent to this discussion to recall the fact that the cardinal symptom of papilloma of the bladder is blood in the urine. This usually appears spontaneously "out of the clear sky" and is seldom attended by burning, frequency, pain, or any other urinary symptoms. It may last only a day or even less and disappear with the same abruptness which marked its appearance. This short duration of hematuria has, unfortunately in many cases, misled both patients and physicians to believe it was of no significance. Recurrent attacks of bleeding are the rule and often each succeeding episode is more severe. It is not uncommon, however, for a year or more to elapse between the first and second appearance of hematuria which emphasizes the importance of investigating the initial warning. Occasionally one sees alarming hemorrhages from these tumors and these may be so severe that a blood transfusion must be given. The amount of bleeding is no index of the size of the tumor as the worst hemorrhage I have seen came from a small papilloma.

Thus hematuria is the only symptom of papilloma of the bladder. One should not wait for the appearance of burning, frequency, tenesmus, etc., for these symptoms in a patient with a bladder tumor usually indicate malignancy and a more unfavorable prognosis for the patient.

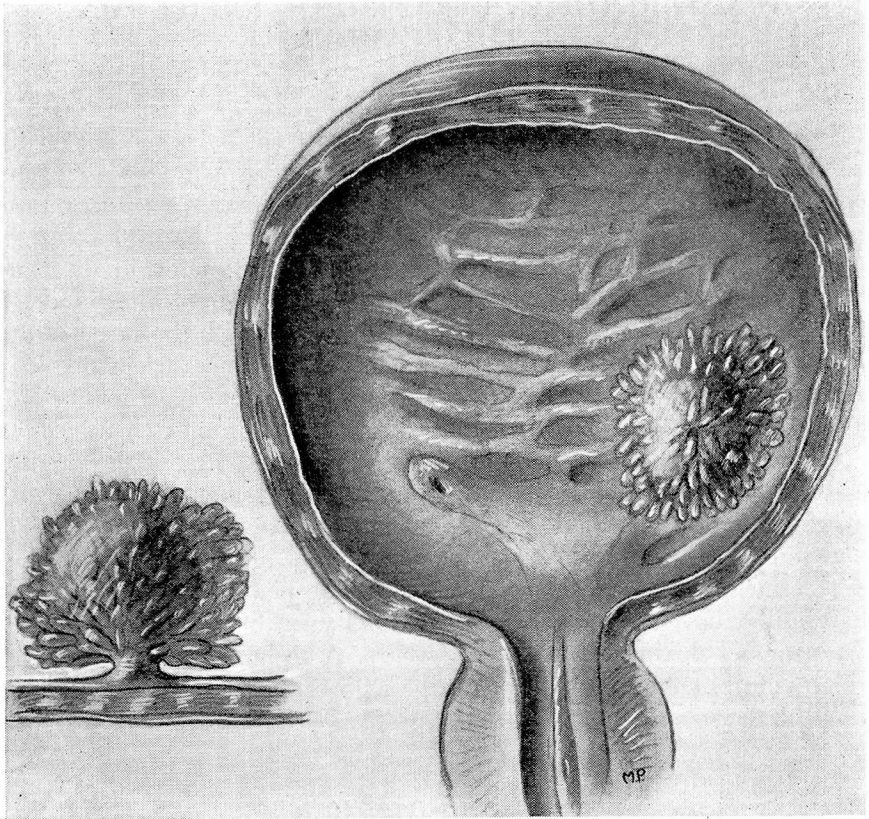


FIGURE 1: Drawing showing pedunculated, soft villous papilloma which is the type suitable for transurethral resection.

CLASSIFICATION OF PAPILLARY TUMORS OF THE BLADDER

Papillary tumors of the bladder constitute about 90 per cent of all bladder tumors. Strictly defined, they include those epithelial tumors which are elevated and project into the lumen of the bladder. They stand in sharp contrast clinically to the infiltrating tumors which invade the bladder wall and grow by surface extension.

Two types of papillary tumors are recognized cystoscopically. The first is the pedunculated, soft, villous papilloma which may be benign or may show histologic evidence of malignancy. (Fig. 1) These papillomata may be single or multiple and may vary greatly in size, which is an important consideration in the selection of the operation.

The second type of papillary growth is the sessile, broad-based, more solid carcinoma. (Fig. 2) In most instances, this is a single tumor, although it may occur in association with other papillomata. It invades

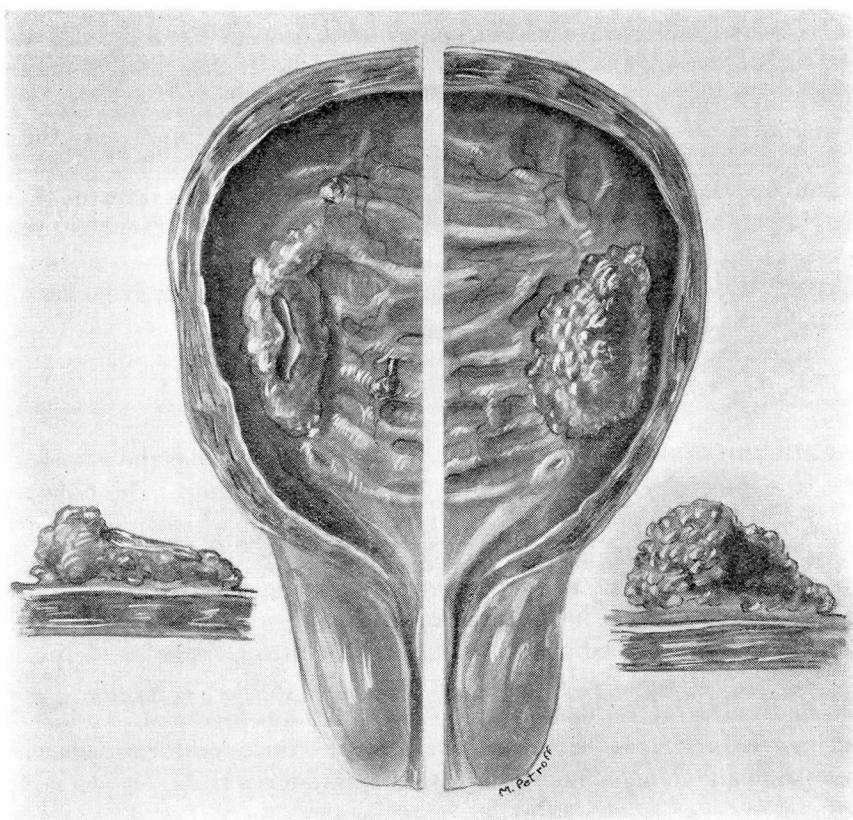


FIGURE 2: Drawing showing sessile, broad-based, more solid carcinoma. This type is not suitable for resection.

the bladder and may exhibit a sloughing, ulcerating surface covered with calcareous material. From the standpoint of treatment, this type of tumor requires more radical measures which are not within the scope of this discussion.

The papilloma must always be regarded as a potentially cancerous growth. Buerger¹ has estimated that from 30 to 35 per cent of all papillomata become malignant. This emphasizes the importance of the complete destruction of these neoplasms when they are first discovered. Even then the problem of recurrence must be dealt with, for, in many instances, a papillomatous growth reappears even though the original tumor has been completely destroyed. In such a case the lesion must be regarded as a new tumor, rather than as a recurrence of the original growth. Obviously the same factors, whatever they may be, which produced the first tumor still exist, and the patient presents a potential problem as long as he lives and retains his bladder. We have the record of one patient from whom a large papilloma of the bladder

was removed in 1913. He returned to the Clinic in 1934, after a free interval of twenty-one years, with what must be classified as a new papillomatous tumor. This was resected intravesically.

THE TREATMENT OF THE PEDUNCULATED PAPILLOMATA

The operation herein described is applicable to the treatment of papillomata with well defined pedicles, regardless of whether the tumor is benign or malignant. Its only limitation is the size of the tumor, although my experience leads me to the opinion that any growth up to 5 cm. in diameter is suitable. If the diameter is greater than 5 cm., the tumor should be removed by suprapubic cystotomy.

Technic of the Intravesical Operation: The technic of the intravesical removal of bladder tumors is similar to that of prostatic resection. The McCarthy resectoscope is employed. This instrument has the advantage of a free loop which cuts with either a to or fro motion. The objective in all cases is to expose the pedicle of the growth which may then be excised flush with the bladder mucosa. In the case of small papillomata, this may frequently be accomplished with a single stroke, whereas the larger tumors have a bushy overhanging margin which must first be removed before the pedicle can be exposed. In such cases the superior and anterior surfaces are cut away until the pedicle is visible. This is then divided piece by piece by pushing the loop forward. To blindly place the loop beyond the tumor and cut toward the operator is hazardous because of the danger of perforating the bladder wall.

Surprisingly little bleeding is encountered ordinarily and there is no difficulty in controlling this with electrocoagulation. Complete coagulation of the surface before the resection is begun has been a great help in some instances when the tumor was fairly large. Once the pedicle is exposed, thorough coagulation usually renders the operation bloodless. It is essential that bleeding be controlled at all times; otherwise the surgeon is confused because of inadequate vision and clots which obscure the boundaries of the tumor.

When the growth has been removed, the base should then be coagulated thoroughly, including an area wide enough to insure destruction of all involved mucosa. Radium has not been implanted in any of the cases in this series and it is not necessary if the tumor has been completely removed and the base adequately treated.

Advantages of the Intravesical Operation: Previously, fulguration was the only intravesical method of treating papillomata of the bladder. This entailed repeated cystoscopic instrumentation and, in many instances, it failed to completely control the growth of the tumor or recurrences. With the resectoscope, it now is possible to remove the entire tumor completely and thoroughly at one operation. This constitutes an obvious advantage.

TRANSURETHRAL REMOVAL OF PAPILLOMA OF THE BLADDER

The intravesical operation has several other advantages: (1) The operative risk is minimized and no deaths have occurred in this series of patients; (2) the period of hospitalization is markedly reduced—the average stay in the hospital for this group of patients was 3.7 days, with a minimum of one day and a maximum of twelve days; (3) tumors for which this operation is suitable can be removed more completely and thoroughly under cystoscopic vision in the intact, distended bladder than with the unaided eye in an opened collapsed bladder; (4) there is less chance of overlooking small secondary growths in the bladder and the occasional recurrence or implant in the prostatic urethra does not escape detection which might easily occur when the bladder is opened and viewed suprapubically; (5) the danger of accidental implantation of tumor cells in the wound has been eliminated by avoiding suprapubic operation.

RESULTS OF TRANSURETHRAL RESECTION

The results of this operation have been most gratifying and have definitely established the fact that it is possible to completely destroy these tumors by this method. Twenty-one of the twenty-six patients have been carefully followed from six months to three years and are known to be well and have no recurrence. Four patients have had small recurrences treated but they are now well and cystoscopic examination shows a normal bladder. One patient has not returned for follow-up examination. In following these patients we do not rely upon symptoms alone but always make a cystoscopic examination at each return visit. This is essential in order to detect early recurrences when they are small and hence easily destroyed.

There have been no operative deaths and no noteworthy complications. Postoperative hemorrhage has occurred in only a single instance and this appeared about twelve days following resection for multiple papillomata. It was relatively mild and only two days of catheter drainage were required to clear it up. One patient's convalescence was delayed by a postoperative pyelitis which responded promptly to appropriate treatment. The only remaining complication was a cystitis which occurred in a woman who had a large cystocele.

FOLLOW-UP MANAGEMENT OF PATIENTS WITH PAPILLARY TUMORS

These tumors have a marked tendency to recur; hence, close observation after operation is necessary. After either intravesical or suprapubic removal, the surgeon has only begun his treatment of the patient. He must give careful explanations regarding the tendency of these tumors to recur asymptotically, and he must impress upon the patient that periodic cystoscopic examination is essential. He is even justified in the threat that cancer will be the result if this warning is ignored. If recur-

rent tumors can be discovered when they are small and still benign, their removal is an easy task, but if they are discovered late when they are large, multiple, or malignant, the outlook may be quite different. It is not sufficient simply to instruct a patient to return at a definite time, but he must be given an adequate explanation for doing so, because the patient who is experiencing no difficulty seldom reports for observation. Experience has proved that greater coöperation can be gained by an intelligent, sympathetic explanation of the problem, even to the point of a short discussion of the pathology of these tumors in lay terms. The patient with a bladder tumor must be educated to understand his problem. Granting that the patient returns for periodic examination, recurrent tumors may be removed by the transurethral method, or minute growths may be destroyed by simple fulguration without anesthesia. Should recurrence be rapid or multiple or should general papillomatosis develop, the lesion must be considered as of the same degree of malignancy as the sessile, broad-based type of papilloma. In these cases more radical measures must be instituted.

SUMMARY

Before the method of treatment can be determined, a clear distinction must be made between the pedunculated, papillomatous tumors and the sessile, broad-based papillary carcinoma.

All primary, pedunculated, papillomatous tumors, single or multiple, which are, roughly, 5 centimeters or less in diameter, can be removed completely at a single operation by intravesical excision with the McCarthy resectoscope. Larger tumors of this type should be excised by suprapubic cystotomy.

Regardless of the method employed, the patient should report at frequent intervals for the first year and annually or semi-annually thereafter for cystoscopic examination in order that possible recurrent growths may be detected and destroyed.

REFERENCES

1. Buerger, L.: The pathological diagnosis of tumors of the bladder with particular reference to papilloma and carcinoma, *Surg. Gynec. & Obst.*, 21:179-198, 1915.
2. Graham, Allen: Tumors of the bladder, *J. Urol.*, 33:565-569, (June) 1935.