

# SURGICAL TREATMENT OF UNILATERAL CORONAL CRANIOSTENOSIS (PLAGIOCEPHALY)

## Report of Three Cases

DONALD F. DOHN, M.D.  
*Department of Neurological Surgery*

CRANIOSTENOSIS or premature closure of cranial sutures ordinarily presents no diagnostic difficulty to the pediatrician or neurosurgeon. For example, the long boatshaped head (scaphocephaly) caused by early closure of the sagittal suture is easily recognized and is by far the most common type. The wide or brachycephalic skull found in bilateral closure of the coronal sutures, and the pointed or tower skull associated with fusion of all the cranial sutures (oxycephaly) likewise present no problem in identification. Roentgenography, of course, has greatly facilitated diagnosis. A simple classification designating the defect according to which suture or sutures are involved is shown in *Table 1*.

**Table 1.**—*Classification of craniostenosis (modified from Freeman and Borkowf<sup>2</sup>)*

---

---

### I. Simple craniostenosis

- A. Sagittal suture (scaphocephaly or boat head)
- B. Coronal suture, bilateral (brachycephaly or short head)
- C. Coronal suture, unilateral (plagiocephaly or asymmetric head)
- D. All or most sutures (oxycephaly or tower head)
- E. Metopic suture (trigonocephaly or triangular head)
- F. Mixed (usually sagittal and one other suture)

### II. Craniostenosis with added anomalies

- A. Crouzon's disease (craniostenosis of any or all sutures with facial anomalies characterized by exophthalmos, small maxilla, prognathism, beaked nose)
  - B. Apert's syndrome (craniostenosis of any type associated with syndactylism)
- 
- 

Some of the rare types of craniostenosis, however, may be difficult to categorize from the clinical and even the roentgen appearance. Unilateral premature stenosis of the coronal suture (plagiocephaly) is one of these unusual varieties, and thus often is not well understood and sometimes is not even recognized. It is the purpose of this paper to report three cases of plagiocephaly treated surgically during the four-year period from 1958 through 1962, and to discuss the clinical and roentgenographic features of the condition. Nathan, Collins, and Collins<sup>1</sup> described three cases of premature unilateral synostosis of the coronal suture; however, they did not discuss the results of surgical treatment. In addition, we wish to state our

position in regard to the recent controversy in the literature concerning the general principles for surgical treatment of craniostenosis.<sup>2-4</sup>

### Pathogenesis

Although various theories have been proposed, the cause of craniostenosis remains unknown.<sup>5</sup> However, it has been established that premature fusion of one or more of the cranial sutures, which ordinarily do not have bony union until the sixth to eighth decade, arrests growth at right angles to the axis of the suture. Since the expanding brain must have room, accelerated bone growth occurs paralleling the long axis of the suture. If this acceleration is not possible because of the multiplicity of suture involvement, intracranial pressure results, often of a severe degree, causing optic atrophy and cerebral dysfunction. It is doubtful that stenosis of a single suture ever leads to restriction of the growth of the brain, which is 80 percent completed by the end of the second year of life. It is important to differentiate microcephaly from craniostenosis. The small head in the patient having microcephaly is caused by failure of the brain to grow, and is not associated with stenosed sutures. In patients having craniostenosis, associated anomalies sometimes are found such as syndactylism, facial deformity, and congenital heart disease, suggesting a common factor in etiopathogenesis.<sup>6</sup> The familial occurrence of scaphocephaly is well documented in the literature, as pointed out by Bell, Clare, and Wentworth.<sup>7</sup> Hereditary examples of plagiocephaly as in our case 1 have not, to our knowledge, previously been reported in the literature.

### Clinical Features of Unilateral Coronal Craniostenosis

As noted in *Table 2*, the number of cases of plagiocephaly represents only a small portion of the total number of cases of craniostenosis seen at the Cleveland Clinic during the last sixteen years (1946 through 1962). The clinical appearance of

**Table 2.**—*Types of craniostenosis (Cleveland Clinic from 1946 through 1962)*

Type	No. of cases
Simple	45
Sagittal suture	24
Coronal bilateral sutures	2
Coronal unilateral suture	3
All or most sutures	6
Metopic suture	4
Mixed sutures	6
Crouzon's disease	4

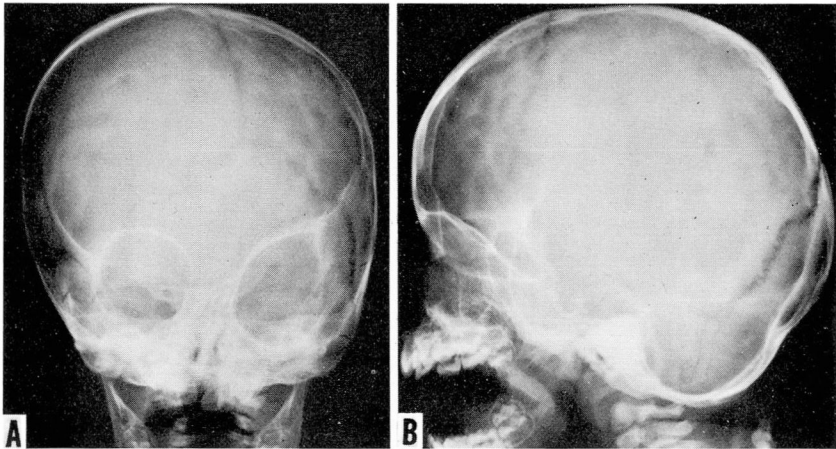
an infant or child with this anomaly is striking. There is extreme asymmetry of the head manifested by flattening of the forehead of the side of the involved suture, with an apparent bulging of the opposite side. The supraorbital ridge on the pathologic side is noticeably underdeveloped and receded, causing the entire orbit to appear malformed and the eye to be exophthalmic. The parents may note that the eye on the involved side fails to close completely during sleep.

### Roentgenographic Features

The most striking roentgenographic finding in these cases is the elliptic shape and enlargement of the orbit on the involved side as seen in the anteroposterior view. This "teardrop" sign may be considered pathognomonic of coronal synostoses. In addition there is ipsilateral elevation of the lesser sphenoid bone, flattening of the parietal region, and slanting of the nasal septum to the pathologic side. The coronal suture is fused, and the anterior cranial fossa is small. The petrous ridge on the ipsilateral side may be depressed.<sup>1</sup>

### Report of Cases

**Case 1.** A 12-month-old boy was examined on September 15, 1958, because of "a lopsided head" and slow mental development. His left supraorbital ridge had not developed and the left side of the forehead was flattened. The palpebral fissure on the left side was much wider than that on the right, and the left eye appeared exophthalmic. Despite the history of poor development, his intellect seemed normal according to gross testing. His mother was noted to have an identical uncorrected deformity except that it was on the right side. Roentgenograms of the skull (*Fig. 1*) were obtained. On September 28, 1958, he underwent linear craniectomy with removal of the stenosed left coronal suture. A small subtemporal decompression was also



**Fig. 1.** Case 1. Preoperative roentgenograms: A, the elliptic left orbit and slanted nasal septum are visible, also the elevation of the ipsilateral sphenoid ridge and the flattening of the parietal region. B, only the uninvolvement of the coronal suture can be seen.

performed. A lining of polyethylene film was sutured to the bony edges to discourage bony fusion. The postoperative course was uneventful, and when the child was last examined nine months following operation, the cosmetic result was judged to be good (Fig. 2) although the operative defect had already been bridged by bone.

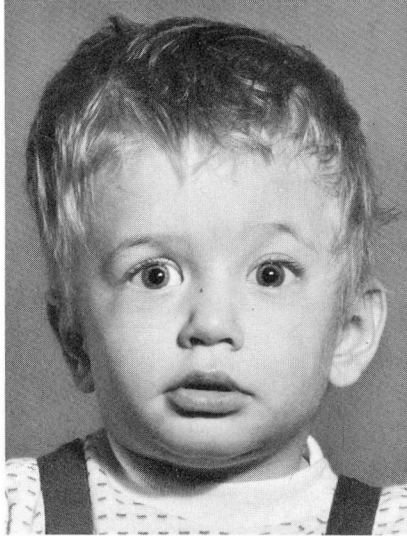

Fig. 2. Case 1. Photograph showing patient's five months' postoperative appearance.

**Case 2.** A six-week-old girl was examined on December 7, 1959, because of asymmetry of the head and unequal opening of the eyes. The appearance was exactly like that of the previous patient except that the defect was on the right side. Roentgenograms showed typical changes of right coronal synostosis (Fig. 3). On December 28, 1959, a linear craniectomy of the stenosed right coronal suture and a small subtemporal decompression were performed. Polyethylene film was used as in case 1. The postoperative course was uneventful. When the child was last ex-

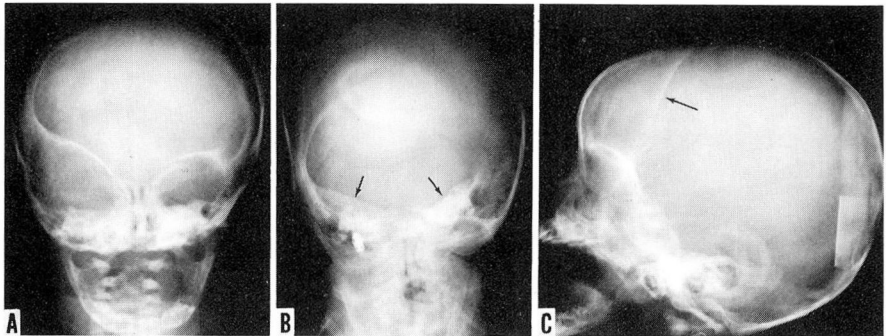
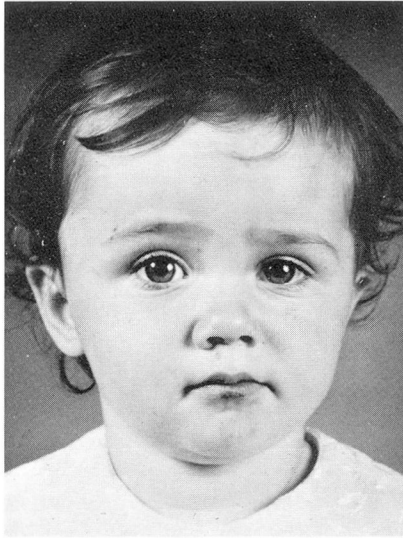


Fig. 3. Case 2. Preoperative roentgenograms: A, elliptic or teardrop right orbit is well demonstrated; there also is a mild but definite tilting of the nasal septum to the same side. B, the right petrous ridge is depressed as compared with the opposite side (arrow). C, only the left coronal suture can be seen (arrow).



amined, 28 months after operation, she was found to have an excellent cosmetic result and to be normal in every way (*Fig. 4*). The bony defects had become bridged with bone.



*Fig. 4.* Case 2. Photograph showing patient's appearance 22 months postoperatively.

**Case 3.** An 8-week-old boy was first examined on November 11, 1959, because of asymmetry of the skull noted by the father a few days after birth. The right side of the forehead seemed prominent to the parents, and they noted that the left eye did not close completely during sleep. Examination revealed the same type of underdevelopment of the left supraorbital ridge and flattening of the left forehead as that in case 1 (*Fig. 5A*). In addition, there was paralysis of external rotation of the left eye. The eye appeared exophthalmic; the roentgenogram is shown in *Figure 6*. On May 17, 1960, six months after initial examination, the patient underwent linear craniectomy of the stenosed left coronal suture. The edges of the craniectomy were lined with polyethylene film. When the child was last examined, 34 months postoperatively, the cosmetic result was good, although there was still palsy of the left external rectus muscle (*Fig. 5B*).

### Differential Diagnosis

Utilization of clinical and roentgenographic features should make the differential diagnosis of asymmetry of the head and face fairly simple.<sup>1, 8-10</sup> Facial hemiatrophy almost always occurs at an age beyond infancy, and does not involve the head. There are atrophic changes in the skin, muscle, and bone. Flattening of the skull from chronic posturing should not be confused with asymmetry from other reasons. It is most commonly found in mentally defective infants or in those who are unable to support their heads without assistance.

Chronic subdural hematoma or slowly progressive brain tumors may cause asymmetry of the head because of the expansion of the skull on the side of the lesion. Here, however, one is usually guided by neurologic symptoms and signs,

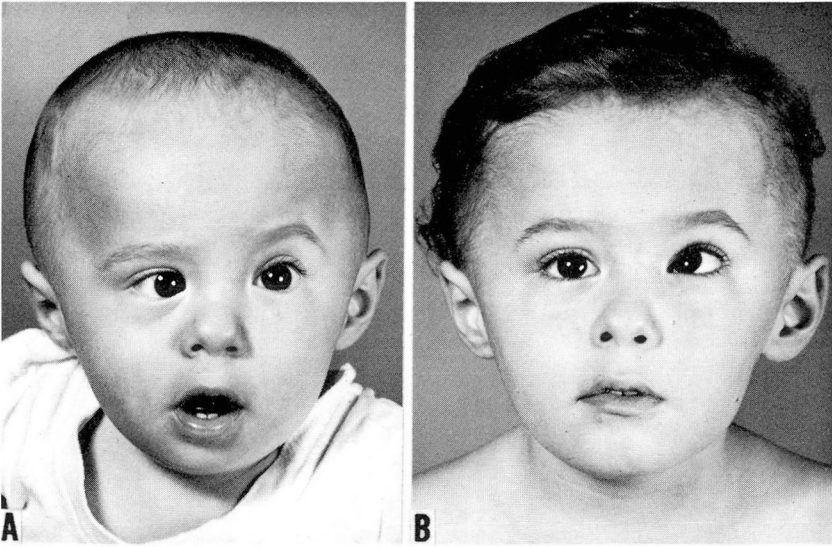


Fig. 5. Case 3. Photographs of the patient: A, preoperative appearance; patient also has unrelated external rectus muscle palsy on the left side. B, 34 months postoperatively; the internal strabismus is to be corrected surgically in a few months.

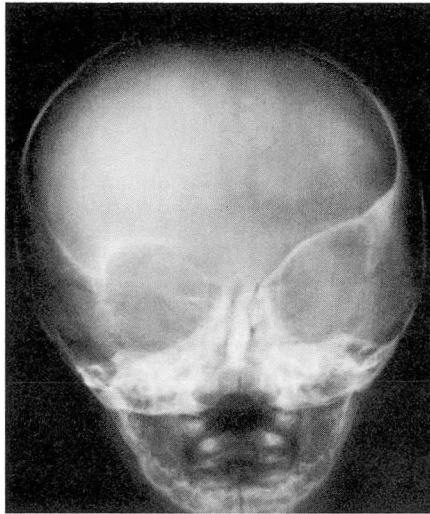


Fig. 6. Case 3. Preoperative roentgenogram showing the teardrop left orbit and notably slanted nasal septum.

and the roentgenographic changes associated with plagiocephaly will not be present. The teardrop orbit and slanted nasal septum of plagiocephaly will be most significant in differentiating plagiocephaly from the brain lesions, since enlargement

of the middle fossa and asymmetry of the petrous and sphenoidal ridges may be present in either group. A palpable ridge over the coronal suture area is often a definitive sign in plagiocephaly.

There are many causes of unilateral exophthalmos, including orbital tumor, cyst or vascular malformation, intracranial hypertension associated with orbital defect, and brain tumor or subdural hematoma; however, these conditions usually are not associated with unilateral frontal flattening. In cerebral hemiatrophy a decided asymmetry of the head may be present. The roentgenograms in this instance show thickening of the skull on the involved side together with elevation of the petrous ridge, and do not show the orbital change and oblique septum as they do in unilateral coronal synostosis.

### Treatment

Recently there have been two provocative papers<sup>2,4</sup> challenging the indications for surgery in craniostenosis, especially for single suture closure, and most particularly for scaphocephaly. These authors have rightly taken to task those surgeons who advise craniectomy in uncomplicated cases of sagittal synostosis in the belief that release of the confined brain will allow its normal growth and thus prevent future complications such as mental retardation. There certainly seems to be no evidence to support such a premise. These same authors,<sup>2,4</sup> however, imply that there also is little need to operate for cosmetic reasons. Their evidence in support of this reasoning is unconvincing.

Our present policy is to operate electively to correct the cosmetic defect whenever it is clinically obvious. The presence of increased intracranial pressure, as for example in oxycephaly, makes surgery mandatory. The operations in the three cases of plagiocephaly reported herein have been somewhat varied but each procedure included a linear craniectomy with removal of the stenosed coronal suture. In patients 1 and 2 a small subtemporal decompression was performed as well. In each patient the pericranium was stripped back from the bone edge and a sheet of polyethylene was sutured in place over the edge to retard regeneration and refusion of the opened suture. A refinement in the technic, which has been advocated by Sayers,<sup>11</sup> is to carry the craniectomy across the supraorbital region and to fracture the supraorbital ridge so as to realign it symmetrically with its opposite member. We have not yet utilized this method, but plan to do so in future cases. Another surgical innovation, which we have used in another case not described herein is the application of Zenker's acetic fixative to the exposed dura mater to reduce its osteoblastic properties.<sup>12</sup>

### Summary

The clinical and radiographic features of unilateral coronal suture stenosis or plagiocephaly are presented. The surgical results in three cases have been good, and seem to justify surgical treatment even if only for cosmetic reasons.

## References

1. Nathan, M. H.; Collins, V. P., and Collins, L. C.: Premature unilateral synostosis of coronal suture. *Am. J. Roentgenol.* **86**: 433-446, 1961.
2. Freeman, J. M., and Borkowf, S.: Craniostenosis; review of literature and report of thirty-four cases. *Pediatrics* **30**: 57-70, 1962.
3. Shillito, J. Jr., and Matson, D. D.: Letter to editor. Sagittal stenosis: indications for operation. *J. Pediat.* **59**: 789-790, 1961.
4. Hemple, D. J.; Harris, L. E.; Svien, H. J., and Holman, C. B.: Craniostenosis involving sagittal suture only: guilt by association? *J. Pediat.* **58**: 342-355, 1961.
5. Ingraham, F. D., and Matson, D. D.: *Neurosurgery of Infancy and Childhood*. Springfield, Illinois: Charles C Thomas, 1954, 456 p.
6. Dodge, H. W., Jr.; Wood, M. W., and Kennedy, R. L.: Craniofacial dysostosis: Crouzon's disease. *Pediatrics* **23**: 98-106, 1959.
7. Bell, H. S.; Clare, F. B., and Wentworth, A. F.: Familial scaphocephaly. *J. Neurosurg.* **18**: 239-241, 1961.
8. Jackson, H.: Asymmetry and growth of skull; Barclay Prize Essay, 1956. *Brit. J. Radiol.* **29**: 521-535, 1956.
9. Archambault, L., and Fromm, N. K.: Progressive facial hemiatrophy; report of 3 cases. *Arch. Neurol. & Psychiat.* **27**: 529-584, 1932.
10. Jacobs, E. M.: Progressive facial hemiatrophy. *Neurology* **5**: 444-446, 1955.
11. Sayers, M. P.: Paper on craniostenosis, presented at Section on Neurological Surgery, Ohio State Medical Association Meeting, Columbus, Ohio, May 1962.
12. Anderson, F. M., and Johnson, F. L.: Craniostenosis. *Surgery* **40**: 961-970, 1956.