

DEFORMITIES OF THE ANTERIOR CHEST WALL IN CHILDREN

LAURENCE K. GROVES, M.D.

Department of Thoracic Surgery

THE pediatrician and the thoracic surgeon are not infrequently consulted by the parents of children with deformities of the anterior chest wall. The commonest of these deformities is the funnel chest or pectus excavatum, and less common is the opposite deformity, pigeon breast, or pectus carinatum. Both of these deformities are closely related, a fact that becomes apparent as one examines a large number of them.

Various combinations of the two abnormalities are encountered in which there are asymmetric deformities of the anterior chest wall, one side being displaced outward and the other side inward, so that in the anteroposterior diameter one hemithorax is distinctly larger than the other. The most obvious skeletal changes involve the sternum and the adjacent costal cartilages; however, there are other aspects to the problem which affect the shape of the entire thoracic cage, and which therefore preclude total surgical correction. Obviously if one half of the thoracic cage has a greater anteroposterior diameter than the other, this asymmetry reflects a different shape of the entire rib cage on each side, and nothing can be done to alter this. Similarly it is extremely common for persons with pectus excavatum deformities to have a greatly decreased anteroposterior thickness of the entire chest structure, and although the surgeon may be able to correct nicely the actual depression, little can be done to alter the basic shape of the chest. To generalize: the greater the deformity to the sternum and cartilages the greater is the associated distortion of the basic contour of the chest, and the surgeon can usually obtain the best cosmetic result from the deformity that initially is not severe. Thus, before arranging for the operation, it is important to point out to the parents what the surgeon can and cannot accomplish.

Considerable disagreement exists in the literature as to the physiologic impairment and possible jeopardy to health and longevity associated with these deformities. It is clear that in extreme forms, much as in the severely kyphoscoliotic individual, cardiorespiratory function can become mechanically so impaired that death occurs at a relatively early age from cor pulmonale; in the extremely severe cases there may also be a slight increase in supraventricular cardiac arrhythmias. Severe cases of this type include only those with extreme flattening of the rib cage, and a distance between the anterior vertebral bodies and the back of the sternum of only 1 or 2 cm. Such degrees of pectus excavatum are rare. One finds generally that pulmonary function and lung capacity are essentially normal. We have studied a number of patients by means of right heart catheterization, and have yet to demonstrate an increase in pressures in the right side of the heart or pulmonary artery in the pediatric age group. The cardiac displacement to the left of the midline, which is

always present in some degree in pectus excavatum, of itself does not seem to be physiologically significant. In addition, one must consider that the extensive surgical mutilation performed to the anterior chest wall in correcting this deformity, although cosmetically pleasing, probably results in considerable functional immobility of this region.

Etiology

The cause of pectus excavatum is not known. The author believes that this is invariably a congenital condition present from birth. In a well-fed infant the deformity may be overlooked, and becomes noticeable to the parents only as the baby fat is lost and the body size increases. Obviously a depression that in the supine adult may hold several ounces of water, would hold only a thimbleful in the newborn infant. The deformity does not seem to be a hereditary trait, although the author has seen it in siblings. Currently in our society it clearly is not rachitic in origin.

One frequently sees a child whose parents are distressed because they were previously told to ". . . leave it alone and he will outgrow it." This never happens, but this advice is not dangerous because, as noted above, the deformity seems to be only rarely of physiologic significance. On the contrary, as a child grows and as his chest size increases, the deformity also grows, although relative to body mass it does not change. Poor posture with a dorsal slouch and stooped shoulders seems to be almost always associated with pectus excavatum deformities (*Fig. 1*). However, the deformity itself cannot be corrected by postural training. This poor posture seems to be a subconscious effort to conceal the deformity, whereas in reality, it directs attention to it.

It has been pointed out that both pectus excavatum and pectus carinatum are associated with excessive length of the costal cartilages.^{1,2} This is invariably present according to my surgical experience. The costal cartilages bridge the distance from the rib end, at the costochondral junction, to the sternum. When these cartilages are just long enough to bridge this gap, the sternum will lie in the same plane as the rib ends. However, when the cartilages are of excessive length, the sternum must then bow either outward or inward to accommodate this length. In some cases it may bow outward on one side and be twisted inward on the other, so that, instead of lying in a transverse plane, the body of the sternum may approximate the anteroposterior axis. Hence it seems reasonable to assume that the same factors are associated with either inward or outward displacement of the sternum and the various combinations as have been mentioned. This is apparently all one and the same anomaly. However the cause for the excessive cartilage length remains obscure.

Indications for Surgical Repair, and Selection of Patients

It is apparent that the chief indications for this operation are cosmetic ones. I

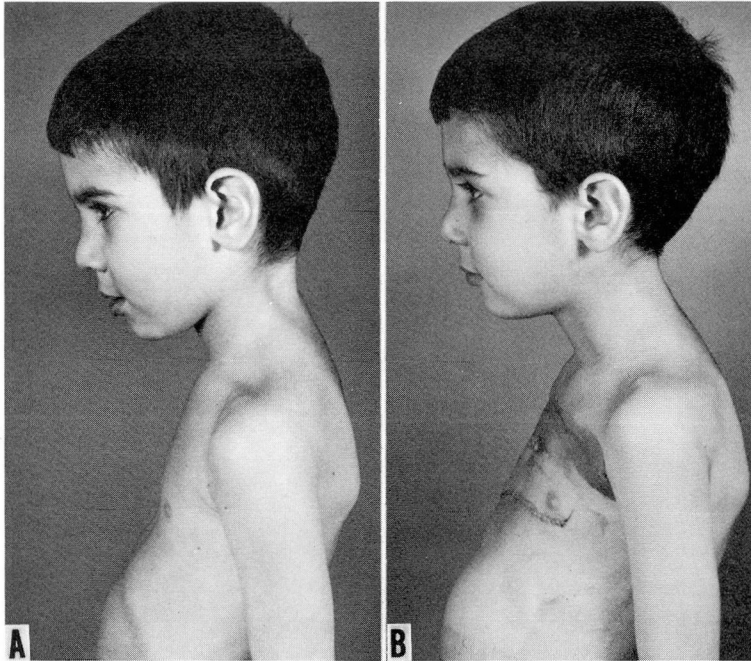


Fig. 1. Preoperative and postoperative profile photographs of a four-year-old boy with pectus excavatum deformity. This lateral view does not show the depth of the funnel deformity, but it emphasizes the typical posture. Unrelenting parental vigilance is necessary to combat this aspect of the problem.

am careful to explain to parents that the surgery will probably have no more effect on the child's health than would a cosmetic nasoplasty, though it may minimize the risk of future cardiopulmonary difficulties. Frequently these children are taken to the physician for such complaints as: "He has colds all winter long"; "He is tired all of the time"; "He doesn't do well in school"; or analogous problems that are virtually a "normal" part of growing up. The parent, to whom the chest deformity is the only obvious physical abnormality of the child, naturally tends to associate it with other disabilities, particularly respiratory symptoms. Children after starting to school usually acquire considerable immunity to respiratory illnesses, and a coincident operation to the chest frequently allows the surgeon to receive unwarranted credit. The cosmetic indications for surgery, however, are important, and I believe that most truly significant deformities warrant surgical correction.

The preschool child has little curiosity about anatomic and physical features, except perhaps for the obvious sex differences. However, to the school-age child who begins to take part in group athletic activities and becomes exposed to locker rooms and community toilet facilities, physical features become important. Facial

features are universally exposed, and although handsomeness of the physiognomy may be a social attribute the opposite condition is accepted and is no true handicap. However, bodily deformities are not acceptable. One's body is assumed to be the same as that of everyone else, and an obvious deformity of the anterior chest wall becomes an object of great curiosity and possibly of derision. Children are thoughtlessly cruel to one another, and the individual who is so unfortunate as to stand out in this fashion can have his life made quite miserable. Such a child may indeed take a great dislike to school, and perform poorly as a student. For obvious reasons he is going to alienate himself from group and athletic activities, and thus isolated may become a social outcast.

Such factors tend to be more important to the boy than to the girl, who is not ordinarily seen bare-chested. It seems justifiable for this reason to leave uncorrected many of the lesser deformities in the girl. In the woman a mild pectus excavatum deformity may be a physical attribute in that it in effect increases what is known in entertainment circles as "cleavage." However, a severe deformity creates a hollow, physically unattractive chest contour (*Fig. 2*).

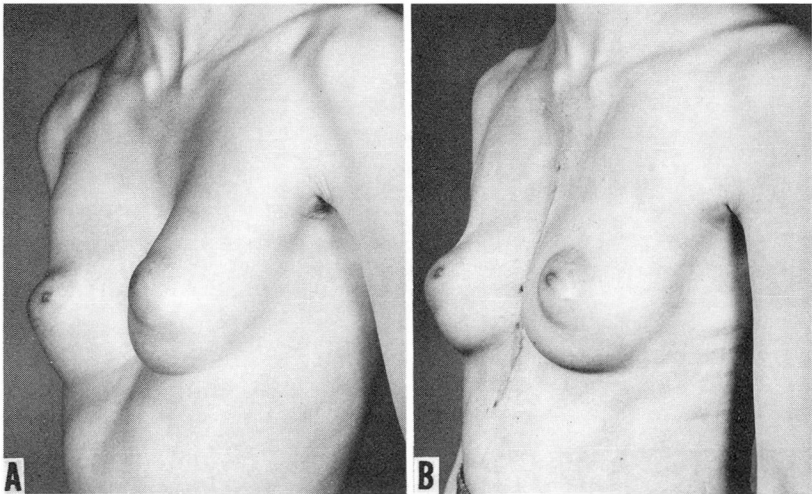


Fig. 2. Preoperative and postoperative photographs depicting appearance of pectus excavatum and the cosmetic improvement achieved in a woman. Currently, we utilize a transverse submammary incision.

Age for Surgery

In the course of our experience in the surgical treatment of more than 70 patients, we have learned a great deal about the management of these patients; probably most important, we think we have learned the ideal age for this surgery. As we have watched this group of patients mature, it has become apparent that the cosmetic result most nearly approximates the ideal if the operation is deferred until

the age of four to six years. The only two true recurrences, which required another operation, occurred in individuals operated on at less than two years of age. The chest structure of the infant is perhaps best described as rubbery, and inasmuch as we do not really understand the forces that cause the deformity, it is not surprising that if recurrence is going to happen it should happen in this young group with elastic chest skeletons.

It was formerly advocated that if the xiphoid were excised in the infant and the "retrosternal ligament" were divided, the funnel chest would be prevented.³ Our trial of this approach was a failure, and we have yet to demonstrate the ligament in question. In our experience a less than complete operation at any age will result in a less than ideal result. A rare infant with obstruction in the major airways may have excessive paradoxical inward motion of the lower anterior chest wall with inspiration. The resulting deformity resembles a funnel chest; however, when such an infant is seen relaxed in his sleep, the deformity is usually not apparent. Under these circumstances traction on the lower end of the sternum (*Fig. 3*) can dramatically improve breathing efficiency and tide the patient over until the respiratory crisis has passed.

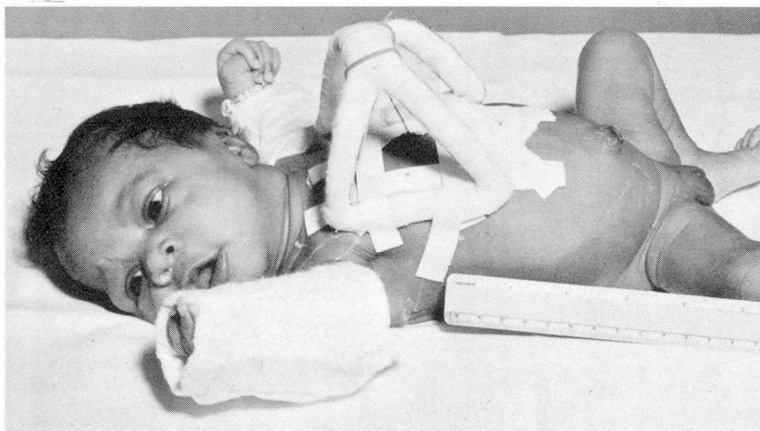


Fig. 3. Photograph of an infant who had been in severe respiratory distress until the lower sternum was supported as described in the text. It was necessary to maintain this traction for approximately one week only.

The immediately preschool child tolerates surgery extremely well. Hospitalization at that time is convenient to all concerned and, most important, the correction achieved is permanently maintained. The child can then enter school without the stigma of his deformity.

There is no reason why the operation cannot be performed at a later date, on into adulthood as we have done many times. However, as the size of the chest increases, the magnitude of the procedure and the time required for it also increase, and we consider from four to six years the preferred age.

Technical Considerations

It has already been stated that we do not think that there is a place for other than a complete operation. There are many variations of such an operation, but insofar as basic principles are concerned most surgeons are in agreement. The sternum is being held in its deviated position by the abnormally long costal cartilages, and these must be resected. Ordinarily the deformity starts inward immediately below the angle of Louis, which is at the level of the second rib. Hence, ordinarily the costal cartilages from and including the third cartilage downward on each side are resected. Occasionally the third cartilage will not be sufficiently deformed to warrant its removal; the surgery must be individualized in each case. It is our practice to remove each cartilage in its entirety from the sternum out to the costochondral junction. Ordinarily the inward or outward deformity, as the case may be, commences laterally at approximately the costochondral junction. One may extend the resection farther laterally (and resect rib) or stop it shorter medially as the situation demands. It is important to preserve the perichondrium so that a new cartilage will regenerate. Usually I bury the tip of a knife blade into the costal cartilage at the sternum through the overlying pectoral muscle. The tip of the knife blade then is drawn laterally along the anterior surface of the cartilage until the costochondral junction is encountered. In this fashion the anterior surface of the cartilage is exposed and the perichondrium is incised. These deformed cartilages may follow an extremely tortuous S-shaped course, and considerable care should be taken to keep the tip of the knife in the cartilage. If the knife slips off and enters the thorax, the consequences might be drastic. Now, using appropriate elevators, the cartilage is mobilized intraperichondrally throughout its circumference (*Fig. 4*). Next it usually is most convenient to divide the cartilage somewhere near its midpoint, and to pick up each end with a Kocher clamp and carry the dissection to the two ends.

After excision of the cartilage, the perichondral tunnel and the overlying pectoral musculature are reconstituted with fine sutures, and a virtually normal costal cartilage can then regenerate. In performing the operation in this manner, we have observed with interest (as each costal cartilage is transected near its midpoint and the ends are allowed to override) the amount of excess length, as indicated by this overriding. In effect each cartilage is a spring that maintains the sternal deformity and, as each cartilage is resected, the sternum approaches a normal position. Occasionally, virtually total correction of the deformity will result merely from removing the cartilages in this fashion; however, in most patients there is sufficient angulation of the sternum to preclude an optimal result. After each cartilage has been removed, and the perichondrium and muscle have been reconstituted, the next cartilage down is dealt with similarly. At the lower end of the sternum, frequently several cartilages that are fused together can be removed through a single incision. We are careful not to overlook the lowermost cartilage on each side: these cartilages are thin, round, elastic, and deeply placed in the rectus muscle, and hence

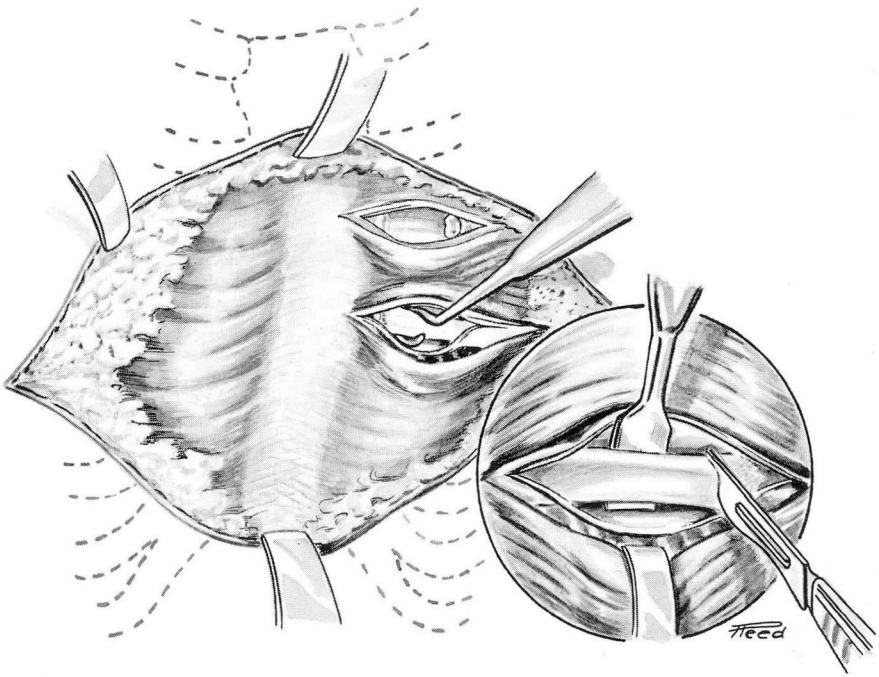


Fig. 4. Diagrammatic sketch of the method of resecting costal cartilages. Each of the tunnels thus created is closed with fine sutures.

are easily missed. I believe that one of our two reoperated on recurrences was caused by overlooking such a costal cartilage at the initial procedure. There was still present a spring to push the sternum back into its depressed position. There may also be floating cartilages at the lower end, the medial ends of which are not attached to the sternum; these cartilages are not important.

To deal with the cartilages as discussed above requires a large exposure of the anterior chest wall. Obtaining this exposure requires a long incision and the development of skin flaps. For a number of years we used a midline vertical incision and developed the skin flaps laterally on each side. More recently, as have others,⁴ we have used a transverse incision. This incision approximates the submammary crease, which is a rather nebulous structure in the pediatric age group, but obviously this incision offers significant cosmetic advantages. It seems to us that both of these incisions on the anterior chest wall have a great propensity to keloid formation, but perhaps the transverse incision also offers advantages in this direction. Ordinarily the transverse incision runs approximately from nipple line to nipple line. If the

cartilages to be resected are rather carefully mapped out before making the incision, the precise location of the incision can be tailored in such a way that equal skin flaps can be developed above and below. It is our practice to develop the skin flaps deep to the subcutaneous fat tissue on the surface of the pectoralis fascia. This plane has been satisfactory; we have had no loss of skin flaps. Others have elevated the pectoralis muscles with the skin flap.⁵

One now is left with the problem of correcting the position of and maintaining correction of the lower sternum, which has been turned loose from its costal attachments. Usually the manubrium of the sternum lies in an essentially normal position and axis, although many of the children have extremely flat chests and the distance between the manubrium and the vertebral column may be distinctly less than normal, even without a funnel deformity at this level. The sternal deformity thus starts at approximately the angle of Louis where there is a posterior angulation leading down to the depths of the depression, which is invariably at the lower pole of the sternum. The degree of angulation is extremely variable, and the rigidity of angulation varies with the age of the child and the resultant degree of ossification. In a few patients the release of the lower sternum has allowed it to spring back into a satisfactory position, so that to have performed an osteotomy, or to have used fixation to maintain the lower sternum, would have been surgically overzealous. The average patient requires maintenance of the correction, or preferably, maintenance of a slightly overcorrected position of the body of the sternum. Costal cartilages, particularly in childhood, regenerate with great rapidity, and probably one month's fixation is adequate. Our current method of fixation is so well tolerated that we have been maintaining it electively for three months.

After resection of the costal cartilages, the xiphoid is excised to give digital access to the anterior mediastinal plane behind the sternum. A finger is inserted behind the sternum, which is manually lifted up into a corrected position, and the cosmetic appearance is assessed. Until approximately a year ago an osteotomy of the anterior sternal table was almost always made at the point of angulation. This transverse osteotomy allowed the sternum to be straightened out by performing in essence a green-stick fracture of the posterior table. Recently, I have found that unless the angulation is extremely severe, firm fixation and slight overcorrection of the lower end of the sternum will elevate the manubrium if it is still attached, and some of the flattening of the upper anterior chest may thus be overcome. The juvenile sternum is sufficiently elastic so that there never has resulted an offensive hump at the angle of Louis. Lateral tilting of the sternum may call for an osteotomy in other locations on the sternum, or even in a longitudinal axis.

The method of immobilizing the lower sternum has improved with experience, and unquestionably the current method is by far the most satisfactory we have used. Originally we maintained the sternal correction with external traction. Several wire sutures were deeply placed into the sternum and were brought out through stab wounds in the overlying skin flaps. These wires were then suspended with rubber

band traction to a frame over the anterior chest wall. In children this frame was fashioned of coat-hanger wire and was taped to the skin. In adults a light plaster jacket was used to support the frame. These technics were cumbersome for the patient or his parents, particularly after discharge from the hospital. Also, it was surprisingly difficult to obtain enough traction in this fashion to maintain the desired slight overcorrection, even when the sternum was completely free from bony support.

In several patients we have placed Kirchner wires transversely across the front of the chest behind the sternum with the ends protruding from the skin. This seemed to be an improvement, but we found it difficult to place the wires precisely through this rather long course. We are currently using the technic described by Adkins and Blades.⁶ The sternal correction is maintained by a flat malleable stainless steel bar that is available in various sizes. The bar looks somewhat like the familiar flat-blade malleable surgical retractor; there are several holes and notches near the ends to allow it to be held in place with catgut sutures. It is sufficiently malleable so that it can be bent by hand or with pliers. A size is selected that is sufficiently long, so that when it is placed across the front of the chest each end is well supported on the rib cage lateral to the costochondral junction.

A tunnel is then developed with scissor dissection immediately behind the lowermost end of the sternum, taking care to stay close to the sternum to avoid injury to the internal mammary vessels. Practically, each end of this tunnel should start at the deep aspect of one of the sites of cartilage removal, where a plane can readily be developed across the back of the sternum. The bar is inserted through this tunnel and then is contoured to fit the anterior chest wall, and at the same time is bowed anteriorly sufficiently in the midline to maintain the sternum in a slightly overcorrected position (*Fig. 5*). The ends of the bar are sutured to the chest wall musculature with several catgut sutures. Except where it passes behind the sternum, it is subcutaneous in location. We have never seen one shift in position significantly. It is the author's practice to place one end of the bar in such a position that it lies immediately beneath one pole of the skin incision. Thus it can be removed subsequently by reincising one tip of the incision while the patient is under either local or brief general anesthesia.

Surgery for the pigeon-breast deformities is virtually identical to that for funnel chest. In a rather limited experience it has been found that once the cartilages have been resected, the sternum will fall back into a satisfactory position without any fixation device (*Fig. 6*). All that is necessary is a firm wound closure, and perhaps slight pressure from the dressings. In every patient (both types of deformity) a Penrose drain has been left in place for approximately 24 hours through a small stab wound in the lower skin flap, thus minimizing the possibility of a hematoma's causing the skin flaps to float.

There has been no surgical mortality in this group of patients. Pneumothorax is such a frequent occurrence from entering a pleural space in the course of dissecting

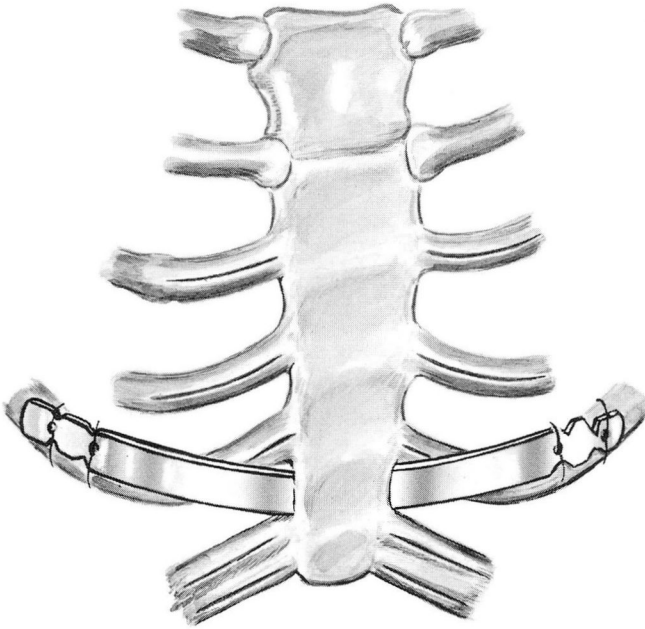

Fig. 5. Artist's impression of the use of the malleable stainless steel bar to support the sternum in the corrected position.

out the costal cartilages that it is not considered a true complication. A chest roentgenogram is routinely obtained shortly after the completion of the operation, and a severe degree of pneumothorax is immediately treated by thoracentesis. Infection is to be dreaded after an operation that opens up so many tissue planes, and fortunately major sepsis has not been a problem. In one instance, persistent wound drainage necessitated the removal of the steel bar after one month; however, the repair was solid and the ultimate cosmetic result has been excellent. Drainage ceased immediately upon removal of the bar. The only major complication in this series of patients occurred early in our experience with the use of the stainless steel bar. The patient was a teenage boy, and the longest bar available obtained only a precarious support on the chest wall lateral to the cartilage resections. Subsequently the bar slipped off the ribs at one end, and the sternum exerted sufficient posterior force so that the bar was pushed down through the chest wall tissues and fractured the internal mammary vessels, control of which fracture twice necessitated emergency thoracotomy. We have been careful since this time to use a bar amply long to be molded to the anterolateral portion of the chest, hence, to be well supported.

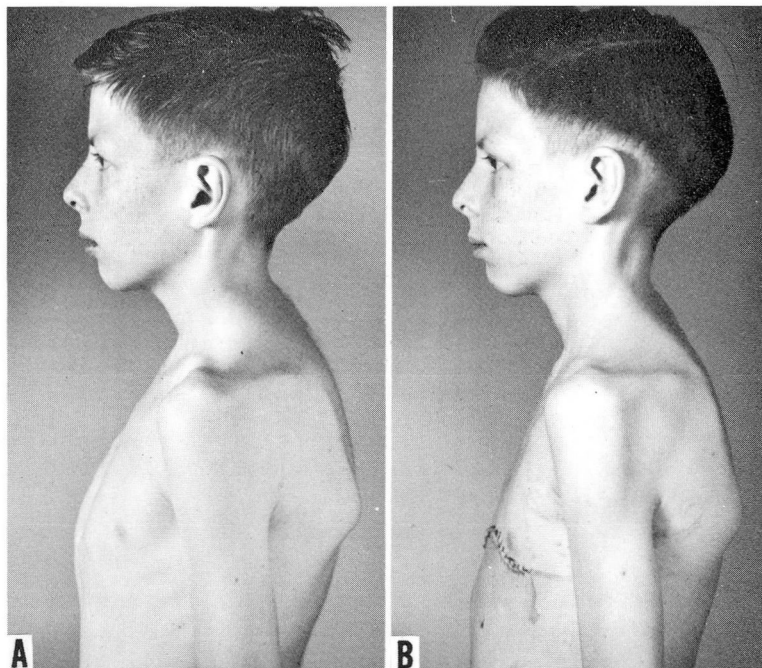


Fig. 6. Preoperative and postoperative photographs of a 13-year-old boy who had pectus carinatum deformity. A decrease in anteroposterior chest diameter was accomplished by surgical correction of the pectus carinatum. The child was greatly handicapped by chronic bronchial asthma. Subjectively, and according to his family, there has been a dramatic improvement in his respiratory function. We have been unable to document this improvement in serial determinations of timed vital capacity.

Conclusion

The author's philosophic concept and surgical technic in the correction of the anterior chest wall deformities in children are discussed. It is stressed that in most instances the operations are plastic surgery for cosmetic improvement. It is also pointed out that the cosmetic indications in children usually are sufficient to justify surgical correction, particularly since the surgical risk is low and the end results are altogether satisfactory.

References

1. Sweet, R. H.: Pectus excavatum; report of 2 cases successfully operated upon. *Ann. Surg.* 119: 922-934, 1944.
2. Sanger, P. W.; Robicsek, F., and Taylor, F. H.: Surgical management of anterior chest deformities: new technique and report of 153 operations without death. *Surgery* 48: 510-521, 1960.

3. Brown, A. L.: Pectus excavatum (funnel chest) anatomic basis; surgical treatment of incipient stage in infancy; and correction of deformity in fully developed stage. *J. Thoracic Surg.* **9**: 164-184, 1939.
4. Welch, K. J.: Satisfactory surgical correction of pectus excavatum deformity in childhood; limited opportunity. *J. Thoracic Surg.* **36**: 697-713; discussion, 724-728, 1958.
5. Ravitch, M. M.: Congenital deformities of chest wall, p. 227-247, *in* Benson, C. D., and others, editors: *Pediatric Surgery*, vol. 1, Chicago: Year Book Medical Publishers, Inc., 1962, 653 p.
6. Adkins, P. C., and Blades, B.: Stainless steel strut for correction of pectus excavatum. *Surg. Gynec. & Obst.* **113**: 111-113, 1961.