

## CONGENITAL DIAPHRAGMATIC HERNIA IN THE CHILD BEYOND INFANCY

ROBERT E. HERMANN, M.D., and DAVID H. BARBER, M.D.\*

*Department of General Surgery*

CONGENITAL hernia of the diaphragm is infrequently seen in the child beyond the age of two years, because of the frequency with which it becomes symptomatic and is treated in the neonatal period and infancy. In the newborn child and the infant, these hernial defects are life-threatening during the first hours to days of life, from collapse of the lung on the side of the defect, and compression of the contralateral lung secondary to mediastinal shift. Distention of the herniated gastrointestinal organs further exaggerates the existing respiratory insufficiency. Symptoms of severe respiratory distress, cyanosis, and dyspnea are most prominent, with circulatory disorders and gastrointestinal symptoms present to a lesser degree.

Because of the high mortality associated with congenital diaphragmatic hernia in the newborn when the defect is not promptly repaired (75 percent in the early study of Hedblom<sup>1</sup>), most of the emphasis in teaching has been placed on the symptoms of acute respiratory insufficiency seen in the newborn period. Early surgical repair of the defect is essential. A few children with small defects, however, do survive the first months and years of life without noticeable difficulty, only to have symptoms develop in later years.

In these children beyond the age of infancy, problems referable to the gastrointestinal tract usually overshadow those of the respiratory tract.<sup>2</sup> These gastrointestinal difficulties include those of obstruction, intermittent incarceration, or, occasionally, strangulation of viscera with perforation. Such a problem is illustrated in a recent case of a congenital diaphragmatic hernia in a child of six and one-half years of age.

### Report of an Illustrative Case

A six and one-half year old boy was admitted to Babies and Childrens Hospital of the University Hospitals of Cleveland† on an emergency basis late at night on November 7, 1961, because of nausea, vomiting, and abdominal pain of eight hours' duration. The child had become ill at school, and had been vomiting small amounts of clear fluid without relief of the abdominal distress. His pediatrician examined him, and referred him to the hospital for further evaluation. The parents stated that in the last two weeks the child had complained of vague abdominal distress, and twice had vomited clear fluid without evidence of blood. The child otherwise had been well.

His previous medical history was unremarkable. The child was the second child of four children, the product of a normal pregnancy and delivery. Growth and development were normal. He had undergone tonsillectomy and adenoidectomy at the age of two years. One sibling, aged seven years, was said to have had "pyloric stenosis" at one month of age, which

\*Fellow in the Department of General Surgery.

†When the senior author was on the staff of the University Hospitals of Cleveland, Cleveland, Ohio.

had been treated by medical management. There was no known trauma before the onset of the present illness. Several chest roentgenograms, made three years before admission to the hospital, were stated to have revealed "cloudiness around the heart."

On physical examination the child was pale and appeared to be in moderate distress. He was lethargic, breathing rapidly with mild respiratory distress, but was not cyanotic. His temperature was 39.5 C., his pulse rate was 108, and blood pressure was 110/85 mm. of Hg. The trachea was found to be deviated to the right. There was dullness to percussion over the left lower part of the chest with diminished breath sounds in this area; breath sounds on the right side were normal. The apical pulse was in the left midclavicular line; no thrill or murmur was detectable. The abdomen was soft; the liver could be percussed at the right costal margin. There was moderate tenderness to palpation in the left upper quadrant of the abdomen; bowel sounds were normal. The results of rectal examination were normal, as was the remainder of the physical examination at this time. Laboratory studies included a blood hemoglobin content of 14.6 gm. per 100 ml., with a hematocrit reading of 42 percent, a white blood count of 16,600 per cubic millimeter, a differential leukocyte count with increased immaturity of cells; and a normal urinalysis. Serum electrolyte concentrations were: sodium, 141 mEq. per liter; potassium, 4.2 mEq. per liter; chloride, 101 mEq. per liter; plasma carbon dioxide content was 23.9 mEq. per liter; and blood pH, 7.38.

A roentgenogram of the chest showed the mediastinum notably shifted to the right, and the left lung atelectatic, compressed into the left upper hemithorax with an air-fluid level below (Fig. 1). A nasogastric tube was inserted, and approximately 800 ml. of clear liquid was aspirated

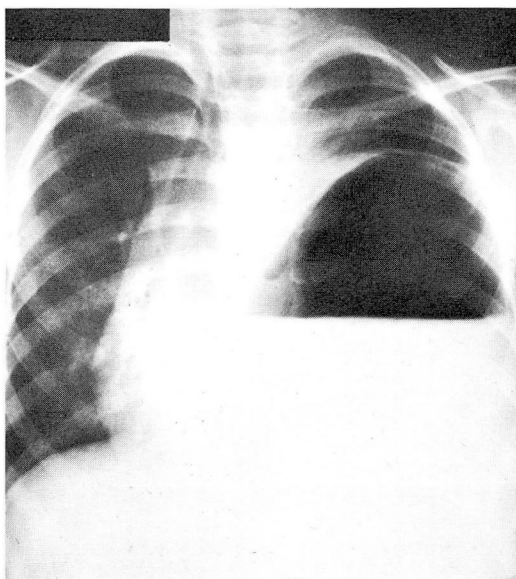


Fig. 1. Initial chest roentgenogram showing evidence of a herniated, distended viscus in the left lower part of the chest, with a large amount of air and fluid.

along with an unknown quantity of air. Another roentgenogram of the chest at that time showed evidence of less air and fluid than before, and partial reexpansion of the left lung (Fig. 2). The mediastinum had returned to a midline position. A presumptive diagnosis was made of left posterolateral diaphragmatic hernia of the foramen of Bochdalek, with herniation and incarceration.

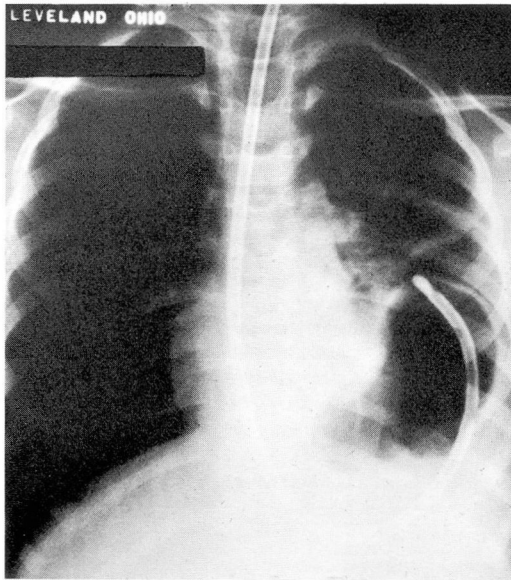


Fig. 2. Passage of the nasogastric tube into the viscus demonstrates on the roentgenogram that it is stomach. The distention is decreased after suction.

tion of the stomach. The nasogastric tube was placed on constant suction; antibiotics were administered; and parenteral rehydration was instituted. A surgical consultation was obtained, and it was believed that a short period of gastric decompression, fluid replacement, and antibiotic therapy preoperatively was indicated.

There was an initial improvement with treatment, but several hours later the patient's condition suddenly deteriorated. There was return of the mediastinal shift to the right, and the child became severely dyspneic with a respiratory rate of 90. He appeared pale, cyanotic, and complained of pain in the left lower posterior region of the chest. Another roentgenogram showed evidence of a mediastinal shift to the right, with a tension pneumothorax on the left and collapse of the left lung (Fig. 3). An anterior thoracotomy tube was immediately placed into the pleural cavity, and several hundred milliliters of dark-brown fluid and air was obtained, with relief of the patient's respiratory distress and return of the mediastinum to the midline (Fig. 4). The diagnosis of perforation of the stomach was made, and immediate surgical intervention was advised.

Early on November 8, 1961, under endotracheal anesthesia, a left subcostal incision was made and the upper abdomen was inspected. A left posterolateral diaphragmatic hernia of the foramen of Bochdalek was found, approximately 3 cm. in diameter. There was herniation and incarceration of the entire stomach, the spleen, and the splenic flexure of the left colon into the chest. A moderate amount of cloudy fluid was present in the left upper part of the abdomen. The hernial defect was opened to release the incarcerated viscera, and these were delivered into the abdomen. A 1 by 2 cm. perforation in the upper greater curvature of the stomach could then be seen in a region of ischemic change (Fig. 5). The spleen appeared thickened and engorged, but thrombosis of the splenic vein was not present. The thorax was thoroughly irrigated with saline solution, and a second thoracotomy tube was inserted into the left lower pleural cavity for postoperative drainage. The hernial defect was repaired by simple closure with interrupted

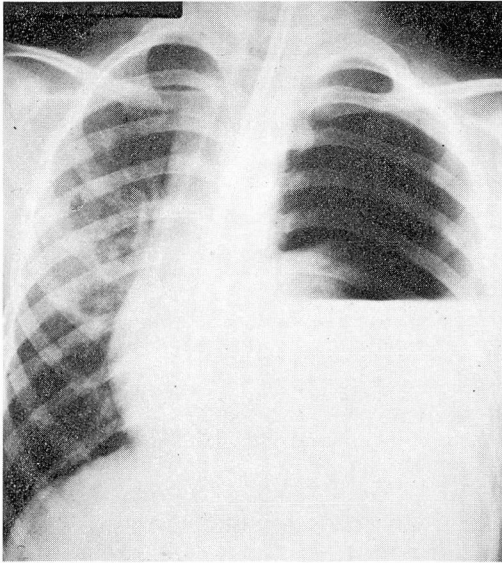


Fig. 3. The most striking change on the roentgenogram is evidence of a tension pneumothorax on the left, with a large air-fluid level. The collapsed lung is shown in the hilar region above the fluid level.

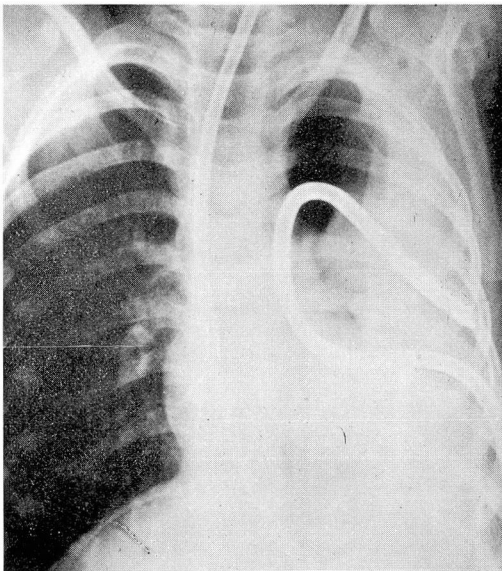


Fig. 4. Roentgenogram showing that an anterior thoracotomy tube has partially reexpanded the left lung.



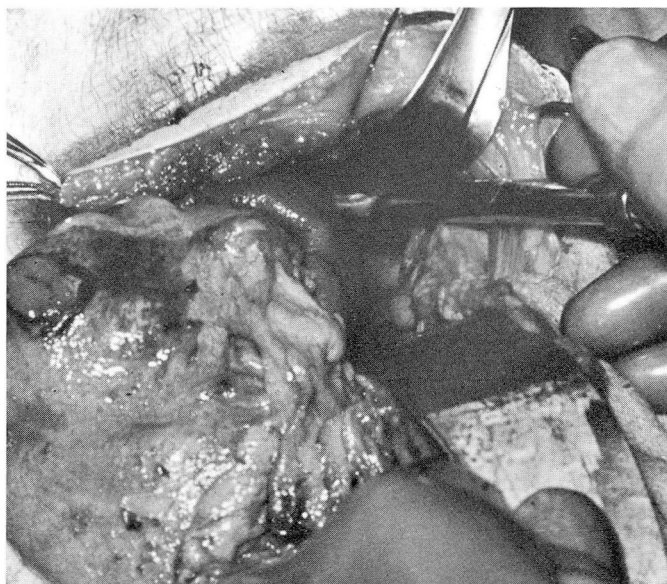

Fig. 5. Operative photograph showing (in upper left) the perforation in the stomach, and (in upper central) the hernial defect.

three-zero silk sutures. A wedge gastric resection that included the region of ischemia and perforation of the greater curvature of the stomach was performed, and the spleen was removed because of congestion and the hazard of splenic vein thrombosis. A gastrostomy tube was placed and the abdominal wound was closed.

The patient's postoperative course was uneventful. Examination of the chest in the immediately postoperative period showed full reexpansion of the left lung. A subsequent roentgenogram showed no evidence of atelectasis or residual pleural effusion, and the outline of the left diaphragm was smooth (Fig. 6). The patient was discharged from the hospital on the tenth postoperative day. Results of follow-up examinations have been normal, and one year later the boy is fully active and has no complaints of ill health.

### Discussion

Congenital diaphragmatic hernias may occur in any of three locations: the posterolateral regions along the pleuroperitoneal canal (the foramen of Bochdalek), the region of the esophageal hiatus, or behind the sternum (the foramen of Morgagni). Hernias of the foramen of Bochdalek account for about four fifths of all congenital hernias of the diaphragm.<sup>3</sup> Those on the left side are about five times more common than those on the right side, and are more frequently symptomatic since the liver often covers the defect on the right side.

The majority of hernias of the foramen of Bochdalek do not have a sac, thus allowing the abdominal viscera to pass freely into the pleural cavity of the side involved. A large defect permits such a passage without constriction of the viscera;

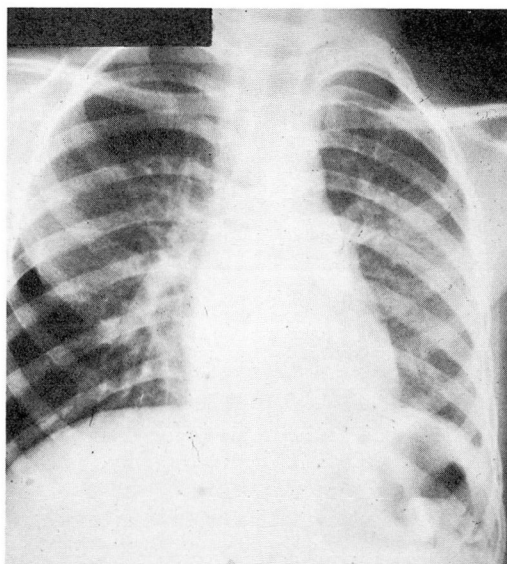


Fig. 6. Chest roentgenogram taken on the ninth postoperative day, before the patient was discharged from the hospital.

the lung on the side of the defect is unexpanded, and respiratory symptoms are pronounced, becoming worse as swallowed air distends the herniated viscera. These symptoms predominate in the newborn, and overshadow any symptoms of intestinal tract obstruction.

If the diaphragmatic hernia is small, or if it has a sac, as do almost all hernias of the esophageal hiatus and about half of the defects of the retrosternal area, respiratory symptoms are lessened or absent. The lungs are normally expanded, and massive herniation of the gastrointestinal tract does not occur. In these children, symptoms may not be detected in the first few years of life, and the hernia remains masked.

In the child older than two years of age, the most prominent symptoms associated with diaphragmatic hernias are those referable to the gastrointestinal tract. Symptoms of intermittent abdominal pain and distention, mucosal bleeding, and vomiting all may be present. Surgical repair of the defect should be undertaken whenever the diagnosis can be made, as soon as any coexisting fluid deficits are repaired, for with strangulation and perforation the mortality rate may rise to as high as 40 percent.<sup>4</sup>

The method of approach to the repair of diaphragmatic hernias, whether transabdominal or transthoracic has been much discussed.<sup>5</sup> In the newborn with a large defect, where most of the abdominal contents are misplaced into the chest, the

abdomen frequently has a limited capacity to accept these contents when the hernia is repaired. The "right of domain" of the viscera in the abdomen has not been established. In these instances an approach through the abdomen has certain advantages: reduction of the viscera is easily performed, and inspection for an accompanying obstructing malrotation (which occurs in one patient of six<sup>3</sup>) may be accomplished. Repair of the defect is technically as satisfactory as through the chest. Closure of the abdominal wound, if the abdomen is inadequately developed, may be staged, closing only the skin at the primary procedure, leaving a fascial defect to be closed at a later procedure. This allows replacement of intestinal contents without so distending the abdomen that diaphragmatic respiratory excursion is limited and undue tension is placed on the repaired diaphragm.

In the child beyond infancy in whom these problems do not exist, the trans-thoracic repair may be more suitable than transabdominal repair for closure of the defect. Yet, when there are problems of intestinal obstruction or incarceration, and certainly when strangulation with perforation has occurred, the repair through the abdomen is most advantageous. Reduction of the hernial contents and inspection of the viscera for areas of necrosis or ischemia, and the division of other adhesions or bands may be performed. When ischemia or necrosis is seen, or when a perforation exists, resection or closure may be performed under better vision and control from the abdominal than from the thoracic side. Also, in these children, closure of the diaphragmatic defect is rarely a problem from below. The pleural space can be thoroughly irrigated during the procedure, and is drained by means of a chest catheter with adequate control of the intrapleural soiling.

### Summary

Little has been written about the symptoms of congenital hernias of the diaphragm in the child whose hernia has escaped detection during infancy. It is much less common to have symptoms from diaphragmatic hernias develop in late childhood. The predominance of gastrointestinal symptoms in such a child in distinction to respiratory symptoms in the newborn or infant has not been previously stressed. A case is presented which illustrates the predominant gastrointestinal symptoms and complications that can occur in children beyond the first years of life. Operative management is discussed, and the value of transabdominal repair for children with associated complications is stressed.

### References

1. Hedblom, C. A.: Diaphragmatic hernia; study of 378 cases in which operation was performed. *J.A.M.A.* 85: 947-953, 1925.
2. Kiesewetter, W. B.; Gutierrez, I. Z., and Sieber, W. K.: Diaphragmatic hernia in infants under one year of age. *Arch. Surg.* 83: 561-572, 1961.

3. Gross, R. E.: Chap. 33, Congenital hernia of diaphragm, p. 428-444, *in* The Surgery of Infancy and Childhood; Its Principles and Techniques. Philadelphia: W. B. Saunders Co., 1953, 1000 p.
4. Skinner, E. F.; Carr, D.; Duncan, J. T., and Hall, J. R.: Strangulated diaphragmatic hernia. *J. Thoracic Surg.* **36**: 102-111, 1958.
5. Baffes, T. G.: Diaphragmatic hernia, p. 251-265, *in* Benson, C. D., and others: *Pediatric Surgery*, vol. 1. Chicago: Year Book Medical Publishers, Inc., 1962, 653 p.