

SURGICAL TREATMENT OF CHRONIC ULCERATIVE COLITIS IN CHILDREN

Four Illustrative Case Reports

WILLIAM M. MICHENER, M.D., M.S.(Pediat.),
Department of Pediatrics

and

RUPERT B. TURNBULL, JR., M.D.
Department of General Surgery

TREATMENT of the child with chronic ulcerative colitis continues to be a challenge to the pediatrician, the gastroenterologist, and the surgeon. The clinical course of this disease is variable and at times unpredictable despite adequate medical therapy. Increased awareness that this entity occurs in children has led to early diagnosis and consequently better medical management of the illness. The availability of steroid hormones for systemic and topical administration has greatly improved the effectiveness of treatment of the child severely ill with chronic ulcerative colitis.

The progress made in the medical management of this disease has been coupled also with significant improvement in the surgical treatment. Ileostomy and subtotal colectomy have been lifesaving in several of our patients, and our overall experience with these procedures in the patients with ulcerative colitis has been gratifying and encouraging. With the improvement in surgical technic, and the obvious improvement of the child after ileostomy and subtotal colectomy, the controversy as to whether it is the medical or the surgical therapy that prolongs these patients' lives assumes importance.

Indications for surgical intervention during the course of ulcerative colitis in a child are usually definite, only occasionally controversial. Definite indications include: imminent perforation (toxic megacolon), carcinoma of the colon, and repeated massive hemorrhages. A controversial indication is the history of recurrent disabling disease for five years in the adolescent child. Differences of opinion are reflected in the range of percentages of patients with colitis who have been operated on in various institutions. However, the percentages of children operated on has been practically the same in most large series reported for similar periods of follow-up; namely, about 20 percent.¹⁻³ In the last 10 years, from 1952 to 1962 at the Cleveland Clinic, of 74 children with ulcerative colitis, 19 (23 percent) underwent ileostomy and subtotal or total colectomy. A slightly higher operative incidence is reported by Korelitz and Gribetz.⁴ Comparison of these various operative percentages would indicate that the controversies regarding surgical indications are mainly academic, and that when dealing with the sick child in practice, most physicians would agree on the indications for *definitive* surgery.

Perhaps the situation most often underestimated as to seriousness is in the child in whom, during rapidly progressing disease, toxic dilatation of the colon develops. Impending perforation through the dilated thin wall must be considered a surgical emergency if there has been no prompt response to medical therapy.

Retardation of development is common in the child who has chronic ulcerative colitis. Pediatricians have long been aware that chronic disease has a more deleterious effect on the growing child than on the adult. Usually the child who continues to have recurrent or chronic diarrhea (or bloody diarrhea) will attain normal height, but be severely underweight. At this institution, from 10 to 15 percent of children have loss in weight as the chief reason for seeking medical help. In these children, there will usually be a delay in the onset of adolescent growth changes. A serious growth problem, namely dwarfism, is also seen in children with chronic ulcerative colitis. During the active phase of the disease, retardation in growth occurs, and may persist after the disease is in remission. Dwarfism or failure to grow in height over a prolonged period of observation (while the patient is on a good medical program) should be considered an indication for definitive surgery.

The most difficult patient to evaluate is the child with chronic yet intermittent disease. This patient usually responds to a good medical program, but will have one or two relapses per year. The overall effect of the disease may involve not only growth and nutrition, but the emotional development of the child as well as of the family. If the disease process continues for 5 to 10 years, and particularly through the adolescent period, surgical therapy should be considered as a means of offering a healthy existence and a new outlook to the child, as well as a means of prevention of cancer.

The possible development of carcinoma of the colon in the child who has had or still has chronic colitis is a real hazard. In 1959, Rosenqvist, Öhrling, Lagercrantz, and Edling⁵ stated that cancer of the colon developed in one third of their patients who had been followed from 11 to 22 years. In 1961, a study to determine the prognosis of chronic ulcerative colitis in children, reported 46 colon cancers in 401 children.¹ In this group of patients, carcinoma of the colon was the cause of 40 of 112 deaths. In 10 patients less than 20 years of age, carcinoma of the colon developed. If this group of patients were statistically analyzed to give the incidence of carcinoma of the colon as compared to the duration of follow-up, the results would be more similar to the series reported by Rosenqvist and associates.⁵ Statistics per se, in regard to the risk of cancer, are hardly a basis for performing surgery, but they must always be borne in mind by the physician ultimately responsible for the care of children with chronic ulcerative colitis.

Four Illustrative Case Reports

Case 1. *Toxic dilatation with perforation of the colon.* A four-year-old girl was referred to the Cleveland Clinic in February, 1962, with a diagnosis of "perforating colon secondary to ulcerative colitis." Before referral she was hospitalized for eight weeks because of bloody diarrhea. A

SURGICAL TREATMENT OF CHRONIC ULCERATIVE COLITIS

diagnosis of ulcerative colitis was made after a proctoscopic examination and a roentgenographic study after a barium-solution enema. She was treated with a low-residue diet, Azulfidine,* vitamins, and antispasmodic medications. During the course of treatment a high spiking fever and a tender distended abdomen developed. Steroids had been administered orally and intravenously, but she became more distended and toxic and was transferred to the Cleveland Clinic Hospital.

On admission distention and tenderness of the abdomen were present (*Fig. 1*). Subtotal colectomy and ileostomy were performed. The colon revealed multiple perforation sites. A large perforation had occurred in the descending colon and was walled-off by the anatomic

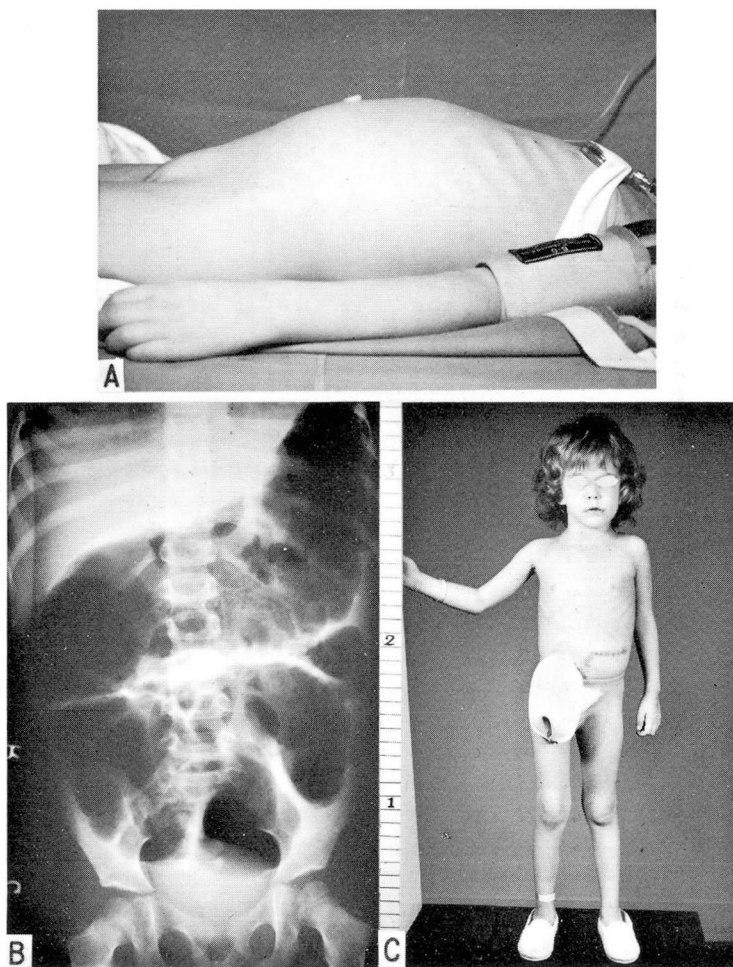


Fig. 1. Case 1 (toxic dilatation). A, photo of abdominal distention; B, toxic megacolon; C, postoperative photo of child with ileostomy.

*Pharmacia Laboratories, Inc.

gutter space. Within 24 hours postoperatively she was much improved, and was discharged from the hospital two weeks later. She has remained well for one year.

Case 2. Massive rectal hemorrhage. A 15-year-old girl was first examined at the Cleveland Clinic in August, 1948, because of a seven-year history of intermittent diarrhea attributed to chronic ulcerative colitis. She had been on medical therapy during the entire period. Her maximum weight was 115 pounds at the age of 12 years. Six months before examination, persistent severe diarrhea developed. Her weight had decreased to 85 pounds. At the time of examination her temperature was 103.2 F. orally, and she appeared to be acutely ill. The abdomen was diffusely tender, but not distended. A barium-solution enema study and proctoscopic examination revealed typical ulcerative colitis. Treatment was started with intravenous fluids, whole blood, and Sulfathalidine.* Forty-eight hours after admission to the hospital, massive rectal hemorrhage occurred. Ileostomy and subtotal colectomy were performed, and the patient had an uneventful postoperative course. Six months later she weighed 108 pounds and was asymptomatic (Fig. 2). She has continued to be well for eight years. Her growth and development have been entirely normal.

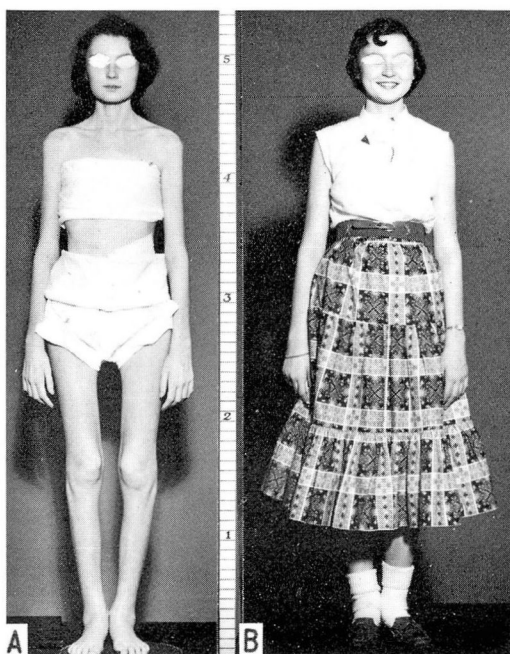


Fig. 2. Case 2 (massive rectal hemorrhage). A, preoperative photo; B, roentgenogram showing evidence of postoperative (6 months) photo of the patient.

Case 3. Dwarfism. A nine-year-old boy was examined at the Cleveland Clinic in September, 1953, because of intermittent diarrhea that developed when he was four years old. He weighed 35 pounds and was 43 inches tall (Fig. 3). He was hospitalized and was given two weeks of intensive medical therapy consisting of adrenocorticotropin (ACTH), serum albumin, Sustagen, †

*Merck, Sharp & Dohme.

†Mead Johnson Laboratories.

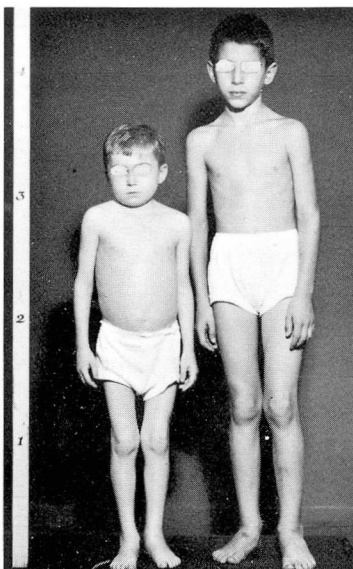


Fig. 3. Case 3 (dwarfism). Photos of the 9-year-old patient and a normal child of the same age (right).

Streptomycin sulfate,* Chloromycetin,† whole blood, and vitamins. There was some improvement, and he was discharged from the hospital to follow a medical program at home. Two weeks later he was readmitted to the hospital, because his family physician and his parents had been unable to follow the program. Because of the severe dwarfism and difficult home situation, ileostomy and subtotal colectomy were performed. Two further surgical procedures (ileostomy revision) were done during the next nine years. This boy otherwise has developed well, has no further active bowel disease, and now is in the thirtieth percentile for height and weight for his age.

Case 4. Carcinoma of the colon. A 15-year-old girl was first examined at the Cleveland Clinic in 1955 because of persistent bloody diarrhea that had first occurred when she was nine years old. At age 17 years, severe migratory polyarthritis developed. Roentgenographic examination disclosed evidence that the entire colon was severely involved by a nonspecific ulcerative colitis. She was given intensive medical therapy, including Meticorten‡ orally. She improved initially, but during the next two years had many recurrences of her disease. At the age of 19 years, toxic dilatation of the colon developed. Subtotal colectomy and ileostomy were performed. On opening the resected colon two separate carcinomas were found. Three years after surgery, she is asymptomatic.

Surgical Procedures

The surgical treatment of ulcerative colitis in children depends on the extent of

*Pfizer Laboratories.

†Parke, Davis & Company.

‡Schering Corporation.

disease present. Ordinarily the rectum is but superficially affected, and may be spared for possible ileorectal anastomosis after colectomy. In most instances, subtotal colectomy and ileostomy are performed, the distal sigmoid colon being brought out through the lower end of the abdominal incision as a mucous fistula (Fig. 4). When trimmed below the skin level, the fistula soon closes. After a year

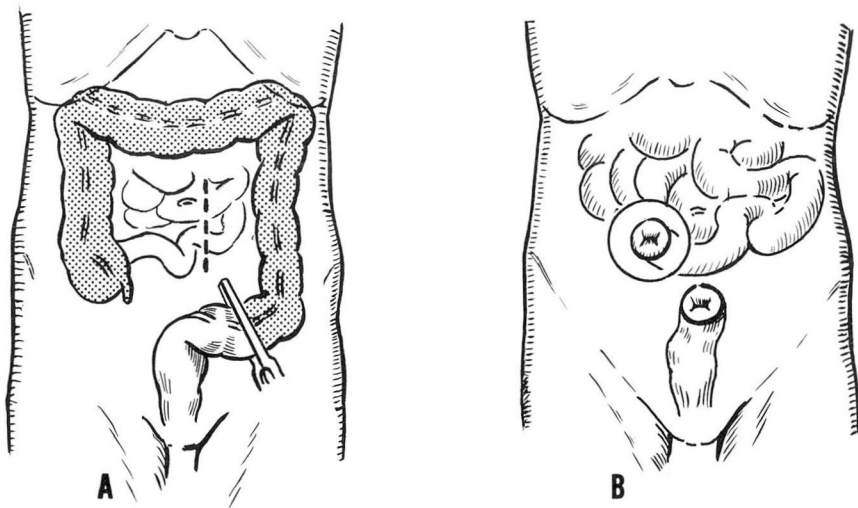


Fig. 4. Sketches showing subtotal colectomy and ileostomy. A, colon removed to distal sigmoid; B, ileostomy: the end of the sigmoid colon is brought to the skin over the pubis.

or longer, consideration is given to the feasibility of ileorectal anastomosis.

In children operated upon because of hemorrhage, the rectum may still be preserved because the bleeding has its origin above the rectum. In the child with rapidly progressive disease and toxic megacolon, the decision for surgical intervention should be made before perforation of the colon occurs. The surgeon and pediatrician together must attend the child. Progressive distention of the upper abdomen indicates dilatation of the transverse colon, and is a grave sign. If the distention is rapidly progressive, perforation takes place. In some patients, however, the dilatation may be present for some days, and then disappears as the disease responds to treatment. Unfortunately, some children with toxic megacolon arrive at the hospital after perforation has occurred. Attempts at removal of the colon result in fecal spillage, which may be fatal.

We should like to propose an operative procedure that has been satisfactory in eight adults under these circumstances (Fig. 5). The abdomen is opened on the left side as usual and, after inspection of the walled-off perforations, the ileum is divided about 8 inches proximal to the dilated cecum; the distal end is closed; and the proximal end is brought out through a previously marked site in the right lower

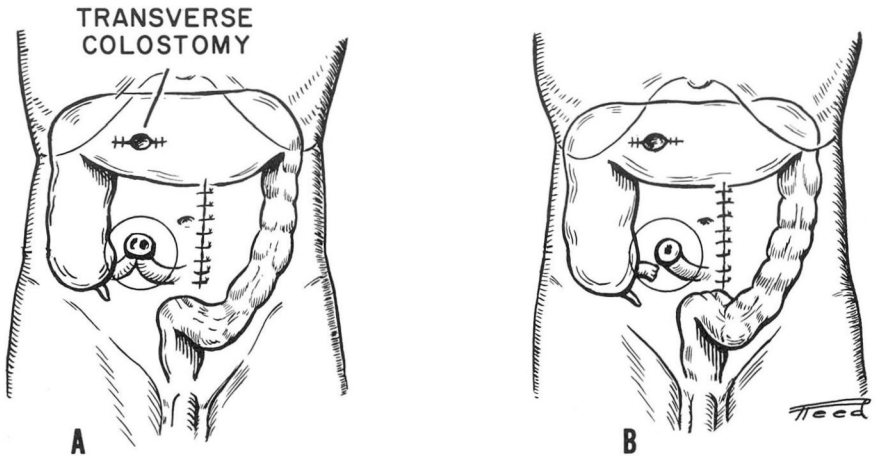


Fig. 5. Sketches showing surgical treatment of fulminating ulcerative colitis with toxic megacolon. A, transverse skin level colostomy; loop ileostomy; B, transverse colostomy and end ileostomy.

quadrant as an end ileostomy. With the left hand on the proximal dilated transverse colon (usually not perforated or fixed), a short transverse incision is made through the skin and rectus muscle high in the right upper quadrant to bring the colon into view. After the abdomen is closed, a colocolutaneous anastomosis is made at this site, after closure of the left paramedian incision. The details of construction are shown in *Figure 6*. The immediate decompression of the obstructed transverse

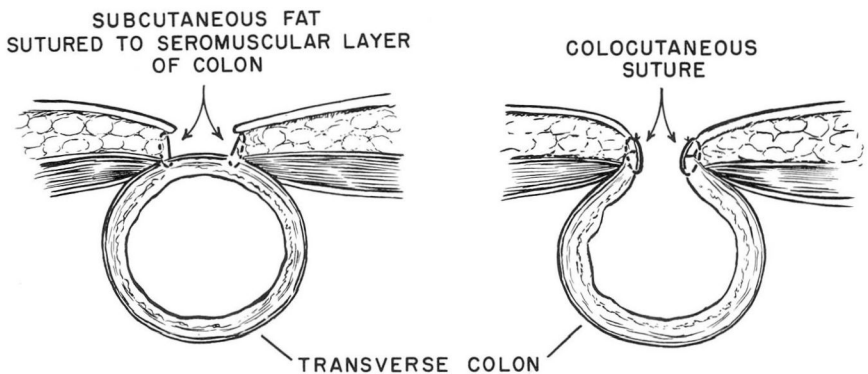


Fig. 6. Sketches showing details of construction of transverse colostomy in ulcerative colitis with toxic megacolon.

colon is sufficient to turn the tide of the disease, and to allow recovery to a point at which colectomy can be carried out under more favorable circumstances. The fecal diversion by a suitable ileostomy allows a pouch to be worn and a normally functioning-intestinal tract to support the recovery period.

Comment

Successful management of ulcerative colitis in the child or adolescent often requires the combined efforts of the pediatrician, gastroenterologist, and the surgeon. More than 50 percent of children with this disease respond to medical therapy. Most physicians are extremely hesitant to advise the removal of a child's colon and the construction of an ileostomy. If the indications for surgery are definite, the physician caring for the child should not hesitate to recommend surgery, for it may be lifesaving. After removal of the colon the child improves rapidly: the toxic symptoms disappear, physical growth ensues, and the personality blossoms. The emotional problems within the family which have arisen from the child's disease tend to disappear. The ileostomy is well accepted by the child and his parents, and in our experience does not seem to inhibit the child's normal everyday activities.

References

1. Michener, W. M.; Gage, R. P.; Sauer, W. G., and Stickler, G. B.: Prognosis of chronic ulcerative colitis in children. *New England J. Med.* **265**: 1075-1079, 1961.
2. Ehrenpreis, T.; Ericsson, N. O.; Billing, L.; Lagercrantz, R., and Rudhe, V.: Surgical treatment of ulcerative colitis in children. *Acta paediat.* **49**: 810-826, 1960.
3. Platt, J. W.; Schlesinger, B., and Benson, P.: Ulcerative colitis. *Turkish J. Pediat.* **1**: 98-109, 1958.
4. Korelitz, B. I., and Gribetz, D.: Prognosis of ulcerative colitis with onset in childhood; II. Steroid era. *Ann. Int. Med.* **57**: 592-597, 1962.
5. Rosenqvist, H.; Öhrling, H.; Lagercrantz, R., and Edling, N.: Ulcerative colitis and carcinoma coli. *Lancet* **1**: 906-908, 1959.