

# WHAT ABOUT LARGE-BOWEL POLYPS IN CHILDREN?

## A Clinicopathologic Study

FRANK L. WEAKLEY, M.D.,

*Department of General Surgery*

WILLIAM A. HAWK, M.D.,

*Division of Pathology*

and

RUPERT B. TURNBULL, JR., M.D.

*Department of General Surgery*

OF those polyps of the colon and rectum which occur in childhood, one peculiar type designated as "juvenile polyp" constitutes a significant percentage. Though for many years this lesion has been recognized as a distinct type, some of the reports do not emphasize this fact.<sup>1-7</sup> The purpose of this paper is to stress this distinction through a clinicopathologic study of 15 children with such lesions examined at the Cleveland Clinic in the last decade.

### Patients in the Series

In the period from October 1953 to October 1962, 15 patients younger than 16 years of age were treated at the Cleveland Clinic Hospital for polyps of the colon or the rectum (*Table 1*). The ages of the children ranged from 2 to 10 years,

*Table 1.—Polyps of the colon and the rectum in 15 children: summary of data*

| Patient | Age<br>in<br>years | Site of<br>polyp   | Treatment: removal at |                     | Follow-up<br>period in<br>months | Present status            |
|---------|--------------------|--------------------|-----------------------|---------------------|----------------------------------|---------------------------|
|         |                    |                    | Protoscopy            | Laparotomy          |                                  |                           |
| 1       | 2                  | Rectum             | *                     | —                   | 62                               | Asymptomatic              |
| 2       | 2                  | Sigmoid            | —                     | Sigmoid colotomy    | 113                              | Asymptomatic              |
| 3       | 3                  | Sigmoid            | —                     | Sigmoid colotomy    | 20                               | Asymptomatic              |
| 4       | 3                  | Rectum             | Polypectomy           | —                   | 13                               | Asymptomatic              |
| 5       | 4                  | Rectum and sigmoid | Coagulation           | Sigmoid resection   | 38                               | Polyp in transverse colon |
| 6       | 4                  | Rectum             | Polypectomy           | —                   | 0                                | Not known                 |
| 7       | 4                  | Rectum             | Polypectomy           | —                   | 50                               | Asymptomatic              |
| 8       | 4                  | Transverse colon   | —                     | Transverse colotomy | 50                               | Abdominal cramping        |
| 9       | 4                  | Rectum             | Polypectomy           | —                   | 73                               | Asymptomatic              |
| 10      | 5                  | Rectum             | Polypectomy           | —                   | 84                               | Asymptomatic              |
| 11      | 6                  | Rectum             | Coagulation           | —                   | 28                               | Asymptomatic              |
| 12      | 6                  | Rectum             | Polypectomy           | —                   | 53                               | Asymptomatic              |
| 13      | 8                  | Rectum             | Polypectomy           | —                   | 21                               | Asymptomatic              |
| 14      | 9                  | Rectum             | Coagulation           | —                   | 0                                | Not known                 |
| 15      | 10                 | Rectum             | Polypectomy           | —                   | 20                               | Asymptomatic              |

\*Advised but not performed by us.

the mean age being 5 years. There were 11 boys and 4 girls, a ratio of almost 3 to 1. The predominance as to males has been reported by others.<sup>2-7, 9</sup>

### Symptoms

Rectal bleeding was the only symptom common to all patients. Usually the blood was red or dark red and without clots. Sometimes it was mixed with the feces. Bleeding had been observed as recently as one week and as remotely as two years before our examinations. Pain was an inconstant symptom, but when present it was crampy or like "gas pains." Though anemia, weight loss, and evidence of chronic illness were absent, the growth rate of one patient was subnormal until a large polyp was removed from his transverse colon.

### Diagnosis

The discovery of the polyps was by proctoscopy and by roentgen examination. The lesions in 12 patients were visible by protoscopy. The use of both methods of examination disclosed the presence in one patient of three polyps in the rectum and four in the sigmoid colon.

### Treatment

The patient who had both rectal and sigmoid polyps was treated by coagulation of the rectal polyps and by sigmoid resection. All other patients had solitary polyps, 11 of which were accessible to treatment through the protoscope. Two of these patients were treated by coagulation, and eight by polypectomy. Coagulation was advised for one patient, but was not performed by us. In three patients, the polyps were higher than could be reached through the protoscope: two were in the sigmoid and one was in the transverse colon. These three patients underwent laparotomy with colotomy and polypectomy.

### Follow-up

The posttreatment period of study ranges from 13 to 113 months after initial examination; two of the children could not be traced for progress examination. The 13 children have had no further rectal bleeding and have been in good health. One child reported abdominal cramps after physical activity. One child was found to have a polyp in the transverse colon three years after initial examination. *No patient is known to have died, and in no patient has cancer been known to have developed.*

### Pathology

From the 15 patients, 11 specimens were submitted for pathologic examination. Ten specimens were resected polyps, and one specimen was a resected segment of colon bearing four pedunculated lesions.

Grossly all polyps were similar. Each appeared as a pedunculated, polypoid excrescence comprised of a slender stalk attached to a smooth spheroidal tissue mass (*Fig. 1*). The largest polyp was 2.0 cm. in diameter, the smallest approximately 0.5 cm. These polyps were a deeper red than the normal colonic mucosa. The cut surface was flecked by numerous small cysts containing glistening mucoid

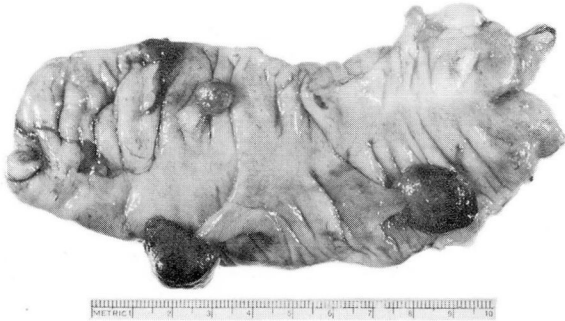

Fig. 1. Photograph of a colonic segment containing four juvenile polyps in close proximity.

material. The tissue separating the cysts was homogeneous, soft, and gray. Rare foci of hemorrhage were noted, and occasionally ill-defined areas of firmness were present.

Microscopically the polyps were comprised of variously sized glandular structures of the colonic type, enmeshed in an abundant stroma (Fig. 2). Many of the

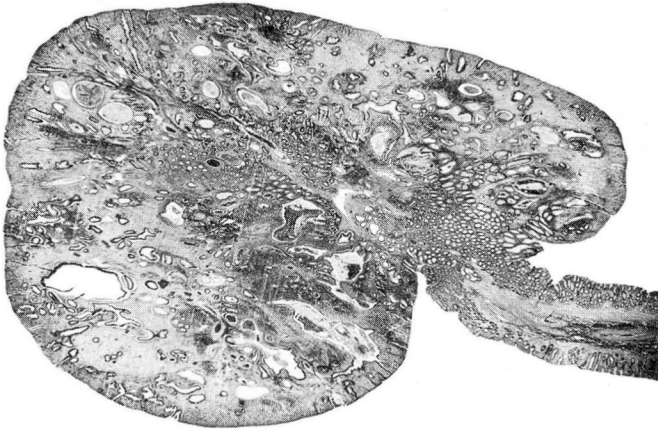


Fig. 2. A juvenile polyp that shows the abundant stroma and dilated glands. Hematoxylin-eosin-methylene blue stain; magnification X5.

glands were cystic and dilated, irregular in contour, and contained mucinous material. The smaller glands were formed of tall columnar cells and many goblet cells similar to those of normal colonic glands. However, in the dilated glands the epithelium was atrophic or notably flattened. Alcian blue and periodic acid—Schiff preparations revealed abundant mucin production (Fig. 3), and demonstrated an impressive array of goblet cells. In some of the glandular tubules there was a tendency toward hyperchromatism and pseudostratification of the epithelial elements, but the nuclear cytoplasmic ratio and polarity of the cells were not disturbed.

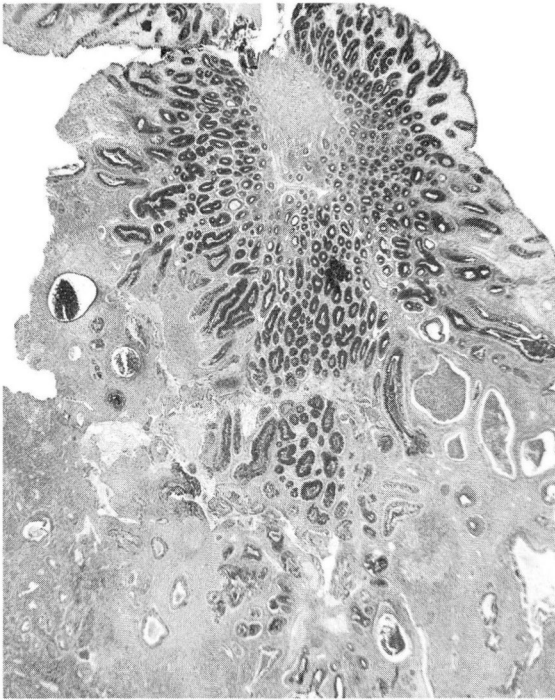


Fig. 3. A juvenile polyp that shows evidence of abundant mucus production in the dark-staining glands, particularly those that are not dilated and are near the polyp base. Periodic acid-Schiff stain; magnification X17.

The stroma was as distinctive as it was abundant (*Fig. 4*). It was highly cellular, and was formed of fibroblasts and numerous, widespread, fine capillaries suggestive of granulation tissue. Frequently there was infiltration by lymphocytes, plasma cells, histiocytes, neutrophils, and occasionally eosinophils. Lymph follicles were also observed. The density of the chronic inflammatory infiltrate was variable, seemingly influenced by the ulceration of the surface epithelium that characteristically enclosed the polyps. In addition, neutrophil aggregates were seen in the dilated, cystic, centrally located glands. Rare mitotic figures of typical configuration were noted, most particularly in glands adjoining zones of ulceration or intense inflammation.

The stalks were formed of typical colonic mucosa complete with muscularis mucosae and a small amount of submucosa. The muscularis mucosae ended abruptly at the zone of attachment of the polyp, and did not contribute to the polyp stroma. The enveloping single-layered, mucus-secreting epithelium of the polyp joined the surface epithelium of the stalk without an appreciable transitional zone.



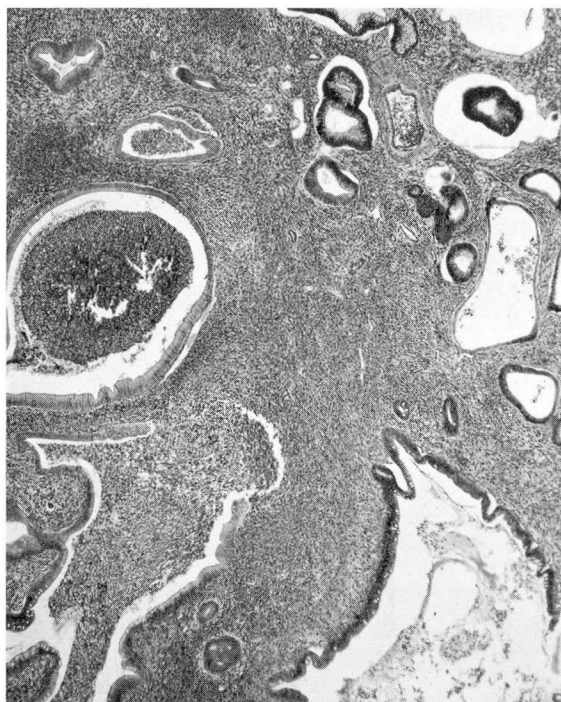


Fig. 4. A juvenile polyp that shows the cellular stroma and the cystic, dilated glands, some of which contain purulent exudate. Hematoxylin-eosin-methylene blue stain; magnification X32.

#### Comment

The common polyps of the colon and rectum have a gross and a histologic structure different from those just described. Though they are frequently pedunculated the surface of the polyp is usually finely fissured, and in some of the sessile varieties may even have a fine villous appearance. A few are formed of well-differentiated colonic glands, in arrangement closely simulating normal colonic mucosa (Fig. 5). More commonly the glands are of less orderly arrangement, often displaying hyperchromatism and pseudostratification of glandular epithelium. Such distorted glands frequently branch and form villous processes supported by delicate stromal cores. Mucin production and the presence of goblet cells are well defined in the well-differentiated variety, and to these the term "adenomatous polyp" has been applied. The more complex variety displaying fronding we designate as "papillomatous polyps" (Fig. 6). It is in this latter group that hyperchromatism, increased mitotic activity, and pseudostratification of columnar epithelium with fewer goblet cells may be observed. In this group, foci of carcinoma in situ and occasionally invasive carcinoma may be found. In all of these polyps the stroma is inconspicuous, and in the adenomatous polyp it may appear similar to normal

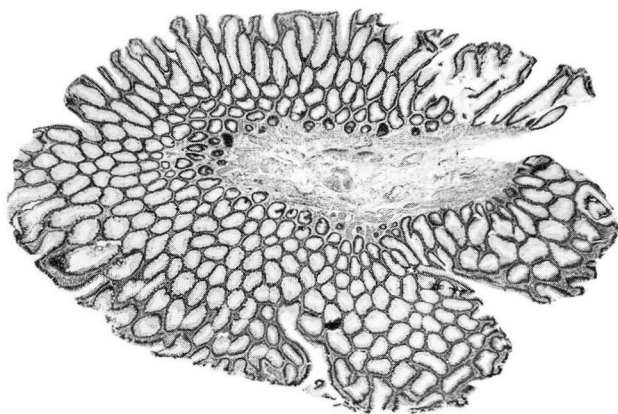


Fig. 5. An adenomatous colonic polyp that shows glandular structure closely approximating normal colonic epithelium in contrast to that of the papillomatous type of polyp. Hematoxylin-eosin-methylene blue stain; magnification X12.

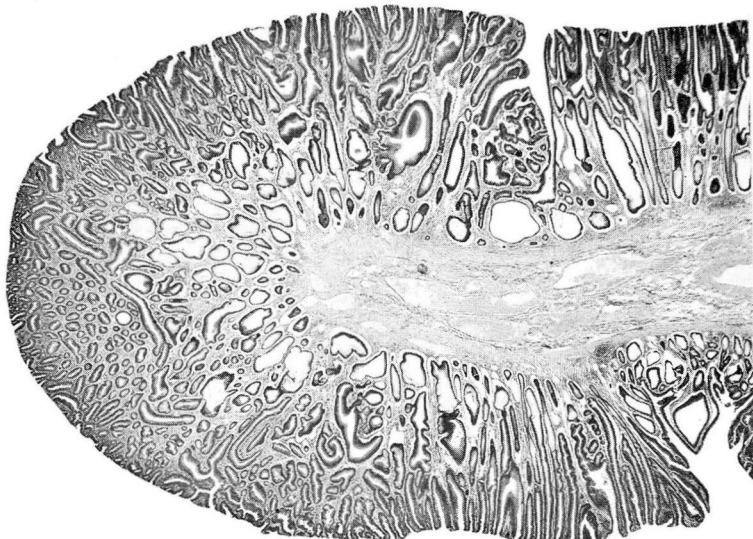


Fig. 6. A representative papillomatous polyp that shows the villous areas, hyperchromatism, and pseudostratification of glandular epithelium. Hematoxylin-eosin-methylene blue stain; magnification X12.

lamina propria. In the papillomatous group it is fibrous and vascular, and, at the base of the polyp, it may be dense and the muscularis mucosae of the colon is tented up into the polyp base.

Morson<sup>8</sup> has ably described the details of the juvenile polyp, and has pointed out the difference between it and the other colonic polypoid lesions. He states that the juvenile polyp may represent an abnormality of the mucosal connective

tissue, and that the stroma bears some resemblance to primitive mesenchyme, thus suggesting that this lesion is a hamartoma and not an adenoma. From the material reviewed in our study there is much agreement with Morson's views. Roth and Helwig<sup>9</sup> have suggested that the juvenile polyp represents a polypoid transformation of a local submucosal inflammatory process. The most striking reasons for segregating these lesions from the usual adenomas of the colon are that these lesions lack the usual papillomatous pattern; they have a peculiarly abundant, characteristic stroma; they appear much more prone to a severe inflammatory change; mucous retention-cysts are prominent; and shreds of the muscularis mucosae are conspicuously absent from the polyp stroma.

### Discussion

Juvenile polyps have not been proved to be premalignant. In no child having a juvenile polyp has carcinoma of the colon or rectum, arising from such a polyp, been known to have developed. The symptomatic juvenile polyps must be removed, but only the most conservative measures should be used.

When numerous small polyps are present, representative excisional biopsy should be performed to establish the type of polyp; if they are juvenile polyps, thorough coagulation should suffice. Larger polyps should be excised through the proctoscope if possible, or by means of laparotomy with colotomy and polypectomy, if necessary. Asymptomatic colonic polyps may be observed and not otherwise treated if rectal polyps simultaneously present are of the juvenile type. Segmental colon resection should be done only when the juvenile polyps are sufficiently numerous and localized to indicate that this procedure would be the safest and most expedient method of management.

### Summary

Fifteen children treated at the Cleveland Clinic Hospital between October 1953 and October 1962 were found to have juvenile polyps of the large bowel. The location and treatment of these polyps and the status of these patients after a follow-up period of from 13 to 113 months are reported.

The gross and microscopic characteristics of these juvenile polyps are compared with the characteristics of the more familiar types of polyps of the large bowel. The juvenile polyp is largely formed of colonic glands, many of which are cystically dilated, enmeshed in a stroma that simulates granulation tissue, frequently with a dense inflammatory infiltrate. It is suggested that the juvenile polyp is more characteristic of a hamartoma than of an adenoma.

It is emphasized that conservative, local excision of the juvenile polyp should be employed, since there is no known relationship between juvenile polyps and cancer of the rectum or colon.

## References

1. Lane, J. R.: Clinical observations on diseases of rectum. *Lancet* **2**: 87-88, 1865.
2. Horrilleno, E. G.; Eckert, C., and Ackerman, L. V.: Polyps of rectum and colon in children. *Cancer* **10**: 1210-1220, 1957.
3. Knox, W. G.; Miller, R. E.; Begg, C. F., and Zintel, H. A.: Juvenile polyps of colon. Clinicopathologic analysis of 75 polyps in 43 patients. *Surgery* **48**: 201-210, 1960.
4. Mauro, J., and Prior, J. T.: Gastrointestinal polypoid lesions in childhood. *Cancer* **10**: 131-137, 1957.
5. Helwig, E. B.: Adenomas of large intestine in children. *Am. J. Dis. Child.* **72**: 289-295, 1946.
6. Kennedy, R. L. J.; Dixon, C. F., and Weber, H. M.: Polypoid lesions of colon in children. *Surg. Gynec. & Obst.* **77**: 639-644, 1943.
7. Kerr, J. G.: Polyposis of colon in children. *Am. J. Surg.* **76**: 667-671, 1948.
8. Morson, B. C.: Some peculiarities in histology of intestinal polyps. *Dis. Colon & Rectum* **5**: 337-344, 1962.
9. Roth, S. I., and Helwig, E. B.: Juvenile polyps of colon and rectum. *Cancer* **16**: 468-479, 1963.