

## TRUE HERMAPHRODITISM: REPORT OF A CASE WITH CHROMOSOMAL ANALYSIS

DERRICK LONSDALE, M.D., ROBERT D. MERCER, M.D.,

*Department of Pediatrics*

and

E. PERRY McCULLAGH, M.D.

*Department of Endocrinology and Metabolism*

THE word *hermaphrodite* comes from the myth of Hermaphroditus, a son of Hermes and Aphrodite, who, while bathing became joined in one body with a nymph. The clinical term describes a person who possesses both male and female organs, and many subdescriptions are used. The term *pseudohermaphrodite* is misleading and ambiguous, and should be used with care in describing a clinical situation, particularly when masculinization of a female or femininization of a male is produced by disease or drugs.

This report describes a true hermaphrodite who was proved to have both male and female gonads and, in particular, describes an unusual chromosomal pattern in the cells of this person.

### Report of a Case

A 12½-year-old boy was first examined at the Cleveland Clinic in September 1960. At the age of 10 years he had been examined by another physician because of urethral hypospadias and absence of scrotal testes. The referring physician stated that the hypospadias was repaired and a left orchiopepy was attempted. The left inguinal contents had been described as "atrophic" and fixed in the groin, and they were therefore removed; microscopic examination showed a hernial sac containing immature ovary, uterus, and fallopian tubes. Examination of the contents of the sac on the right side showed the presence of a fallopian tube with an immature ovary and an immature testis. He had been taking fluoxymesterone,\* 2 mg. daily, for approximately one and one-half years before examination here, and had gained some increase in stature.

On examination here, he was 53¾ inches tall, and weighed 67 pounds. The blood pressure was 122/84 mm. of Hg. He was well nourished and had a masculine appearance. The fourth toe of each foot was underdeveloped, and there was extreme pes planus deformity of the feet. Hair growth in the axilla and over the pubis was slight. The scrotum contained prosthetic testicles. The penis was average in size for the age of the boy. There was a scar on the under-surface from surgical correction of a hypospadias, and the urethral orifice was situated distally on the ventral surface of the penis. On rectal examination there was no palpable prostate. Findings on the remainder of the physical examination were normal. Roentgen examination of the hands revealed a congenitally short fourth metatarsal bone, and the bone age of the wrist corresponded approximately to that of a boy aged 11 years, 6 months. A buccal smear showed that none of the 100 cells exhibited the sex chromatin mass. Psychometric evaluation revealed an I.Q. of approximately 97. Color vision by the Ishihara test was normal. A course of testosterone enanthate, † 200 mg. injected intramuscularly every two weeks, was started. He was last examined in January 1962, one year and four months after initial examination. His height was 57¾ inches, and his weight 94 pounds. The penis appeared larger than average for the age of 14 years. There was adequate facial and pubic hair, and muscular development was normal for his age. This improvement was thought to be due entirely to the androgen therapy that he had received continuously.

Blood was drawn for analysis of chromosomes and was processed by a modification of the method described by Moorhead and associates.<sup>1</sup> One hundred and forty cells were examined

\*Halotestin, The Upjohn Company.

†Delatestryl, E. R. Squibb & Sons.

under the microscope for a chromosomal count, and 33 cells were photographed for detailed analysis. Twenty-one karyotypes showed a modal number of 46 chromosomes with an XY sex chromosomal complement. In addition, in 83 percent of the cells examined there was a chromosomal fragment present which was slightly larger than the satellites seen on any one of the acrocentric chromosomes. *Tables 1 and 2* show the distribution of the chromosomal counts and the karyotypes.

Table 1.—*Distribution of chromosomal counts in a true hermaphrodite*

Number of cells	Chromosomal count*								
	Less than 45		45		46		More than 46		
	+F	-F	+F	-F	+F	-F	+F	-F	
Total	140	3	1	12	10	98	12	4	0
Analyzed	33	1	—	7	—	22	3	—	—

\* +F = chromosomal fragment present; -F = chromosomal fragment absent.

Table 2.—*Analysis of chromosomal count in a true hermaphrodite*

Number of chromosomes	Number of cells	Chromosomes, type
< 45	1	XY +F (random loss)
45	4	XO +F
		XY +F (random loss)
46	1	XX +F
	3	XY -F
	21	XY +F
Fragment	83.3 percent	

It would appear that the major stem-line cell contains 46 chromosomes with XY sex chromosomes. There were 22 cells with a 45 chromosomal complement, and karyotypes were made from seven of these. Four of the seven showed a sex chromosomal complement XO. However, it is possible that all the cells with aneuploidy demonstrated only random loss and therefore do not represent a stem line. Thirty cells had more or less than the standard 46 chromosomes, which represents 21 percent of the total cells counted, a much larger variation than is usually seen.

### Discussion

A classification of patients having true hermaphroditism into three groups was described by Hinman.<sup>2</sup> Group I, called *bilateral*, included any person having a testis and an ovary, either separate or united as an ovotestis. Group II, called *unilateral*, included any person having a testis and an ovary, either separate or united, on one side, and either a testis or an ovary on the other side. Group III, called *alternating*, included any person with a testis on one side and an ovary on the other.

True hermaphroditism is relatively uncommon, and some confusion has arisen in the past because of attempts to classify it without defining the exact nature of the gonads. By definition, both male and female gonadal tissue must be present in true hermaphroditism, and histologic diagnosis of both gonads is necessary. Serial sections are essential for accurate diagnosis, because an ovotestis can be sectioned at the pole to reveal only testicular elements. Lewis<sup>3</sup> described 15 cases and reported a total of 89 cases from the literature. Only seven of his 15 cases were studied for chromatin, and five were chromatin positive and two, chromatin negative. Grumbach and Barr<sup>4</sup> presented a comprehensive review of sex chromatin studies in the true hermaphrodite, and pointed out that chromatin-positive persons were more common than chromatin-negative in the ratio of approximately 3 to 1. It is only in recent years that the sex chromosomes have been studied in true hermaphroditism, and there are relatively few cases reported to date with chromosomal analysis.<sup>5-9</sup>

Many theories have been offered as to the etiology of this condition, and much interest has centered around accidental nondisjunction, mosaicism, genetic anomaly, and the masculinizing effect of the Y chromosome. Armstrong and associates<sup>10</sup> described a true hermaphrodite who was chromatin positive but with Barr bodies said to be smaller than usual. They found that the patient's blood group was O, but that no anti-B substance was detectable in the serum; they postulated that the condition resulted from a genetic anomaly.

Griboff and Lawrence<sup>11</sup> advanced an ingenious theory. They stated that a primordial testis will lead to the retention of wolffian duct structures on the same side, and that an ovotestis will cause retention both of müllerian and of wolffian systems, with müllerian predominating. If an ovary is present, or no gonad, the müllerian system prevails. They postulated that the presence of ovaries indicates categorically the presence of two X chromosomes or the equivalent in genetic complement, and suggest that translocation of the genes from one X chromosome to an autosome is a possibility. Testicular elements, they believe, depend on the presence of male-determining genes from the Y chromosomes, which may be translocated in a similar fashion.

Harnden and Armstrong<sup>5</sup> described a case with XX karyotype, and discussed the masculinizing features associated with the lack of a Y chromosome. They mentioned the possibility of mosaicism, but were unable to find evidence of another stem-line cell. Harnden and Stewart<sup>12</sup> reported a phenotypic female who had a chromatin-negative smear and an XY karyotype, and they postulated that something more than the Y chromosome is required for maleness. German, Bearn, and McGovern<sup>6</sup> described three chromatin-positive cases in each of which the karyotypes were XX. They found various degrees of development of wolffian and müllerian systems, and suggested that the Y chromosome is not essential to the development of the testis.

Another possibility is described by Gartler, Waxman, and Giblett<sup>7</sup> who re-

ported a case in which the karyotype was a mosaic of XX/XY. They discussed the possibility of a double fertilization by two genetically different sperms fertilizing two egg nuclei, thus giving rise to approximately equal halves of one individual. This child had a normal ovary on the left and an ovotestis on the right, and different colors of the eyes (heterochromia simplex). Some further impetus was given to the idea of a genetic cause from the description of two families in which two true hermaphrodite siblings had occurred in each.<sup>13, 14</sup>

The case described here is unusual because of the presence of a chromosomal fragment and there have been only a few reports of this phenomenon. There is now considerable evidence that an abnormal autosome occurs in many cases of chronic myelogenous leukemia,<sup>15</sup> but whether this is a deleted chromosome is not yet clear. Most of the explanations advanced for the presence of chromosomal fragments are concerned with deletion of one or other of the sex chromosomes in cases of sex development. Ferguson-Smith, Johnston, and Weinberg<sup>8</sup> described two true hermaphrodites, each with XX sex chromosomal complement and each was chromatin positive. In one of the cases three cells showed an additional fragment that was described as being "... reminiscent of an isochromatid deletion." They suggested that it was the centromere-bearing remains of the Y chromosome which had taken part in a translocation and had persisted in a small proportion of the cells.

Another case was reported<sup>9</sup> of a patient who had normal female genitalia with no breast tissue and who was obese and hirsute. She was chromatin negative. Chromosomal analysis was carried out and 56 cells were studied. Thirty cells each showed 45 chromosomes with one X chromosome, and 26 cells each showed 46 chromosomes that included one normal X and a chromosomal fragment. The fragment was approximately half the size of a 22 chromosome, and was interpreted as a deleted Y chromosome. The authors did not refer to histologic examination of the gonads. They expressed the belief that the male features in their patient resulted from the deleted Y chromosome.

Vaharu and associates<sup>16</sup> reported a case of gonadal dysplasia with an enlarged phallus in a girl. The chromosomes showed a complement of 45 with one normal X chromosome and a fragment present in each cell that was analyzed. The fragment was described as half the size of the 22 chromosome and was interpreted as a deleted Y. They mentioned the possibility of the presence of some testicular elements in the dysplastic gonads. A further possibility lies in a deletion of one X chromosome. Such a case was reported in a woman with primary amenorrhea.<sup>17</sup> Of 500 cells in a buccal smear, only 36 had chromatin bodies and these were regarded as smaller than usual. The chromosomal complement was 46, with a normal X chromosome, and a fragment that was regarded as a deleted X chromosome and the cause of the unusually small chromatin bodies.

TRUE HERMAPHRODITISM

There are several possible explanations for our case. The high percentage of cells that carry the fragment indicates the presence of a kinetochore, which is necessary for replication. In some cells the fragment was visible, as a double structure, as demonstrated on the karyotype shown in *Figure 1*, and this suggests that it is a small telocentric chromosome with terminal placement of the kinetochore. There are at least four possibilities for its origin: (1) partial deletion of the X chromosome, (2) partial deletion of the Y chromosome, (3) partial deletion of an autosome, and (4) a mutual translocation between two chromosomes with the extrusion of a small fragment.

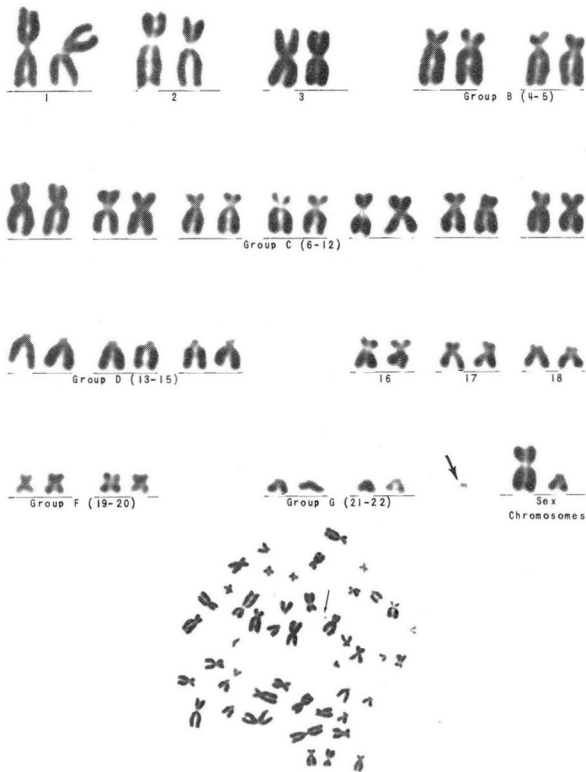


Fig. 1. Karyotype of a true hermaphrodite. The chromosomal fragment (arrows) is shown in comparison with the sex chromosomes. Wright's stain; magnification X1800.

A partial deletion of the X chromosome is ruled out because no chromatin bodies were visible in the cells of a buccal smear. It has been mentioned that it would be expected that a number of small bodies would be visible if this fragment

were a partially deleted X chromosome. The second possibility is the partial deletion of a Y chromosome. This could arise from a nondisjunction at the second meiotic division of a Y-bearing sperm, and would give the individual a sex-chromosome complement of  $XY_{\gamma}$  where  $\gamma$  were a deleted Y chromosome. The third possibility, partial deletion of an autosome, is vague because we do not yet know the part played by autosomes in sexual differentiation. The fourth possibility, mutual translocation between two chromosomes, is an interesting mechanism that is known to occur in *Drosophila*. The genetic relationships and balance exerted by position-effect (that is, the net change in genes from their usual position on one chromosome to a position on another chromosome) is still an unknown factor in human genetics. Certainly it is usual for a small fragment to be extruded when a mutual translocation takes place, and the new chromosome produced by such a situation may not be recognizable by present technics. Frequently the fragment is lost in further divisions of the cell.

The origin of the fragment is not subject to proof at this time, and it is even possible that the chromosomal anomaly is entirely unrelated to the clinical presentation of the syndrome. Unfortunately, we do not know whether or not either one of the sexually normal parents possesses a chromosomal fragment. The presence of a parental fragment would suggest that it is merely a supernumerary chromosome exerting no sexual genetic effect.

#### Summary

A clinical description is given of a true hermaphrodite. The presence of a chromosomal fragment in 83.3 percent of the cells from a peripheral blood culture is unusual, and suggests that the fragment was a chromosomal deletion with a kinetochore. A brief review of the literature is given, and discussion centers around the possibilities for the origin of the chromosomal fragment and its relationship to the clinical condition.

#### Acknowledgments

The authors herewith thank Dr. M. A. Ferguson-Smith, Department of Genetics, the University of Glasgow, Glasgow, Scotland, for review of the chromosomal analysis, and suggestions as to the etiology of the fragment; and Miss Martha K. Keller for technical assistance.

#### References

1. Moorhead, P. S.; Nowell, P. C.; Mellman, W. G.; Battips, D. M., and Hungerford, D. A.: Chromosome preparations of leukocytes cultured from human peripheral blood. *Exper. Cell Res.* **20**: 613-616, 1960.
2. Hinman, F.: *The Principles and Practice of Urology*. Philadelphia: W. B. Saunders Co., 1935; 1111 p.; p. 134.
3. Lewis, E. L.: True hermaphrodite. Clinical and psychological study. *J. Urol.* **81**: 309-314, 1959.

4. Grumbach, M. M., and Barr, M. L.: Cytologic tests of chromosomal sex in relation to sexual anomalies in man. *Recent Prog. Hormone Res.* **14**: 255-324; discussion, 324-334, 1958.
5. Harnden, D. G., and Armstrong, C. N.: Chromosomes of true hermaphrodite. *Brit. M. J.* **5162**: 1287-1288, 1959.
6. German, J. L., III; Bearn, A. G., and McGovern, J. H.: Chromosomal studies of three hermaphrodites. *Am. J. Med.* **33**: 83-87, 1962.
7. Gartler, S. M.; Waxman, S. H., and Giblett, F.: An XX/XY human hermaphrodite resulting from double fertilization. *Proc. National Acad. Sc.* **48**: 332-335, 1962.
8. Ferguson-Smith, M. A.; Johnston, A. W., and Weinberg, A. N.: Chromosome complement in true hermaphroditism. *Lancet* **2**: 126-128, 1960.
9. Ferrier, P.; Gartler, S. M.; Waxman, S. H., and Shepard, T. H.: Abnormal sexual development associated with sex chromosome mosaicism. Report of three cases. *Pediatrics* **29**: 703-713, 1962.
10. Armstrong, C. N.; Gray, J. E.; Race, R. R., and Thompson, R. B.: Case of true hermaphroditism. Further report. *Brit. M. J.* **2**: 605-606, 1957.
11. Griboff, S. I., and Lawrence, R.: Chromosomal etiology of congenital gonadal defects. *Am. J. Med.* **30**: 544-563, 1961.
12. Harnden, D. G., and Stewart, J. S.: Chromosomes in case of pure gonadal dysgenesis. *Brit. M. J.* **5162**: 1285-1287, 1959.
13. Milner, W. A.; Garlick, W. B.; Fink, A. J., and Stein, A. A.: True hermaphrodite siblings. *J. Urol.* **79**: 1003-1009, 1958.
14. Clayton, G. W.; Smith, J. D., and Rosenberg, H. S.: Familial true hermaphroditism in pre- and postpuberal genetic females. Hormonal and morphologic studies. *J. Clin. Endocrinol.* **18**: 1349-1359, 1958.
15. Nowell, P. C., and Hungerford, D. A.: Minute chromosome in human chronic granulocytic leukemia. (Abs.) *Science* **132**: 1497, 1960.
16. Vaharu, T.; Patton, R. G.; Voorhess, M. L., and Gardner, L. I.: Gonadal dysplasia and enlarged phallus in girl with 45 chromosomes plus "fragment." *Lancet* **1**: 1351, 1961.
17. Jacobs, P. A.; Harnden, D. G.; Court Brown, W.; Goldstein, J.; Close, H. G.; MacGregor, D. N.; MacLean, N., and Strong, J. A.: Abnormalities involving X chromosome in women. *Lancet* **1**: 1213-1216, 1960.