

AN EXTRA ABNORMAL CHROMOSOME IN A CHILD WITH MONGOLISM AND ACUTE MYELOBLASTIC LEUKEMIA

Report of a Case

ROBERT D. MERCER, M.D., MARTHA K. KELLER, B.S.,*

and

DERRICK LONSDALE, M.D.

Department of Pediatrics

THE purpose of this paper is to report the case of a child who had mongolism and acute myeloblastic leukemia, in whom chromosomal analyses demonstrated two populations of cells. One of these populations showed the typical trisomy of chromosome 21 with the 47 chromosomal count of mongolism. The second population was of cells with trisomy-21 plus an extra medium-sized metacentric chromosome in group C (6-12). We were consistently able to find the cells with 48 chromosomes more easily in 24-hour cultures than in the usual 72-hour cultures.

Report of a Case

A 16-month-old Negro girl was admitted to the Cleveland Clinic Hospital on November 27, 1962, because of acute leukemia. She was the thirteenth living child in the family. The father was 42 years old and the mother 39 years old at the time of the child's admission to this hospital. All of the siblings were said to be in good health.

The child was said to be the product of a normal pregnancy and a normal delivery and was reported to have had a birth weight of 6½ pounds. She breathed poorly and sucked poorly in the immediately neonatal period, and considerable mucus was present in the pharynx. At six weeks of age jaundice was present and she was given a blood transfusion at her local hospital. The cause of this jaundice is not known.

The child was well, aside from slowness in her developmental progress, until November 15, 1962, when pallor was noted. She was admitted to the Aultman Hospital, Canton, Ohio. Blood analysis showed a hemoglobin content of 4.1 gm., a hematocrit reading of 15 percent, red blood cells 1,650,000, and white blood cells 13,300 per cubic millimeter. The platelet count was 16,500 per cubic millimeter with 21 percent blast forms in the smear of the peripheral blood. A diagnosis of acute leukemia was made by Dr. James S. Adler, her referring physician. The child was given a blood transfusion and was transferred to the Cleveland Clinic Hospital.

Upon admission here the child appeared pale, listless, and chronically ill. Numerous petechiae were present over the trunk, extremities, mucous membranes, and conjunctivas. The liver and the spleen were grossly enlarged. The general appearance of the child was that of mongolism (*Fig. 1*). The epicanthic folds were prominent; Brushfield spots were present on the irises; the joints were hypermobile, and the hands and the feet showed the usual configuration without well-developed Simian creases.

The initial blood studies showed a hemoglobin content of 5.4 gm. with a hematocrit reading of 16 percent. The white blood cell count was 18,000 per cubic millimeter, with 58 percent blasts. Granules were present within some of these, and promyelocytes and myelocytes could be identified. The bone marrow was largely replaced with stem cells and blasts, with many immature cells in the granulocytic series. A diagnosis of acute myeloblastic leukemia was made.

After a blood transfusion the child was treated with 6-mercaptopurine, 25 mg. daily, and prednisone, 5 mg. daily. There was no particular improvement in her hematologic condition over the next three weeks. On December 11, 1962, a complete thymectomy was performed

*Medical Technologist (ASCP) in the Department of Pediatrics.

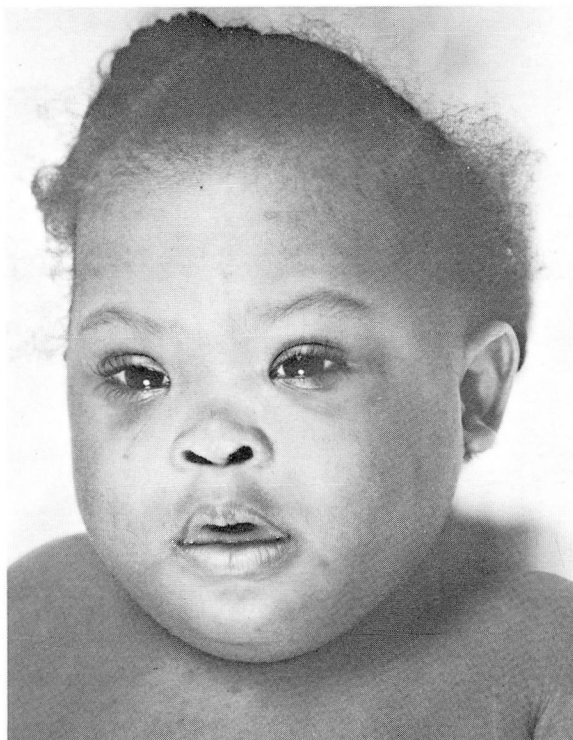


Fig. 1. Photo of 16-month-old Negro girl with mongolism and leukemia.

through a cervical incision as part of a study of that procedure in malignant disease. No beneficial effect of the operation could be observed. Although this child was thrombopenic and hemorrhagic at the time of the operation, bleeding was not excessive and she tolerated the procedure with no difficulty.

Over the next few weeks there was some clinical improvement and a partial hematologic remission. By December 28, 1962, the white blood cell count was 5,800 per cubic millimeter, with 5 percent blast forms in the differential count. A complete hematologic remission did not take place. On January 27, the 6-mercaptopurine therapy was discontinued and a course of amethopterin was started in a dosage of 5 mg. every other day. The child's general condition continued to deteriorate, and after a profuse nasal hemorrhage she died on February 6, 1963. No autopsy examination was made.

Chromosome Studies

Cultures of the peripheral blood and bone marrow were made by a modification¹ of the technic described by Moorhead and associates.² The cells were harvested either after 24 hours or after 72 hours. Six cultures were prepared; a total of 294 cells was counted and 54 karyotypes were constructed.

Culture 1. Blood was first obtained for culture on November 29, 1962. This was after a transfusion but before other treatment. At that time the white blood cells were 18,000 per cubic millimeter with 58 percent blasts. This culture was not

satisfactory, but a few cells could be found after 72 hours of culture to establish the chromosome count at 47 with trisomy-21, and the diagnosis of mongolism was confirmed.

Culture 2. Peripheral blood was cultured on December 5, 1962. At that time the child was being treated with 6-mercaptopurine and prednisone. The white blood cell count was 12,500 per cubic millimeter with 60 percent blasts. The cell concentrate from this culture was prepared for study after 24 hours of incubation. Microscopic counts were made on 50 cells; in each of 46 cells there were 48 chromosomes, and in four cells each, 47 chromosomes. Karyotypes were constructed from photomicrographs of five cells with a chromosome count of 48, and from one cell with a chromosome count of 47. All cells demonstrated trisomy-21. The cells with 48 chromosomes contained in addition an extra chromosome in group C (6-12). One member of the number 2 chromosome pair was unusually large (Fig. 2).

Culture 3. Peripheral blood was prepared on December 28, 1962, when the disease was in a partial remission. The white blood cell count was 5,800 per cubic millimeter with 5 percent blasts. The cells were cultured for three days. Microscopic counts were made on 50 cells; 48 each contained 47 chromosomes, and two each contained 46 chromosomes. Ten cells were photographed and were counted: each contained 47 chromosomes. Karyotypes made from five of these photomicrographs showed only the trisomy-21 of mongolism (Fig. 3).

Culture 4. Bone marrow was cultured on January 16, 1963. At that time the white blood cell count was 19,000 per cubic millimeter with 58 percent blast forms. Cells were harvested after 24 hours of incubation. Microscopic counts of 46 cells showed 44 each with 48 chromosomes, and two each with 47 chromosomes. Both cells with 47 chromosomes, and 10 of the cells with 48 chromosomes were photographed, and karyotypes were constructed from the photomicrographs. The cells with 47 chromosomes demonstrated trisomy-21. All 10 cells with 48 chromosomes demonstrated an extra chromosome in group C (6-12). In each instance one member of the number 2 chromosome pair was unusually large.

Culture 5. On January 17, 1963, the peripheral blood count was the same as that on the day previously, but 61 percent of blasts were present in the differential count. Aliquots of this blood sample were cultured for 24 hours and for 72 hours. One hundred cells of the 24-hour preparation were counted under the microscope. Ninety-two of these each had a chromosome count of 48, seven had a chromosome count of 47, and one cell had a chromosome count of 46. Karyotypes were made from photomicrographs of 10 of the cells with 48 chromosomes; these showed trisomy-21, an extra chromosome of group C (6-12), and an unusually large member of the number 2 chromosome pair. Karyotypes made of four of the cells with 47 chromosomes showed only trisomy-21. One of these cells showed what we believe to be random loss of one of the chromosomes in group F (19-20) and probably actually had a 48 chromosomal count. One member of the number 2

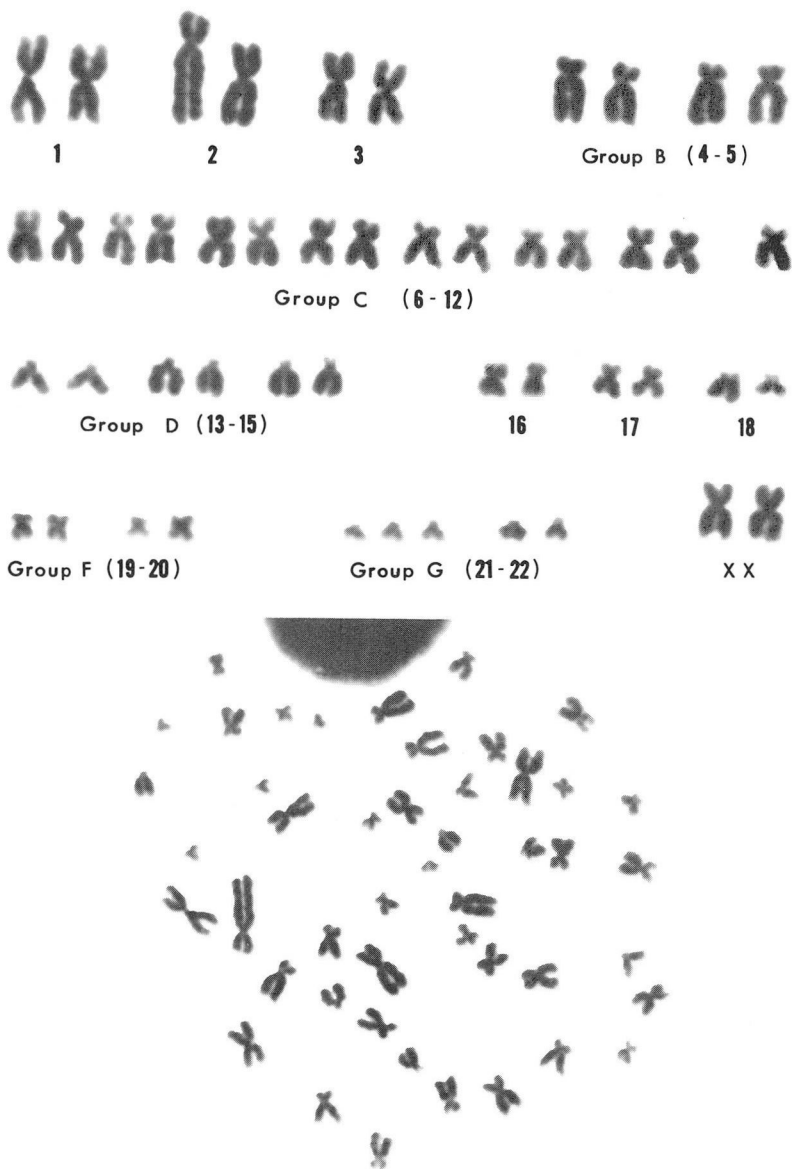


Fig. 2. Karyotypes made from 24-hour culture of the peripheral blood showing cell with 48 chromosomes. There is an extra medium-sized metacentric chromosome in group C (6-12), and one member of the number 2 chromosome pair is unusually large.

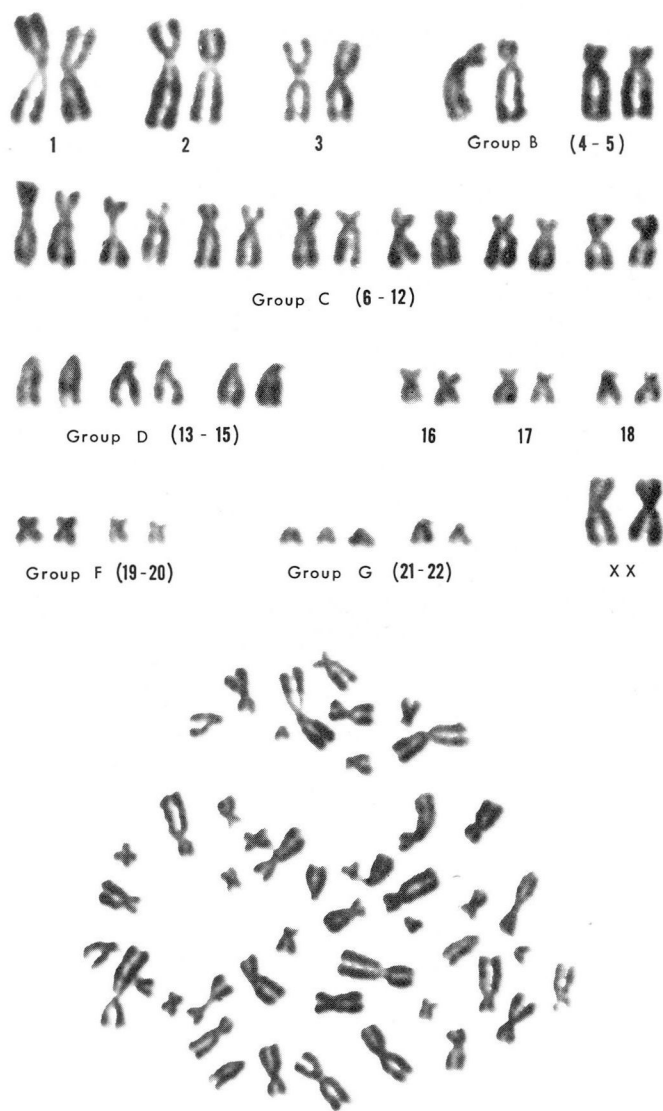


Fig. 3. Karyotype made from a 72-hour culture of the peripheral blood, demonstrating a chromosome count of 47 and the usual trisomy-21 of mongolism.

pair of chromosomes was unusually large in this cell. The other three cells with a 47 chromosome count each had an unusually large member of the number 2 chromosome pair. It is possible that there was random loss in the group C (6-12) chromosomes in these cells.

Culture 6. The three-day culture of the peripheral blood drawn on January 17, 1963, is considered as culture 6. This was, however, part of the same blood specimen as culture 5. In this preparation 45 cells were counted under the microscope. Forty-seven chromosomes were present in each of 38 cells, 46 chromosomes in each of seven cells. Karyotypes were made from photomicrographs of 10 cells with 47 chromosomes. All of these demonstrated trisomy-21 and in no instance was there an unusually large member of the number 2 chromosome pair. Karyotypes were made from photomicrographs of four cells with 46 chromosomes. Three of these demonstrated trisomy-21 with what we assume to be random loss in the group of medium-sized metacentric chromosomes, which includes the group C (6-12) group plus the sex chromosomes. One cell demonstrated only four small acrocentrics in group G (21-22).

The chromosomal data are presented in *Table 1*. It was our conclusion from

Table 1.—*Chromosome counts in a 16-month-old girl with mongolism and leukemia*

Culture	White blood cell count, per cu. mm.	Blasts, percent	Time of culture, hr.	Chromosome count			Total number of cells		Comment
				46	47	48	Counted	Analyzed: no. of cells/no. of chromosomes	
1	18,000	58	72	—	3	—	3	3	Unsatisfactory culture, trisomy-21.
2	12,500	60	24	—	4	46	50	{ 1/47 5/48	Extra chromosome in group C(6-12) in cells with 48 chromosomes.
3	5,800	58	72	2	48	—	50	5/47	Typical mongol trisomy-21.
4	19,000	58	24	—	2	44	46	{ 2/47 10/48	{ Bone marrow culture. Cells with 47 chromosomes showed trisomy-21. Cells with 48 chromosomes contained extra chromosome in group C(6-12).
5	19,000	61	24	1	7	92	100	{ 4/47 10/48	{ Probable random loss in cells with 47 chromosomes. Cells with 48 chromosomes contained extra chromosome in group C(6-12).
6*	19,000	61	72	7	38	—	45	{ 4/46 10/47	{ Typical mongol trisomy-21 in cells with 47 chromosomes. Probable random loss in cells with 46 chromosomes.

*Aliquot of blood sample used from culture 5.

this study that the child had two populations of cells in the peripheral blood. The cell with 48 chromosomes could best be demonstrated in 24-hour cultures. The cell with 47 chromosomes was best demonstrated in the customary 72-hour culture. This is particularly evident from the data of cultures 5 and 6, which were aliquots of a single blood sample. We believe that the differences in chromosome counts do not bear a relationship to the severity of the leukemic process.

Discussion

The normal human somatic cell contains 46 chromosomes. These include 22 pairs of autosomes and a pair of sex chromosomes.³ An extra chromosome producing a total count of 47 has been observed in the majority of patients with mongolism.⁴⁻⁷ The extra chromosome is small, acrocentric, and similar to one of the members of pairs 21 or 22 by the Denver classification.⁸

The presence of an abnormal, unusually small, acrocentric chromosome has been described in many cases of chronic myeloid leukemia.⁹⁻¹³ This small chromosome is presumably one of the members of chromosomal pairs 21 or 22. It has been designated the *Pb*¹ chromosome to indicate Philadelphia, the geographic location of the laboratory in which it was first observed.⁹ It has been suggested that the *Pb*¹ chromosome results from a translocation or a deletion, and that it may carry on it a genetic locus concerned with leukopoiesis.^{11, 12}

The observation that there is a raised incidence of acute leukemia in patients with mongolism seems to have been firmly established.¹⁴⁻¹⁸ A possible biologic relationship between these two conditions was suggested by Krivit and Good in 1956.¹⁴ Others^{11, 12, 18} have studied the chromosomal patterns of patients with both mongolism and leukemia but until recently "... the only consistent abnormality has been typical of mongolism itself."¹⁸

Alterations in number, and abnormalities other than the *Pb*¹ chromosome, have been found in cases of leukemia.¹⁹⁻²⁷ The consensus, particularly as regards acute leukemia of childhood, is that visible chromosomal changes are probably not of etiologic importance in relation to this disease.²⁷

Ford^{22, 24} mentioned an interesting patient with acute blast-cell leukemia in which there were two populations of cells. One of these populations was cells with the normal 46 chromosomes; the other had 48 chromosomes with an extra small chromosome difficult to distinguish from the Y, and an extra medium-length metacentric chromosome. Details of the appearance of this patient were not given but it is interesting to speculate that he might have been a mongol mosaic with leukemia.

Scattered observations have been reported of 48 chromosomes in persons with mongolism and acute leukemia. Two of the five cases described by Tough and associates¹² showed a few cells each with 48 chromosomes, but they concluded that "... in none of these was any chromosome abnormality found other than that associated with mongolism." Johnston²⁸ described many abnormalities in chromosomal number with fragments and breaks in the cells of a child with mongolism and leukemia. Three cells of 161 counted before treatment each showed 48 chromosomes with an extra chromosome in group C (6-12). Sandberg²⁹ also mentions a few cells each with 48 chromosomes in one mongol with acute lymphoblastic leukemia and one with acute myeloblastic leukemia.

Ross and Atkins³⁰ have reported a unique patient, a girl with mongolism with

49 chromosomes including seven small acrocentrics. She had a prolonged remission of leukemia after corticosteroid therapy. Five months before her death, at a time when there was no hematologic evidence of leukemia, a culture of peripheral blood demonstrated only the typical findings of mongolism. Three weeks before her death, cells each with 49 chromosomes were present. Cultures were prepared from a single sample of blood, one of which was harvested at two days and one at three days. In the two-day culture, practically all of the cells each contained 49 chromosomes with seven small acrocentric chromosomes. In the three-day culture, there were two cell populations: about 75 percent of the cells each contained 47 chromosomes with five small acrocentrics, and 25 percent of the cells each contained 49 chromosomes with seven small acrocentrics.

Vincent and associates³¹ have recently described a remarkable case of multiple chromosome abnormalities in a child with mongolism and acute myeloblastic leukemia. Many cells were found each with 49 chromosomes, in each of which were an abnormal pair of large metacentrics similar to chromosome pair number 3, an extra chromosome in group C(6-12), monosomy in group F(19-20), and trisomy-21. They found a significantly greater proportion of abnormal cells in three- and four-day cultures than they did in two-day cultures.

The case that we describe is similar to that described by Warkany, Schubert, and Thompson.³² Their patient was a two-year-old girl with mongolism and acute myeloblastic leukemia. Before treatment, the majority of cells studied demonstrated 48 chromosomes with an extra chromosome in group C(6-12) and trisomy-21. After treatment with 6-mercaptopurine and amethopterin the majority of cells studied showed 47 chromosomes with trisomy-21. A minority of the cells still showed 48 chromosomes each with an extra chromosome in group C(6-12). Warkany and associates³² related these changes to the treatment of the leukemia.

Summary

The chromosomal analysis of a 16-month-old girl with mongolism and acute myeloblastic leukemia is reported. This child demonstrated two different populations of cells. One group of cells contained 48 chromosomes with an extra chromosome in group C(6-12) and trisomy-21. The second group of cells contained 47 chromosomes with only trisomy-21. Differences in the time of culture seemed the important factor in demonstrating the differences in the cell population. It is possible that in this case the leukemic cell contains an extra abnormal chromosome and grows at a different rate in tissue culture than does the cell typical of mongolism.

References

1. Keller, M. K., and Mercer, R. D.: Modification of "Moorhead Technic" for chromosomal analysis. *Cleveland Clin. Quart.* 30: 233-240, 1963.
2. Moorhead, P. S.; Nowell, P. C.; Mellman, W. J.; Battips, D. M., and Hungerford, D. A.: Chromosome preparations of leukocytes cultured from human peripheral blood. *Exper. Cell. Res.* 20: 613-616, 1960.

3. Tjio, J. H., and Puck, T. T.: Genetics of somatic mammalian cells. II. Chromosomal constitution of cells in tissue culture. *J. Exper. Med.* **108**: 259-268, 1958.
4. Lejeune J.; Gauthier, M., and Turpin, R.: Les chromosomes humains en culture de tissus. *Compt. rend. Acad. Sc.* **248**: 602-603, 1959.
5. Lejeune, J.; Gautier, M., and Turpin, R.: Étude des chromosomes somatiques de neuf enfants mongoliens. *Compt. rend. Acad. Sc.* **248**: 1721-1722, 1959.
6. Jacobs, P. A.; Baikie, A. G.; Court-Brown, W. M., and Strong, J. A.: Somatic chromosomes in mongolism. *Lancet* **1**: 710, 1959.
7. Böök, J. A.; Fraccaro, M., and Lindsten, J.: Cytogenetical observations in mongolism. *Acta paediat.* **48**: 453-468, 1959.
8. Böök, J. A.; Lejeune, J., and Levan, A.: Proposed standard system of nomenclature of human mitotic chromosomes. *Lancet* **1**: 1063-1065, 1960.
9. Nowell, P. C., and Hungerford, D. A.: Chromosome studies on normal and leukemic human leukocytes. *J. Nat. Cancer Inst.* **25**: 85-109, 1960.
10. Nowell, P. C., and Hungerford, D. A.: Minute chromosome in human chronic granulocytic leukemia. (Abs.) *Science* **132**: 1497, 1960.
11. Baikie, A. G.; Court-Brown, W. M.; Buckton, K. E.; Harnden, D. G.; Jacobs, P. A., and Tough, I. M.: Possible specific chromosome abnormality in human chronic myeloid leukaemia. *Nature* **188**: 1165-1166, 1960.
12. Tough, I. M.; Court-Brown, W. M.; Baikie, A. G.; Buckton, K. E.; Harnden, D. G.; Jacobs, P. A.; King, M. J., and McBride, J. A.: Cytogenetic studies in chronic myeloid leukaemia and acute leukaemia associated with mongolism. *Lancet* **1**: 411-417, 1961.
13. Nowell, P. C., and Hungerford, D. A.: Chromosome studies in human leukemia. II. Chronic granulocytic leukemia. *J. Nat. Cancer Inst.* **27**: 1013-1035, 1961.
14. Krivit, W., and Good, R. A.: Simultaneous occurrence of leukemia and mongolism. *A.M.A. J. Dis. Child.* **91**: 218-222, 1956.
15. Merrit, D. H., and Harris, J. S.: Mongolism and acute leukemia; report of 4 cases. *A.M.A. J. Dis. Child.* **92**: 41-44, 1956.
16. Stewart, A.; Webb, J., and Hewitt, D.: Survey of childhood malignancies. *Brit. M. J.* **5086**: 1495-1508, 1958.
17. Stewart, A.: Aetiology of childhood malignancies: congenitally determined leukaemias. *Brit. M. J.* **5224**: 452-460, 1961.
18. Wald, N.; Borges, W. H.; Li, C. C.; Turner, J. H.; and Harnois, M. C.: Letter to editor. Leukaemia associated with mongolism. *Lancet* **1**: 1228, 1961.
19. Ford, C. E.; Jacobs, P. A., and Lajtha, L. G.: Human somatic chromosomes. *Nature* **181**: 1565-1568, 1958.
20. Baikie, A. G.; Court-Brown, W. M.; Jacobs, P. A., and Milne, J. S.: Chromosome studies in human leukaemia. *Lancet* **2**: 425-428, 1959.
21. Ford, C. E., and Mole, R. H.: Letter to editor. Chromosome studies in human leukaemia. *Lancet* **2**: 732, 1959.
22. Ford, C. E.: Chromosomes of normal human somatic and leukaemic cells. *Proc. Roy. Soc. Med.* **53**: 491-493, 1960.

23. Sandberg, A. A.; Koepf, G. F.; Crosswhite, L. H., and Hauschka, T. S.: Chromosome constitution of human marrow in various developmental and blood disorders. *Am. J. Human Genet.* **12**: 231-249, 1960.
24. Ford, C. E.: Chromosomal abnormalities in leukaemic cells, p. 1-7, *Proc. Eighth Congress European Society of Haematology*, Vienna, 1961.
25. Wahrman, J.; Schaap, T., and Robinson, E.: Manifold chromosome abnormalities in leukaemia. *Lancet* **1**: 1098-1100, 1962.
26. Baikie, A. G.; Court-Brown, W. M., and Jacobs, P. A.: Letter to editor. Chromosome studies in leukaemia. *Lancet* **1**: 615, 1961.
27. Hungerford, D. A.: Chromosome studies in human leukemia. I. Acute leukemia in children. *J. Nat. Cancer Inst.* **27**: 983-1011, 1961.
28. Johnston, A. W.: Chromosomes in child with mongolism and acute leukemia. *New England J. Med.* **264**: 591-594, 1961.
29. Sandberg, A. A.; Ishihara, T.; Miwa, T., and Hauschka, T. S.: In vivo chromosome constitution of marrow from 34 human leukemias and 60 nonleukemic controls. *Cancer Res.* **21**: 678-689, 1961.
30. Ross, J. D., and Atkins, L.: Letter to editor. Chromosomal anomaly in mongol with leukaemia. *Lancet* **2**: 612-613, 1962.
31. Vincent, P. C.; Sinha, S.; Neate, R.; Dulk, G. D., and Turner, B.: Letter to editor. Chromosome abnormalities in mongol with acute myeloid leukaemia. *Lancet* **1**: 1328-1329, 1963.
32. Warkany, J.; Schubert, W. K., and Thompson, J. N.: Chromosome analyses in mongolism (Langdon-Down syndrome) associated with leukemia. *New England J. Med.* **268**: 1-4, 1963.