

## PRESUMED TRANSLOCATION OF CHROMOSOME NUMBER 2 AND ONE OF THE D GROUP

ROBERT D. MERCER, M.D., and GHAZAR DARAKJIAN, M.D.\*

*Department of Pediatrics*

THE translocation of human chromosomes was reported in 1959 by Turpin and associates.<sup>1</sup> Their patient was an infant with multiple anomalies of bone. A chromosome count of 45 was found in cells of skin from three different biopsies. Several karyotypes demonstrated an absence of one of the small meta-centric chromosomes. The authors suggested that it represented a 13/22 chromosomal translocation. No similar case has at this time been found in the medical literature.

Chromosomal translocation in patients with mongolism, and in the relatives of mongoloid children has been reported many times since it was first recorded by Polani and associates<sup>2</sup> in 1960. In most instances the translocation is presumed to be 15/21.<sup>3-10</sup> Presumed translocations 21/21 and 21/22 have also been suggested.<sup>3, 7, 11</sup> Hamerton and associates<sup>7</sup> reported the possible presence of an isochromosome for the long arm of chromosome 21 in a father and in his son, both of whom probably had chromosomal mosaicism. They suggested a similar explanation for the abnormality reported by Fraccaro, Kaijser, and Lindsten.<sup>11</sup> Gray, Mutton, and Ashby<sup>12</sup> suggested pericentric inversion of a maternal 21 chromosome as an explanation for a closely similar abnormality observed in the karyotypes of a mother and her mongoloid daughter.

Chromosomal translocation in group D (13-15) in a patient with Klinefelter's syndrome was described in 1960 by Lejeune, Turpin, and Decourt.<sup>13</sup> Family studies involving a group D (13-15) chromosomal translocation have been reported by Walker and Harris,<sup>14, 15</sup> and by Jagiello,<sup>16</sup> who reported associated mental retardation, spastic diplegia, and talipes equinovarus.

The purpose of this paper is to describe the clinical appearance and to report the chromosomal analysis of a boy with presumed translocation of chromosome number 2 and one of the large acrocentric chromosomes of the D group.

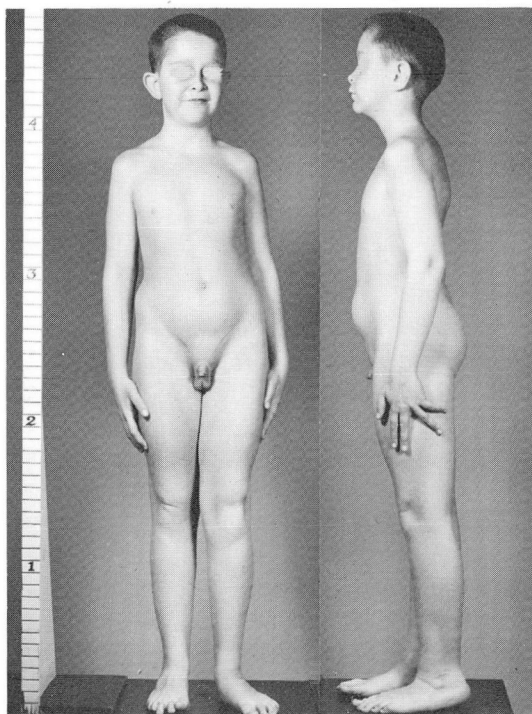
### Report of a Case

A 12-year-old white boy was examined at the Cleveland Clinic on March 14, 1962, because the parents were concerned about his unsatisfactory school record. As to prenatal data, the mother stated that there was some bleeding during the first trimester of pregnancy. The child was born by breech delivery about six weeks before the estimated date of confinement, his birth weight being 4 pounds and 2 ounces. In the neonatal period, the baby sucked poorly, and jaundice was present for a few days. There was no history of excessive vomiting or of paroxysmal fussiness. During early infancy an operation was performed for "club feet." The child started to walk at 18 months; the parents believed that his orthopedic problems were responsible for his delayed progress. During early childhood, operations were performed

\*Formerly Fellow in the Department of Pediatrics; present address: Tailleur Pailoun Bab-ed Riss, Beirut, Lebanon.

for undescended testicles and for large protruding ears, otherwise his health had been normal. The mother stated that as a small child he was always active. She was concerned because he seemed unable to maintain average achievement in his school, although each year he was promoted into the succeeding grade. She also stated that he "never seemed to act like other children," and that he seemed unusually immature and to have no sense of responsibility.

The general physical examination revealed an average-sized boy for his age. His general body contours were unusual with narrow shoulders and prominent, rounded hips (*Fig. 1*).



**Fig. 1.** The patient, aged 12 years. Note the large ears, narrow shoulders, prominent hips, and feet which showed hypermobility.

Various abnormalities, difficult to define, were present. The head was unusually rounded; the eyes were deepset with unusual infraorbital dark circles. The ears were floppy, large, and deficient in cartilage. A speech defect was noticeable with an articulation problem and excessive escape of air through the nose on phonation. The palate appeared normal. The neck was not webbed. The chest was narrow; he stood with sloping shoulders, the muscles of which appeared to be atrophic, but muscular power was at a functional level. There was hypermobility of all joints, which was particularly easy to demonstrate on passive hyperextension of the fingers. The abdomen was normal. The trunk was short in proportion to the legs. A deep pilonidal sinus was present. The genitalia seemed normal for his age. The testes were normal on palpation. The patellae were unusually high, and a thick fat pad could be palpated deep to the patellar tendons. The range of motion of both knees was full; the left knee tended to go into hyperextension. There was considerable laxity of the ligamentous structures of the feet and, on standing, both feet had flattened arches. On the left foot particularly, the os calcis would supinate beneath the talus, and the navicular would drop down, creating essentially a rocker-bottom foot. His gait was odd, springy, and clumsy.

The skull appeared normal on roentgenograms; the spine showed evidence of a left unilateral sacrolization of the fifth lumbar vertebra; the femoral neck on the left side was in the valgus position. The blood hemoglobin concentration, routine blood cell counts, and urinary

sediment were normal. Two separate urinary 17-ketosteroid assays were 3.9 mg. and 4.7 mg. per 24 hours. The approximate gonadotropin assay was more than 13 and less than 105 mouse units per 24 hours. An electroencephalogram was basically normal, but demonstrated occasional high-amplitude, irregular, slow, sharp waves maximal over the right fronto-centro-temporal region.

Psychologic tests using the Stanford-Binet Form L-M were performed. His chronologic age was 12 years and 5 months; his mental age was 10 years and 2 months, yielding an intelligence quotient of 83. His basal age accomplishment was at 8 years, with effort through 13 years. His visual memory and perception were poor.

#### Chromosomal Analysis

Chromosomes were studied in cells cultured\* from the peripheral blood by a modification of the technic of Moorhead and associates.<sup>17</sup> Two separate cultures were prepared; the findings were similar in each culture. Photomicrographs of good technical quality of 62 cells were analyzed in detail. The chromosome counts† were:

Number of chromosomes	41	42	43	44	45
Number of cells	1	1	2	4	54

All cells that were photographed and all other cells seen clearly under the microscope contained an unusually large submetacentric chromosome (*Fig. 2*).

Karyotypes of all cells with a count of 45 chromosomes each demonstrated a single member of the normally paired number 2 chromosomes plus an additional large submetacentric chromosome. In each cell there were only five large acrocentric chromosomes. We were unable to determine whether the missing acrocentric chromosome was from pairs 13, 14, or 15. For purposes of illustration it was assigned to the position of number 15.

The upper arms of the large chromosome are identical to the upper arms of the single number 2 chromosome. The total length of the large chromosome is approximately that of the combined length of the number 2 chromosome plus one of the D group chromosomes. Most of the large chromosomes demonstrated a secondary constriction at the junction of the lower and middle thirds of the long arms.

Karyotypes were also made of each cell with a chromosome count of less than 45. In each instance the large chromosome and only five of the D group (13-15) chromosomes were present. The karyotypes demonstrated random loss of chromosomes other than of the D group.

Chromosome studies of the patient's entire family were completed. Multiple karyotypes were normal. A large member of the number 2 pair of chromosomes was seen in one of the mother's cells, in two of the father's cells, and in three of a sibling's cells. Two other siblings were completely normal as to chromosomal analysis. We attach no particular significance to the presence of an occasional large chromosome in these studies.

\*The colchicine used in this study was generously provided as Colcemide by the Ciba Pharmaceutical Company, Summit, New Jersey.

†The minor discrepancies in chromosome counts reported here as compared to those in our previous brief mention of this case<sup>18</sup> are due to the fact that in this final study, photomicrographs of all acceptable cells have been karyotyped. Five cells were discarded because of poor technical quality.

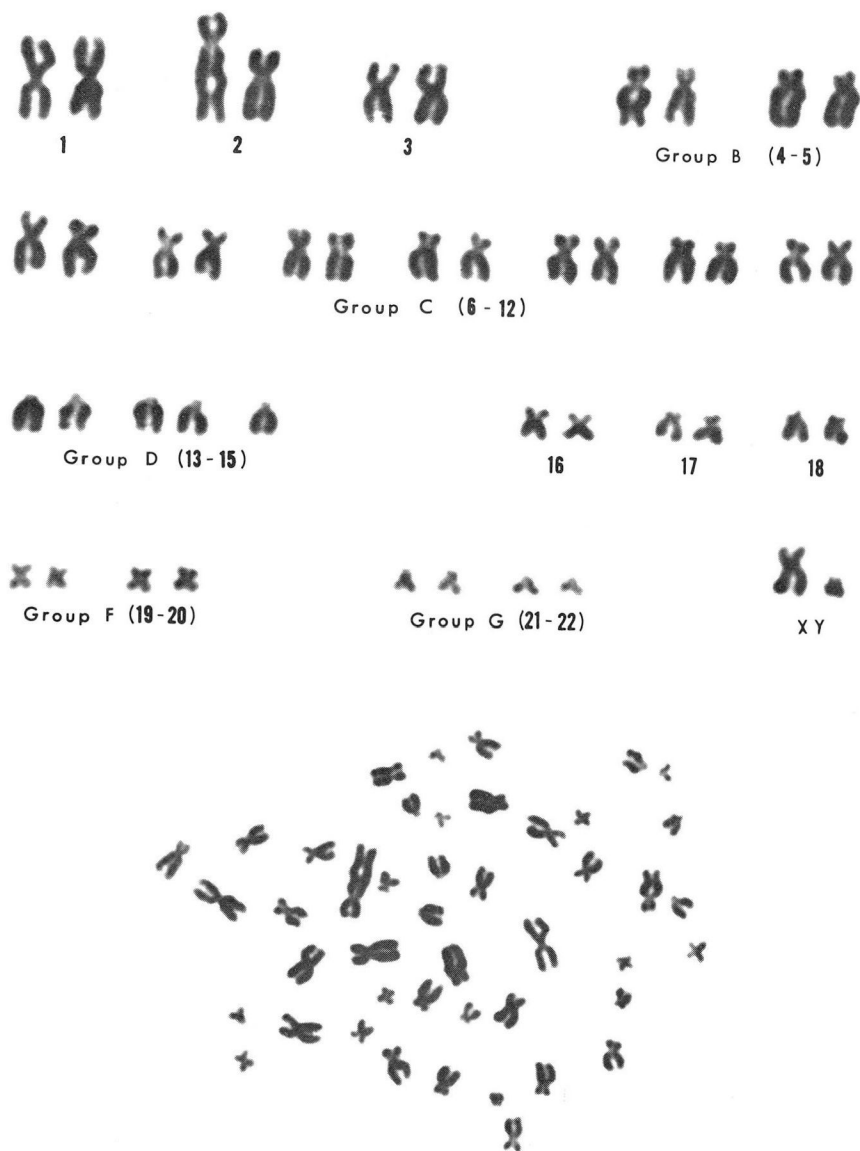


Fig. 2 Photomicrograph showing typical karyotype that demonstrates 2/D translocation. The missing chromosome in the D group is arbitrarily assigned to position number 15.

## Discussion

The previously mentioned reports of translocation syndromes in humans consist of the case of multiple anomalies described by Turpin and associates,<sup>1</sup> various types of translocations seen in mongoloid persons and their relatives,<sup>2-12</sup> and translocations in the group D (13-15).<sup>13-16</sup> A 2/D translocation syndrome has not previously been described, although a brief report of the present case has been published.<sup>18</sup>

Abnormally large chromosomes have been observed in tissues of patients with Waldenström's macroglobulinemia by Bottura, Ferrari, and Veiga,<sup>19</sup> by German, Biro, and Bearn,<sup>20</sup> and by Benirschke, Brownhill, and Ebaugh.<sup>21</sup> In the study of Bottura and associates,<sup>19</sup> of a 71-year-old man, 41 of 100 cells counted had 46 chromosomes, and 49 cells had 47 chromosomes. The cells with 46 chromosomes had a normal karyotype, but a large chromosome was present in all but five of the cells with 47 chromosomes. A secondary constriction can be seen in the long arms of the chromosome that is shown. This chromosome is described as being the same size as the largest pair in the set, with a metacentric "almost subterminal" centromere.<sup>19</sup> This chromosome was not so large as the one described by us, and chromosomal translocation was not present.

The large chromosome reported by German and associates<sup>20</sup> was from a 32-year-old woman who had Waldenström's macroglobulinemia. Four of 90 cells studied from a culture of peripheral blood each demonstrated 47 chromosomes, 86 cells each had 46, and one cell had 45 chromosomes. Karyotypes of cells with 46 chromosomes showed no abnormality. Each of the four blood cells with 47 chromosomes contained an abnormally large chromosome. This large chromosome was unique in that it was larger than any of the other chromosomes in the cell and its centromere was exactly in the middle. The possibility that it was an isochromosome involving the long arms of chromosome number 2 has been suggested.<sup>20, 22</sup>

The case reported by Benirschke and associates<sup>21</sup> was similar to that of Bottura and associates<sup>19</sup> in that of 48 cells counted, 32 each had 46 chromosomes, and 11 each had 47 chromosomes. The large chromosome was found in each of the cells with a 47 count, and the chromosome resembled that described by German and associates<sup>20</sup> in its size and in the position of its centromere; it did not resemble the chromosome described by Bottura and associates.<sup>19</sup> Benirschke and associates<sup>21</sup> believed that the evidence was insufficient to assert that the large chromosome was derived from the normal number 2 chromosome.

Unusually large chromosomes in various other conditions have been described. None of these are associated with a translocation. Baikie and associates<sup>23</sup> found an abnormally large submetacentric chromosome in each of three cells in a preparation made from a woman with acute leukemia; there was great variation in her chromosome count. The karyotype was not illustrated. Wahrman, Schaap, and Robinson<sup>24</sup> described a giant chromosome and many other abnormalities in a

case of chronic myeloid leukemia. Harnden and Armstrong<sup>25</sup> noted an abnormally long chromosome in 7 percent of the cells in one of four cultures of the skin of a true hermaphrodite. They considered this to be an aberration arising in the culture. Fraccaro and associates<sup>26</sup> described a long metacentric chromosome similar to chromosome number 3 occurring in each of three chromatin-positive women with gonadal dysgenesis. They suggest that this could be an isochromosome for the long arm of one X chromosome. Blumel, Ohnuki, and Awa<sup>27</sup> reported an unusually large chromosome with a subterminal centromere in a brother and sister both of whom had "aspastic spastic" cerebral palsy. They suggested that translocation on the X chromosome in the mother is a possible mechanism responsible for the condition in the children.

A translocation of one of the acrocentric chromosomes of the D group to chromosome number 2 is not readily explainable. Shaw<sup>28</sup> has noted the unusual frequency with which acrocentric chromosomes are found adjacent and at right angles to chromosome number 1 with the satellited end of the acrocentric chromosome pointing towards the centromere of chromosome number 1. Edwards<sup>29</sup> stated that this centromeric attraction is also seen in chromosomes numbers 2 and 3. Ferguson-Smith and Handmaker<sup>30</sup> postulated that the frequency with which chromosomal anomalies involve the acrocentric chromosomes may be related to their role in the organization of the nucleoli. Ohno and associates<sup>31</sup> in their discussion of nucleolus organizers have greatly clarified this problem by remarking that all five pairs of acrocentric chromosomes may carry nucleolus organizers on their short arms. The nucleolus-organizing section stains poorly because of the deficiency of desoxyribosenucleic acid, and is known as the S.A.T. (sine acido thymonucleino)-zone. The chromatin material distal to the S.A.T.-zone is known as a satellite. In early prophase these nucleolus-organizing chromosomes tend to cooperate in forming a common nucleolus. Ohno and associates<sup>31</sup> believe that the close proximity of the centromeric regions of the acrocentric chromosomes and the great stretching of the S.A.T.-zones which occur at the time of the organization of the nucleolus may explain the breaks and the possible translocations between these chromosomes.

We would assume that in our patient a break occurred near the centromere of one of the chromosomes of the D group. The mechanism of the translocation of the long arms of this acrocentric chromosome to the long arms of chromosome number 2 is not known. The centromeric attraction of chromosome number 2 for the satellited end of one of the D chromosomes may be of importance. It is possible that a break near the end of the long arms of the number 2 chromosome has occurred with reciprocal translocation to the short arms of the D chromosome. In this instance we would expect to find an unusually small chromosome or fragment to be present; however, such a small chromosome was not visible in the preparation.



## Summary

A case is presented of a 12-year-old boy with a presumed 2/D chromosomal translocation. The clinical features of this syndrome are characterized by multiple minor abnormalities including large protuberant ears, narrow shoulders, rounded hips, generalized hypotonia, and low-normal intelligence. The literature in reference to translocation syndromes and to abnormally large chromosomes is summarized. The mechanism of the presumed translocation is not known.

## Acknowledgments

The authors wish to thank Dr. Wayne H. Borges, Children's Hospital, Pittsburgh, Pennsylvania, for his gracious help and instruction in their initial studies of chromosomal abnormalities. The authors also wish to thank Dr. M. Neil Macintyre, The School of Medicine of Western Reserve University, Cleveland, Ohio; and Dr. Susumu Ohno, City of Hope Medical Center, Duarte, California, for their helpful discussion of the case presented here.

## References

1. Turpin, R.; Lejeune, J.; LaFourcade, J., and Gautier, M.: Aberrations chromosomiques et maladies humaines. La polydyspondylie à 45 chromosomes. *Compt. rend. Acad. Sc.* **248**: 3636-3638, 1959.
2. Polani, P. E.; Briggs, J. H.; Ford, C. E.; Clarke, C. M., and Berg, J. M.: Mongol girl with 46 chromosomes. *Lancet* **1**: 721-724, 1960.
3. Penrose, L. S.; Ellis, J. R., and Delhanty, J. D. A.: Chromosomal translocations in mongolism and in normal relatives. *Lancet* **2**: 409-410, 1960.
4. Carter, C. O.; Hamerton, J. L.; Polani, P. E.; Gunalp, A., and Weller, S. D. V.: Chromosome translocation as cause of familial mongolism. *Lancet* **2**: 678-680, 1960.
5. Forssman, H., and Lehmann, O.: Letter to editor. Translocation—carrying phenotypically normal males and Down syndrome. *Lancet* **1**: 1286, 1961.
6. Ek, J. I.; Falk, V.; Bergman, S., and Reitalu, J.: Male mongoloid with 46 chromosomes. *Lancet* **2**: 526-527, 1961.
7. Hamerton, J. L.; Briggs, S. M.; Giannelli, F., and Carter, C. O.: Chromosome studies in detection of parents with high risk of second child with Down's syndrome. *Lancet* **2**: 788-791, 1961.
8. Hamerton, J. L.; Cowie, V. A.; Giannelli, F.; Briggs, S. M., and Polani, P. E.: Differential transmission of Down's syndrome (mongolism) through male and female translocation carriers. *Lancet* **2**: 956-958, 1961.
9. Breg, W. R.; Miller, O. J., and Schmickel, R. D.: Chromosome studies in mongolism with particular reference to translocation. (Abs.) *Tr. Soc. Pediat. Res. Am. J. Dis. Child.* **102**: 578-579, 1961.
10. Macintyre, M. N.; Staples, W. I.; Steinberg, A. G., and Hempel, J. M.: Familial mongolism (trisomy-21 syndrome) resulting from a "15/21" chromosome translocation in more than three generations of large kindred. *Am. J. Human Genet.* **14**: 335-343, 1962.

11. Fraccaro, M.; Kaijser, K., and Lindsten, J.: Chromosomal abnormalities in father and mongol child. *Lancet* **1**: 724-727, 1960.
12. Gray, J. E.; Mutton, D. E., and Ashby, D. W.: Pericentric inversion of chromosome 21. Possible further cytogenetic mechanism in mongolism. *Lancet* **1**: 21-22, 1962.
13. Lejeune, J.; Turpin, R., and Decourt, J.: Aberrations chromosomiques et maladies humaines: syndrome de Klinefelter XXY à 46 chromosomes par fusion centromérique T-T. *Compt. rend. Acad. Sc.* **250**: 2468-2470, 1960.
14. Walker, S., and Harris, R.: Familial transmission of translocation between two chromosomes of 13-15 group (Denver classification). *Ann. Human Genet.* **26**: 151-162, 1962.
15. Walker, S., and Harris, R.: Investigation of family showing transmission of 13-15 chromosomal translocation (Denver classification). *Brit. M. J.* **2**: 25-26, 1962.
16. Jagiello, G.: Familial 13-15 translocation abnormality (Denver classification) associated with one case of cerebral palsy. *New England J. Med.* **269**: 66-69, 1963.
17. Moorhead, P. S.; Nowell, P. C.; Mellman, W. J.; Battips, D. M., and Hungerford, D. A.: Chromosome preparations of leukocytes cultured from human peripheral blood. *Exper. Cell Res.* **20**: 613-616, 1960.
18. Mercer, R. D., and Darakjian, G.: Letter to editor. Apparent translocation between chromosome 2 and acrocentric in group 13-15. *Lancet* **2**: 784, 1962.
19. Bottura, C.; Ferrari, I., and Veiga, A. A.: Letter to editor. Chromosome abnormalities in Waldenström's macroglobulinaemia. *Lancet* **1**: 1170, 1961.
20. German, J. L.; Biro, C. E., and Bearn, A. G.: Letter to editor. Chromosomal abnormalities in Waldenström's macroglobulinaemia. *Lancet* **2**: 48, 1961.
21. Benirschke, K.; Brownhill, L., and Ebaugh, F. G.: Letter to editor. Chromosomal abnormalities in Waldenström's macroglobulinaemia. *Lancet* **1**: 594-595, 1962.
22. Patau, K.: Letter to editor. Chromosomal abnormalities in Waldenström's macroglobulinaemia. *Lancet* **2**: 600-601, 1961.
23. Baikie, A. G.; Court-Brown, W. M.; Jacobs, P. A., and Milne, J. S.: Chromosome studies in human leukaemia. *Lancet* **2**: 425-428, 1959.
24. Wahrman, J.; Schaap, T., and Robinson, E.: Manifold chromosome abnormalities in leukaemia. *Lancet* **1**: 1098-1100, 1962.
25. Harnden, D. G., and Armstrong, C. N.: Chromosomes of true hermaphrodite. *Brit. M. J.* **5162**: 1287-1288, 1959.
26. Fraccaro, M.; Ikkos, D.; Lindsten, J.; Luft, R., and Kaijser, K.: Letter to editor. New type of chromosomal abnormality in gonadal dysgenesis. *Lancet* **2**: 1144, 1960.
27. Blumel, J.; Ohnuki, Y., and Awa, A.: Chromosomal anomaly in two cases of cerebral palsy, brother and sister. *Nature* **189**: 154-155, 1961.
28. Shaw, M. W.: Letter to editor. Association of acrocentric chromosomes with centromere region of chromosome no 1. *Lancet* **1**: 1351-1352, 1961.
29. Edwards, J. H.: Letter to editor. Chromosomal association in man. *Lancet* **2**: 317-318, 1961.
30. Ferguson-Smith, M. A., and Handmaker, S. D.: Observations on satellited human chromosomes. *Lancet* **1**: 638-640, 1961.
31. Ohno, S.; Trujillo, J. M.; Kaplan, W. D., and Kinoshita, R.: Nucleolus-organisers in causation of chromosomal anomalies in man. *Lancet* **2**: 123-126, 1961.