

MALABSORPTION SYNDROME AND PERIPHERAL NEUROPATHY

Report of Two Cases

RICHARD G. FARMER, M.D.,

Department of Gastroenterology

and

NELSON G. RICHARDS, M.D.

Department of Neurology

THE differential diagnosis of peripheral neuropathy (polyneuritis) can be a difficult and frustrating problem. No specific cause is found in most instances. Because the problem is a perplexing one, rather cumbersome classifications of peripheral neuropathy have evolved, and thus the clinician may tend to give little attention to isolated diseased states associated with neuropathy.

Several chronic diseases are known to be associated with peripheral neuropathy, including chronic alcoholism, malnutrition, hypovitaminosis (particularly vitamin B-complex deficiencies), diabetes mellitus, amyloidosis, and carcinoma. Malabsorption syndromes (nontropical sprue, gluten-induced enteropathy) are generally mentioned in classifications but are not considered prominently. It is well known that megaloblastic anemia due to vitamin B₁₂ deficiency can result in subacute combined degeneration of the spinal cord and neuropathy. The most common known cause of degeneration of the posterior and/or lateral column of the spinal cord is found in association with pernicious anemia. This neurologic picture may be present along with other disorders, for example nontropical sprue, a malabsorption state. Furthermore, the malabsorption syndrome may be associated with the neurologic picture of a peripheral neuropathy rather than posterior or lateral column involvement.

We have recently seen two patients with malabsorption syndrome and peripheral neuropathy. Because of the relative rarity, the prominent neurologic findings, and the importance of early diagnosis, we are reporting these two cases.

Report of Cases

Case 1. A 53-year-old man was examined at the Cleveland Clinic in August, 1963, because of progressive numbness and tingling of his hands and feet, present for 18 months. In addition, he had generalized weakness and staggering gait, also progressively disabling over a one-year period. He had noted sporadic watery diarrhea during the year but had no rectal bleeding. There had been no significant abdominal pain, but he had occasional nausea without vomiting. He had lost 20 pounds in weight in one month.

The patient gave a history of occasional diarrhea over a 10-year period. In 1956, he was examined at the Cleveland Clinic and a diagnosis of regional enteritis was considered. However, he declined hospitalization and therefore further studies were not carried out. In 1958, at another hospital, abdominal laparotomy was performed with an enteroenterostomy and bypass of a portion of ileum for a presumed diagnosis of regional enteritis. Postoperatively the patient continued to have occasional diarrhea but was not incapacitated until his present illness.

Physical examination revealed a chronically ill-appearing man who seemed much older than

his stated age. He was 5 feet 5¼ inches tall and weighed 97 pounds. Moderate clubbing of the digits was present. The tongue was smooth. Cheilosis was present. Abdominal examination revealed no abnormal findings; no masses were palpated, and the abdomen was not distended. There was moderate wasting of the musculature of the extremities with an absence of deep tendon reflexes. Further, there was symmetric loss of pin, cotton, vibration, and joint positional sensation in the distal part of the legs, with a lingering, painful, burning "echo" sensation upon stroking the soles of the feet with a blunt object, as well as a lingering sensation after removal of the pin. There were no extensor plantar reflexes. Chvostek's sign was present.

Laboratory studies indicated that diffuse intestinal malabsorption was present. The blood hemoglobin determination, leukocyte count, and reticulocyte count were normal. Determinations of fasting blood sugar content, blood urea content, and serum concentrations of sodium, potassium, chloride, and carbon dioxide were normal. Other serum concentrations were: calcium, from 5 to 8.3 mg. per 100 ml.; phosphorus, from 2.2 to 2.9 mg. per 100 ml.; magnesium, 1.3 mg. per 100 ml.; albumin, decreased to 2.38 gm. per 100 ml.; and carotene, less than 10 µg. per 100 ml. (normal: 50 to 250 µg. per 100 ml.). D-xylose excretion in a urine specimen was 1.5 gm. five hours after ingestion of a 25-gm. dose (normal: 4 gm. or more).

Hematologic investigation revealed deficiency of factors II (prothrombin), VII, IX, and X (plasma thromboplastin component). Prothrombin time was 30 seconds (control time 13 sec.), or 18 percent activity. Assays showed less than 5 percent activity each for factor IX and factor II. The peripheral blood smear showed evidence of poikilocytosis, with occasional target cells, spherocytes, and macrocytes. The bone marrow was normocytic. A platelet count and cell structure were normal. There was no evidence of fibrinolysis. A Schilling test showed less than 3 percent of vitamin B₁₂ excreted in the urine without intrinsic factor, and after the patient received intrinsic factor, less than 1 percent. A lumbar puncture was not performed.

Roentgenograms of the small intestine were consistent with a diagnosis of the malabsorption syndrome. There was evidence of segmentation of the barium, and dilatation of the small bowel (Fig. 1). Biopsy of the small bowel, by means of peroral intestinal biopsy capsule, was typical of nontropical sprue (Fig. 2).

The patient was hospitalized and the following program was instituted: a gluten-free diet; multivitamins orally,* one capsule, twice daily; vitamin D, † 50,000 units daily; calcium lactate, two drams, three times daily; vitamin B₁₂, 1,000 µg. parenterally, three times a week; and diphenoxylate hydrochloride with atropine, ‡ 2.5 mg., three or four times daily as needed to control the diarrhea.

At the time of discharge from the hospital, the patient had less pain and had increased in strength in the extremities. He was examined again in November and December, 1963, and in April, 1964, and had continued to improve. He has gained 27 pounds and has had only rare episodes of diarrhea. However, some numbness and tingling of the distal part of the extremities persisted. His gait as well as his ability to perceive pin, cotton, vibration, and joint position has progressively improved. The spontaneous as well as induced painful sensations in his feet were "mild" as compared to their severity before treatment. Improvement occurred in results of all laboratory tests except for the value of serum carotene (consistently in the range of 10 to 15 µg. per 100 ml.), and the d-xylose excretion in the urine (1.5 to 1.8 gm. in 5 hours after a 25-gm. dose).

Case 2. A 39-year-old woman was examined at the Cleveland Clinic in March, 1963, because of numbness and painful tingling of the hands and feet since approximately January, 1962. These symptoms began insidiously and involved the hands and fingers first; later the lower portions of the legs and the feet became affected. Weakness and weight loss were not prominent. In 1957, after having had intermittent diarrhea, occasional abdominal cramping, and considerable weight loss, the patient underwent abdominal operation at another hospital, and about a five-foot portion of small bowel was removed for a presumed diagnosis of regional enteritis. Postoperatively the patient was quite well and had little difficulty either with diarrhea or with abdominal pain. There was no diarrhea at the time of development of the painful paresthesias of the extremities, and otherwise she had been feeling well. At no time was there rectal bleeding.

On physical examination the patient was 5 feet tall and weighed 114 pounds; there were no abnormal findings. The neurologic examination revealed generalized weakness of the distal part of the extremities, with unsteadiness of gait and difficulty with heel-to-toe walking. Romberg's sign was present. Deep tendon reflexes were present and active except for the ankle jerks, which were absent. Vibratory sensation was symmetrically decreased in the distal part of the extrem-

**Sur-Bex with C, Abbott Laboratories.*

†*Drisdol, Winthrop Laboratories.*

‡*Lomotil, G. D. Searle & Co.*

ities; position sense of the toes of both feet was decreased. Responses to light touch and pinprick were decreased over the entire distal portion of both the extremities beyond the midforearm and mid thigh. A painful echo sensation occurred upon stroking the soles of the feet or after the pinpoint was removed.

Laboratory studies indicated diffuse malabsorption from the small intestine. Blood hemoglobin determination was 11.1 gm. per 100 ml.; and a leukocyte count, the fasting blood sugar

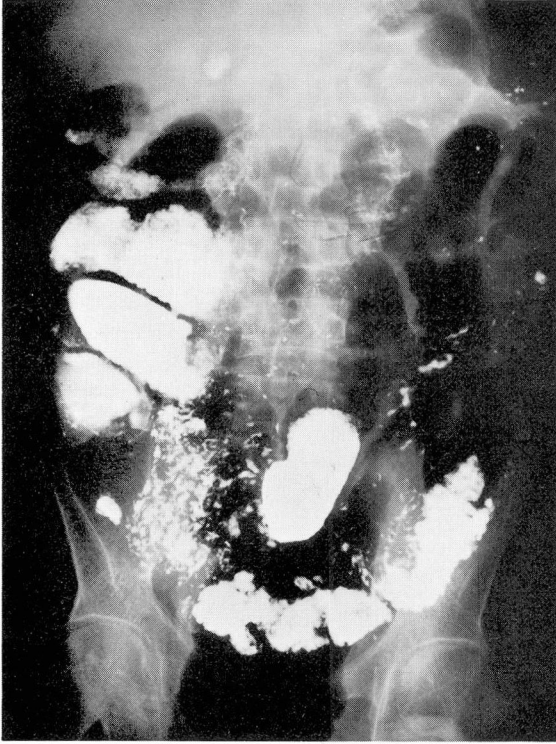


Fig. 1. Case 1. Roentgenogram of the small bowel, showing dilatation of the bowel, and flocculation and segmentation of the barium mixture.

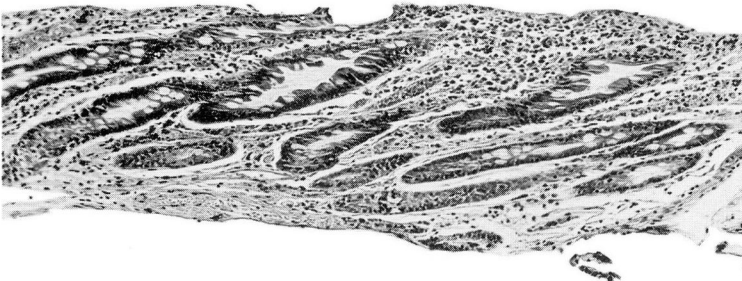


Fig. 2. Case 1. Photomicrograph of a section of small-bowel tissue, showing villous atrophy compatible with nontropical sprue. Hematoxylin-eosin-methylene blue stains; magnification X100.

content, the prothrombin time, and the serum protein values were normal. D-xylose excretion in the urine was 1.9 gm. five hours after a 25-gm. dose. The glucose tolerance curve was flat, with determinations of 66, 68, 62, and 74 mg. per 100 ml. of blood after fasting, and after one, two, and three hours, respectively, after glucose ingestion. The Schilling test, using vitamin B₁₂ plus intrinsic factor, revealed only 0.6 percent urinary excretion of vitamin B₁₂ in 24 hours. A roentgenogram of the small intestine showed evidence of hypermotility and dilatation, but not of a gross lesion or an obstruction.

The patient was started on a regimen including multivitamins, vitamin B₁₂ parenterally administered, and nicotinic acid. She returned for examinations in May and in August, 1963, and was symptomatically improved. There was no diarrhea, and the paresthesias had decreased. A d-xylose tolerance test showed an increase to 2.3 gm. excreted in the urine in five hours. In February, 1964, the most recent date the patient was examined, she had only mild numbness and tingling of the feet and none in the hands. Vibratory sensation and pinprick sensation were still decreased but were improved, and results of other neurologic examinations were normal. Lingering echo sensations were no longer present.

Discussion

For many years it has been recognized that peripheral neuropathy may occur as a complication of nutritional deficiency resulting from small-bowel malabsorption. However, the neurologic symptoms have been regarded as a relatively late manifestation, and observed at a time when the diagnosis of malabsorption syndrome offers no difficulty. In 1937, Woltman and Heck¹ reported that neurologic abnormalities were found in 11 of 29 patients studied who had nontropical sprue. They¹ described the typical clinical picture as consisting of acroparesthesias beginning gradually, distally, and symmetrically. These symptoms were associated with decreases in vibratory sensation, position sense, and deep tendon reflexes. Woltman and Heck¹ emphasized that abnormalities in the peripheral nerves, in the posterior column of the spinal cord, and in the lateral column of the spinal cord may occur singly or in combination; only one patient had the clinical findings of subacute combined degeneration of the spinal cord (posterolateral sclerosis). This latter syndrome has been reported frequently in association with deficiency of vitamin B₁₂, although there is a poor correlation with the severity of the neurologic changes.² Since degeneration of the posterior column usually occurs earlier than involvement of the lateral column, the initial manifestation may simulate peripheral neuropathy, with paresthesias, ataxia, and loss of position and vibratory sensation.

Prominent among listed causes of peripheral neuropathy are so-called metabolic causes: alcoholism, thiamine and other vitamin deficiencies, cachexia, nutritional deficiency, and malabsorption syndrome. Symptoms described in standard textbooks^{3,4} include distal symmetric paresthesias of the hands and feet, distal muscle weakness, loss of position and of vibratory sensation, and absence of deep tendon reflexes. These findings have been reported as occurring in nontropical sprue (idiopathic steatorrhea, gluten-induced enteropathy), and in other conditions causing malabsorption syndrome, such as after surgical resection or bypass of a portion of the small bowel. In a general discussion of neuromuscular disease in relation to nutrition, Cruickshank⁵ emphasized that damage could occur in the muscle cell, at the myoneural junction, and in neural tissue. He pointed out that the neurologic

defect may be specific, such as that related to vitamin B₁₂, or may simply occur along with nutritional deficiency. He stated that abnormalities could be found in the pyramidal tracts or posterior column of the spinal cord, or that selective lower motor neuron damage could be found at or distal to the posterior root ganglion.

Smith⁶ in 1955 reported three cases of peripheral neuropathy associated with idiopathic steatorrhea. The three patients each had a long history of diarrhea, and severe muscle weakness and ataxia subsequently developed, with a rapidly fatal outcome. He mentioned a total of 20 cases of neuropathy associated with idiopathic steatorrhea, and stated that either steatorrhea or neuropathy may be the earliest symptom. He described peripheral neuropathy, sensory ataxia, cerebellar ataxia, upper motor neuron lesions, and mental changes, occurring singly or in various combinations. Smith⁶ postulated deficiency of essential nutritional elements because of intestinal malabsorption and/or defective utilization, and compared the findings clinically and pathologically with neuropathy associated with carcinoma.

Our two cases are unusual in that in both patients the presenting symptoms were referable to neuropathy (*Table 1*) rather than to intestinal malabsorption.

Table 1.—*Neurologic findings in two patients with peripheral neuropathy and small-bowel malabsorption*

Neurologic symptoms or signs	Case	
	1	2
Paresthesias	Present	Present
Vibratory sense	Decreased	Decreased
Joint position sense	Decreased	Decreased
Pinprick sensation	Decreased	Decreased
Light-touch sensation	Decreased	Decreased
Acroparesthesia (echo phenomenon)	Present	Present
Deep tendon reflexes	Absent	Present
Muscle weakness (distal)	Present	Present
Wasting of muscle	Yes	No
Fasciculation of muscle	No	No
Ataxia	Present	Present
Extensor plantar reflex	Absent	Absent

Each patient had a history of diarrhea, abdominal laparotomy, and a presumed diagnosis of regional enteritis, but diarrhea and abdominal pain were not primary nor the significant symptoms at the time these patients were examined by us. One patient (case 1) was extremely underweight and incapacitated by his symptoms, while the other patient (case 2) was of normal weight and had only moderately

severe symptoms. With regard to their neurologic symptoms, both patients improved slowly after therapy was begun.

These two cases emphasize the great importance of searching the medical history in an attempt to find a cause of peripheral neuropathy that can be treated, in view of the progressive and possibly permanent nature of the neurologic defect. Any history of diarrhea, or other symptoms suggesting intestinal malabsorption, given by a patient with peripheral neuropathy, should be vigorously pursued so that appropriate therapy may be immediately instituted in an attempt to prevent irreparable neurologic damage.

Summary

Two patients with signs and symptoms of peripheral neuropathy were found to have small-bowel malabsorption. One patient had typical nontropical sprue, while the other had the malabsorption syndrome on the basis of regional enteritis and/or intestinal surgery. Presenting symptoms in both patients were primarily neurologic, with few gastrointestinal symptoms.

The importance of early recognition of such situations is emphasized, as they may represent a form of peripheral neuropathy that can be treated by measures such as a gluten-free diet and appropriate vitamin supplements. Early clinical awareness and vigorous diagnostic measures, including small-bowel biopsy, are vital to the prevention of permanent neurologic damage in patients who have gastrointestinal and neurologic symptoms.

References

1. Woltman, H. W., and Heck, F. J.: Funicular degeneration of spinal cord without pernicious anemia; neurologic aspects of sprue, nontropical sprue, and idiopathic steatorrhea. *Arch. Int. Med.* **60**: 272-300, 1937.
2. Victor, M., and Lear, A. A.: Subacute combined degeneration of spinal cord; current concepts of disease process. Value of serum vitamin B₁₂ determinations in clarifying some of common clinical problems. *Am. J. Med.* **20**: 896-911, 1956.
3. Kunkle, E. C.: Neuritis (Neuropathy), p. 1637, *in* Beeson, P. B., and McDermott, W., editors: *Cecil-Loeb Textbook of Medicine*. Philadelphia: W. B. Saunders Co., 1963, 1835 p.
4. Grinker, R. R.; Bucy, P. C., and Sahs, A. L.: *Neurology*, 5th ed. Springfield, Illinois: Charles C Thomas, 1960, 1386 p.; p. 265-270.
5. Cruickshank, E. K.: Neuromuscular disease in relation to nutrition. *Fed. Proc.* **20**: 345-352, 1961.
6. Smith, W. T.: Neuropathologic changes associated with idiopathic steatorrhea. (Abs.) Paper presented at Second International Congress of Neuropathology, London, Sept. 12-17, 1955. *Excerpta Medica, Neurology and Psychiatry (Section 8)* **8**: 860-861, 1955.