

# MESENTERIC ARTERITIS WITH PERFORATION OF THE JEJUNUM IN A PATIENT WITH SYSTEMIC LUPUS ERYTHEMATOSUS

## Report of a Case

CHARLES H. BROWN, M.D.,

*Department of Gastroenterology*

PATRICK J. SCANLON, M.D.,\* and JOHN R. HASERICK, M.D.

*Department of Dermatology*

**S**YSTEMIC lupus erythematosus (SLE) is frequently accompanied by gastrointestinal symptoms. Occasionally the first symptoms of lupus erythematosus (LE) comprise the clinical picture of acute abdominal pain which complicates the diagnosis. In gastrointestinal LE, the basic pathologic condition has been a peritonitis, pancreatitis, or arteritis involving various-sized mesenteric vessels, each of which disorder usually responds to steroid therapy.

Our report concerns a patient in whom, during an exacerbation of SLE, the clinical picture of an acute condition of the abdomen developed, and who was thought to have acute pancreatitis. Subsequently, mesenteric arteritis and perforation of a segment of the jejunum required surgical treatment. This case report is one of few published reports of arteritic perforation of the intestine in association with systemic lupus erythematosus.

## Report of a Case

A 38-year-old white man on August 9, 1961, was transferred to the Cleveland Clinic Hospital from a hospital in Maine, because of acute abdominal pain, and with a diagnosis of acute pancreatitis. Nearly 10 years previously, in October, 1951, a diagnosis of SLE was made, and at that time he had a history of migratory polyarthritis for 9 months, an intermittent low-grade fever, three bouts of deep thrombophlebitis of the left calf, a livid discoloration of the malar eminences after exposure to sunlight, a rash on the hands, and one bout of bilateral pleural effusion. He had had several positive LE tests at that time.

During the next nine years, he had many recurrences of LE symptoms, including Raynaud's phenomenon, diplopia and blurred vision, diarrhea, and psychiatric disturbances in addition to the above-named problems. The LE tests frequently were positive, and he had intermittent mild anemia, an increased erythrocyte sedimentation rate, albuminuria, and increased serum content of glycoproteins and globulin according to the electrophoretic method. Medications included adrenocorticotropin (ACTH), several forms of cortisone, propylthiouracil, Isoniazid,† and chloroquine phosphate.

During July, 1961, the month preceding his admission to the hospital, he had more or less constant epigastric pain that sometimes radiated to the midback, usually shortly after the intake of food. A series of upper gastrointestinal roentgenograms made on July 28, 1961, revealed a hiatus hernia. Antacids were prescribed at that time, but brought no relief from pain. Two days before admission to the hospital severe diffuse abdominal pain developed along with nausea and persistent vomiting. There was no hematemesis, diarrhea, bloody stools, or melena. He was examined at another hospital also, where "coffee-ground" material was aspirated from the stomach, and then he was transferred to the Cleveland Clinic Hospital.

The physical examination by us revealed a well-nourished white man in acute abdominal

\*Fellow in the Division of Medicine.

†Eli Lilly and Company.

distress. His skin was clear except for multiple subcutaneous nodules on the flexor surface of the left forearm. There were some coarse rales at the base of the right lung, and the right side of the diaphragm was questionably elevated. The heart tones were essentially normal. The abdomen was moderately distended; there was generalized muscle guarding and tenderness, and rebound tenderness was present in the left lower quadrant. Bowel sounds were absent. There were no palpable masses. The results of the remainder of the examination were essentially normal.

Laboratory studies revealed the following data: white blood cell count, 31,200 per cubic millimeter, with 68 percent segmented neutrophils, 20 percent nonsegmented neutrophils, 9 percent lymphocytes, and 3 percent monocytes. Serum amylase content and peritoneal fluid amylase content each was more than 600 units (Meyer-Killiam). Subsequent serum amylase determinations were: 764, 377, 691, 470, 606, and 515 units. Blood sugar, blood urea, and serum electrolyte values were normal. The urine was negative for porphyrins and porphobilinogen. Other laboratory data are presented in *Table 1*.

A roentgenogram of the genitourinary tract disclosed evidence of a nonspecific abdominal gas pattern, and a solitary edematous loop of jejunum or proximal ileum in the left upper quadrant of the abdomen, which did not appear to be due to mechanical obstruction. The presumed diagnosis was pancreatitis, while the differential diagnoses at that time included perforated peptic ulcer and mesenteric infarctions, all secondary to SLE or to therapy.

The patient was treated conservatively with steroids orally administered, nasogastric suction, intravenous injection of fluids, and narcotics. During the next week his general condition improved considerably, though he still had moderate, generalized, abdominal tenderness and muscle guarding. Another roentgenogram of the genitourinary tract on July 15, 1961, was quite similar to the earlier film, and he was started on routine ulcer management for possible pancreatitis. With the institution of ulcer therapy his condition slowly improved. He ate fairly well, had only occasional nausea, and stools were essentially normal. During this time a low-grade fever persisted. The abdominal pain and tenderness lessened considerably, and the bowel sounds were normal.

On July 22, 1961, a series of roentgenograms of the upper gastrointestinal tract revealed that the esophagus, stomach, and duodenum were normal. Two days later, roentgenograms of the lower gastrointestinal tract showed evidence of a normal colon, and "... a loop of dilated fixed small intestine showing an abnormal mucosal pattern of an inflammatory character" (*Fig. 1*). Subsequent roentgenograms on September 5, 1961, again showed evidence of the dilated segment of jejunum, with retained barium.

In view of the apparent pancreatitis, and the patient's improvement with medical treatment, it was decided at that time to postpone any surgery in regard to the dilated loop of jejunum. The patient was discharged from the hospital on September 9, 1961, with the advice to continue with the routine ulcer regimen and ACTH, 10 units per day.

He progressed well until October 5, when abdominal pain recurred. The pain was cramping in nature, migrated about the abdomen, and was accompanied by loud bowel sounds; there was some abdominal distention. The pain seemed to be triggered by eating, occurring about one hour after meals; it would last for two or three minutes, abate, then, in another few minutes would recur elsewhere, sometimes lasting for five or six hours. Narcotics were necessary to control the pain. On October 8, 1961, he was readmitted to the hospital.

The physical findings were similar to those at the time of his prior admission to the hospital, though the abdominal distress appeared to be less severe. The abdomen was distended, somewhat tympanic, but without evidence of ascites. There was moderate generalized tenderness, especially in the left lower abdominal quadrant and epigastrium, with moderate rebound tenderness in those areas. Bowel sounds were essentially normal. Results of laboratory studies were: white blood cell count, 9,000 per cubic millimeter with a normal differential count; serum amylase content, 455 units. Pancreatic studies after the injection of secretin showed a normal volume and bicarbonate content of the pancreas. A roentgenogram of the genitourinary tract showed evidence of a large segment of gas-distended small bowel in the left upper abdominal quadrant. (*Fig. 2 and 3*.)

The pain (mainly in the epigastric region) persisted during the next 12 days, being aggravated by eating, and partially relieved by vomiting. The patient was afraid to eat, and began to lose weight. A series of roentgenograms of the small bowel on October 10, 1961, and a roentgenogram of the genitourinary tract four days later both showed evidence of a dilated loop of jejunum, which seemed to be somewhat more dilated than previously. Surgical treatment was advised.

On October 21, 1961, laparotomy\* was performed through a short vertical left paramedian incision overlying the point of maximum tenderness. A loop of jejunum had undergone complete necrosis and was surrounded by other loops of small bowel densely adherent in an inflam-

\*Operation was performed by Dr. Rupert B. Turnbull, Jr., of the Department of General Surgery.

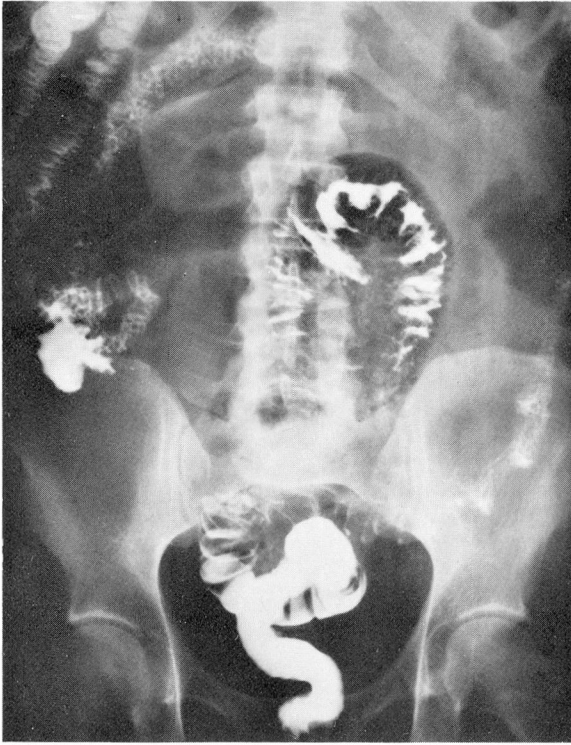

Fig. 1. Roentgenogram made on July 24, 1961, showing evidence of dilated loop of small intestine, with some retention of barium in the stomach from barium swallowed two days previously.

matory type of adhesion. The continuity of the bowel apparently had been maintained by the adherent loops of bowel and the anterior abdominal wall. The entire section was freed, the area debrided, and about 25 cm. of jejunum was resected. Pathologic examination revealed arteritis and infarction in the wall of the partially obstructed jejunum, and a sealed-off area of perforation (Fig. 4 and 5). The patient had an uneventful recovery, and he was discharged from the hospital on the tenth postoperative day.

His progress was fair, with the aid of steroids and, intermittently, the ulcer regimen. In September, 1963, he was readmitted to the hospital for abdominal pain similar to that of two years previously. Roentgenograms revealed evidence of normal esophagus, stomach, and duodenum, except for a small sliding hiatus hernia. Results of motility studies of the small intestine were normal. Conservative management resulted in a quick recovery, and since then he has been more or less asymptomatic.

### Discussion

Perforation of the bowel as a direct complication of SLE is indeed a rare complication.<sup>1-3</sup> Finkbiner and Decker<sup>4</sup> reported the case of a young girl with probable SLE (though LE tests were consistently negative) in whom diffuse gastrointestinal ulcerations and multiple perforation of the jejunum developed, with submucosal arteriolonecrosis that subsequently was proved to be present. Berg, Postel, and

**Table 1.**—Laboratory data of patient with mesenteric arteritis associated with SLE

Determination	Date of examination	
	1961	
	8-9	8-16
<b>Blood:</b>		
Hemoglobin, gm./100 ml.	16.4	13.0
Cell volume, %	45	40
Leukocytes/cu. mm.	31,200	8,300
Segmented cells, %	68	80
Nonsegmented cells, %	20	6
Eosinophils, %	—	3
Basophils, %	—	—
Lymphocytes, %	9	5
Monocytes, %	3	6
Sugar content, mg./100 ml.	—	62
Urea content, mg./100 ml.	40	26
Erythrocyte sedimentation rate, ml./min.	—	1.35
<b>Urine:</b>		
Specific gravity	1.005	—
Albumin	1+	—
Sugar	None	—
Red blood cells, no.	2-4	—
Pus cells, no.	Occasional	—
Casts, no.	Occasional	—
<b>Serum:</b>		
Amylase, units	764	691
Chloride, mEq./l.	97	104
Potassium, mEq./l.	4.7	4.2
Sodium, mEq./l.	136	145
LE test	—	Negative
Protein electrophoresis		
Albumin	—	1.99
α <sub>1</sub> -globulin, gm./100 ml.	—	0.40
α <sub>2</sub> -globulin, gm./100 ml.	—	0.77
β-globulin, gm./100 ml.	—	0.67
γ-globulin, gm./100 ml.	—	0.77
Plasma CO <sub>2</sub> , mEq./l.	27.3	31.2

Table 1.—(concluded)

Date of examination					
1961		1962		1963	
8-18	10-9	4-6	11-14	Sept.	Dec.
12.9	14.4	16.6	18.4	17.6	16.4
37	43	—	—	50	51
9,300	9,000	10,000	8,500	6,500	8,900
77	60	63	80	61	—
7	4	6	4	—	—
1	1	2	1	1	—
—	—	—	—	—	—
11	32	23	8	35	—
4	3	6	7	3	—
85	—	—	—	—	—
—	30	—	—	—	—
—	1.05	—	1.2	0.3	—
—	1.028	—	—	1.018	—
—	None	—	—	1+	—
—	None	—	—	None	—
—	Occasional	—	—	Occasional	—
—	2-3	—	—	2-4	—
—	0	—	—	—	—
470	455	—	—	311	358
—	100	—	—	97	—
—	4.2	—	—	4.8	—
—	140	—	—	142	—
—	Negative	Questionable	Questionable	—	Negative
2.15	4.60	—	—	4.65	—
0.46	0.38	—	—	0.20	—
0.85	0.56	—	—	0.49	—
1.03	0.60	—	—	0.70	—
1.41	1.86	—	—	1.21	—
—	29.1	—	—	28	—



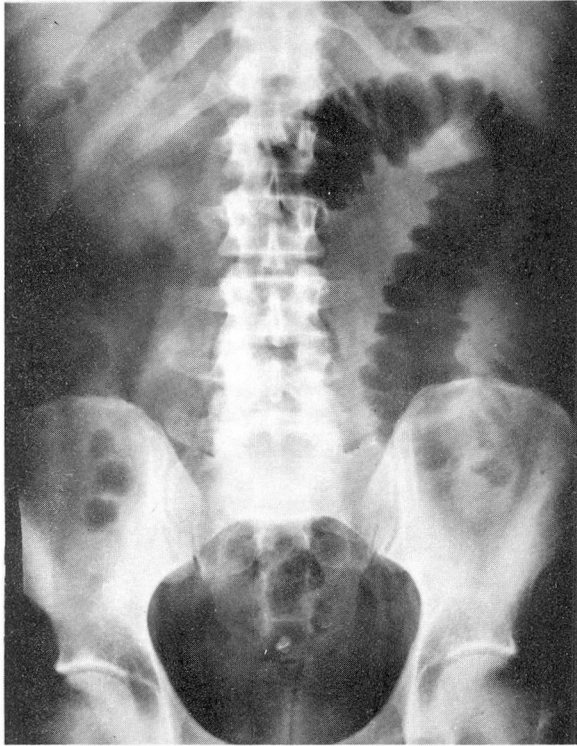


Fig. 2. Roentgenogram of the abdomen made on October 9, 1961, showing evidence of dilated loop of small intestine.

Lee<sup>5</sup> reported two cases in which there was perforation of the ileum, but biopsy showed no arteritis in one patient and no biopsy was done on the other. Perforation of steroid-induced ulcerations have been reported many times as occurring in this disease and in many others. However, the present case is one of few cases, if not the first case of SLE substantiated by a positive LE test, in which arteritic intestinal perforation proved to be a complication.

Gastrointestinal symptoms are common in SLE, reported as occurring in from 15 to 76 percent of collected cases.<sup>1-3, 6-10</sup> Occasionally, such symptoms characterize the onset of LE; Dubois<sup>6</sup> reported this correlation as having occurred in 9.6 percent of his patients, the chief complaints being nausea, vomiting, and variable abdominal pains. On rare occasions, the SLE gastrointestinal complex can mimic an acute condition of the abdomen. Pollak and associates<sup>7</sup> reported 14 cases in which there was simulation of an acute condition of the abdomen, in four of the patients the presenting symptoms simulated pancreatitis, and in 10 they simulated peritonitis in LE. Brown and associates<sup>8, 9</sup> reported two cases in which there was LE associated with chronic ulcerative colitis, and have seen four more since then.

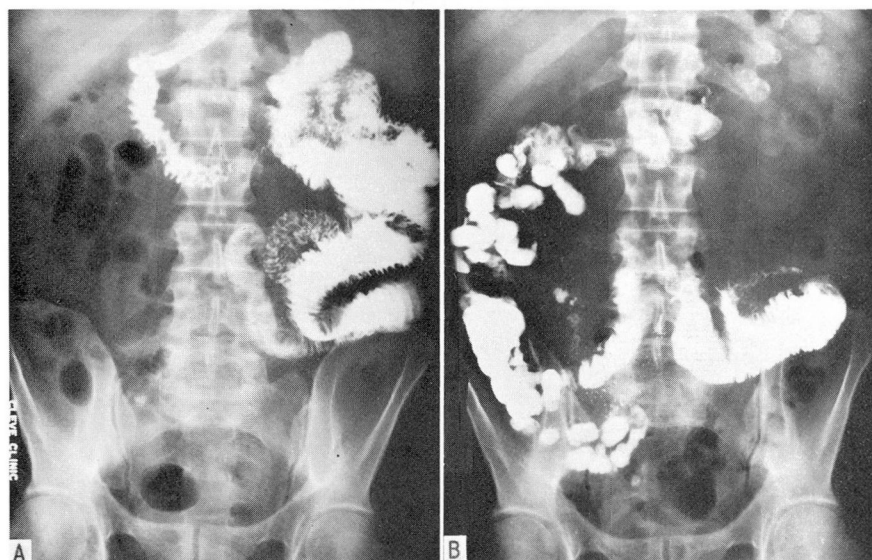


Fig. 3. A, Roentgenogram made on October 9, 1961, of the small intestine after barium was swallowed. Evidence of a dilated loop of jejunum with multiple serrations suggesting ulcerations can be seen. B, Later the same day, the roentgenogram of the small intestine again shows evidence of the dilated jejunum and also a narrowed segment.

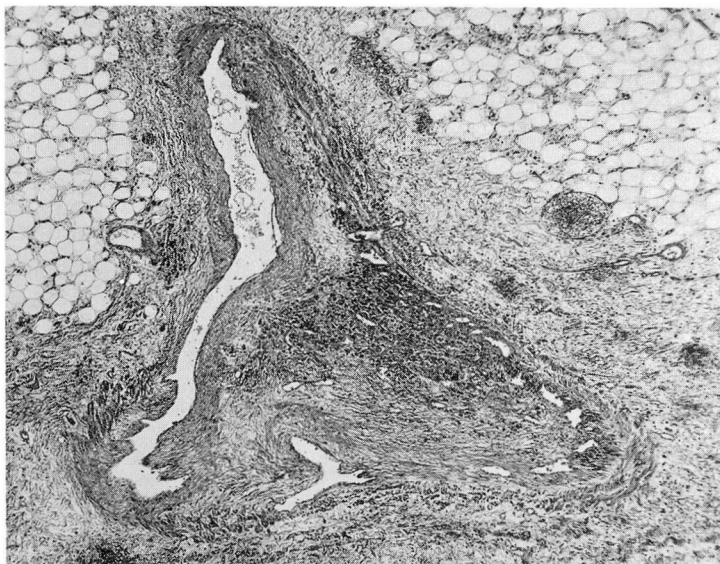
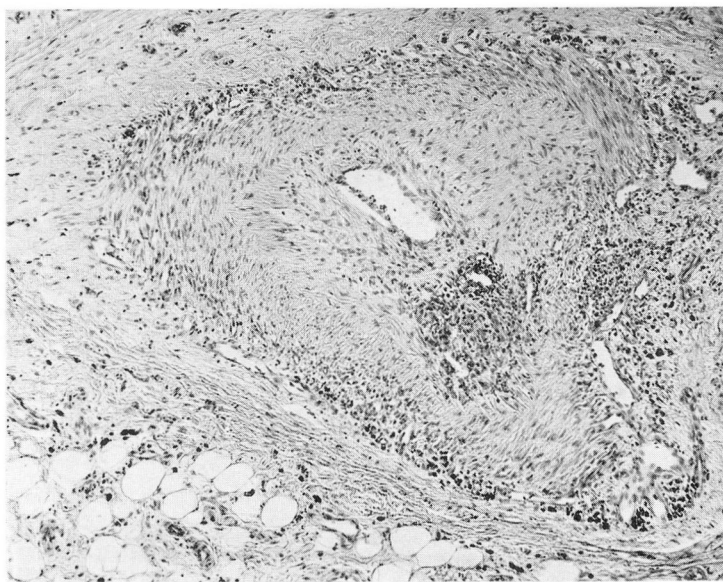


Fig. 4. Section shows a medium-sized artery at its bifurcation in the mesentery of the small bowel. The lumen of one limb is largely occluded by an old organized thrombus that shows marginal recanalization. There is also a rather heavy inflammatory infiltrate in part of the occluding tissue; this largely is formed by lymphocytes, plasma cells, histiocytes containing hemosiderin, and a few neutrophils. Hematoxylin-eosin-methylene blue stains; magnification X35.





**Fig. 5.** A higher power view of the same section shown in *Figure 4*, of a medium-sized vessel showing narrowing of the lumen with subintimal fibrosis. About the adventitia of the vessel there is a rather heavy inflammatory infiltrate of lymphocytes, plasma cells, and occasional neutrophils, and there is a rather large focus of a similar inflammatory infiltrate within the muscularis of the vessel. Small amounts of hemosiderin were present within the inflammatory infiltrate. Hematoxylin-eosin-methylene blue stains; magnification X80.

In cases of SLE, at surgery or at autopsy, the main pathologic features in the gastrointestinal tract have been peritonitis and intestinal arteritis. Harvey and associates<sup>1</sup> described three cases of ulcerations of the small intestine, and four cases of ulceration of the colon, all secondary to arteritis. McCombs and Patterson<sup>11</sup> reported one case found at laparotomy, in which there were early gangrenous changes of a short length of jejunum on the basis of vasculitis. Perforation of the intestine has been described as occurring in other conditions characterized by arteritis, including thromboangiitis obliterans, rheumatoid arthritis, malignant hypertension with necrotizing arteritis, and, especially, in association with periarteritis nodosa. Only one case of perforation secondary to arteritis in association with SLE has been previously described, the case reported by Finkbiner and Decker.<sup>4</sup> Brown, Shirey, and Haserick<sup>8</sup> reported one case of SLE associated with the symptoms and signs of an acute condition of the abdomen. A roentgenogram of the abdomen showed a loop of dilated jejunum; laparotomy revealed a segment of an edematous, engorged jejunum, dilated to twice the normal size, with a sharp line of demarcation between the normal and the dilated portions of the jejunum. No tissue was removed for pathologic study, but it seems probable that those changes also may have been caused by a mesenteric arteritis, not sufficiently severe to cause perforation or necrosis.



The treatment of gastrointestinal involvement in patients with SLE has comprised both parenteral and oral administration of steroids; usually remission occurs within 48 hours. However, such management, with postponement of early surgical intervention in cases of perforation, could easily result in death. A patient with SLE was in the hospital for nine days before a diagnosis of perforated ulcer was made by roentgen examination of the stomach, which showed a large fistulous tract extending to the right lower abdominal quadrant.<sup>8</sup> The usual signs of perforation and peritonitis had been absent. Unfortunately, as is well known in cases of perforation of steroid-produced ulcers, steroids frequently mask the signs of peritoneal irritation, making this diagnosis all the more difficult to make.

### Summary

A case of systemic lupus erythematosus complicated by perforation of the jejunum secondary to mesenteric arteritis is presented. This case is one of few reported cases of mesenteric arteritis, proved by pathologic examination, in association with SLE authenticated by positive LE tests. The clinical and pathologic gastrointestinal features of SLE are briefly discussed, and the difficulty of diagnosis and the necessity of proper treatment are emphasized.

### References

1. Harvey, A. M.; Shulman, L. E.; Tumulty, P. A.; Conley, C. L., and Schoenrich, E. H.: Systemic lupus erythematosus: review of literature and clinical analysis of 138 cases. *Medicine* 33: 291-437, 1954.
2. Jessar, R. A.; Lamont-Havers, R. W., and Ragan, C.: Natural history of lupus erythematosus disseminatus. *Ann. Int. Med.* 38: 717-731, 1953.
3. Copeland, G. D.; Von Cappeller, D., and Stern, T. N.: Systemic lupus erythematosus: clinical report of 47 cases with pathologic findings in 18. *Am. J. M. Sc.* 236: 318-329, 1958.
4. Finkbiner, R. B., and Decker, J. P.: Ulceration and perforation of intestine due to necrotizing arteriolitis. *New England J. Med.* 268: 14-18, 1963.
5. Berg, P.; Postel, A. H., and Lee, S. L.: Perforation of ileum in steroid-treated systemic lupus erythematosus; case report. *Am. J. Digest. Dis.* 5: 274-282, 1960.
6. Dubois, E. L.: Effect of LE cell test on clinical picture of systemic lupus erythematosus. *Ann. Int. Med.* 38: 1265-1294, 1953.
7. Pollak, V. E.; Grove, W. J.; Kark, R. M.; Muehrcke, R. C.; Pirani, C. L., and Steck, I. E.: Systemic lupus erythematosus simulating acute surgical condition of abdomen. *New England J. Med.* 259: 258-266, 1958.
8. Brown, C. H.; Shirey, E. K., and Haserick, J. R.: Gastrointestinal manifestations of systemic lupus erythematosus. *Gastroenterology* 31: 649-664, 1956.
9. Brown, C. H.; Haserick, J. R., and Shirey, E. K.: Chronic ulcerative colitis with systemic lupus erythematosus; report of case. *Cleveland Clin. Quart.* 23: 43-46, 1956.

10. Muehrcke, R. C.; Kark, R. M.; Pirani, C. L., and Pollak, V. E.: Lupus nephritis: clinical and pathologic study based on renal biopsies. *Medicine* **36**: 1-145, 1957.
11. McCombs, R. P., and Patterson, J. R.: Factors influencing course and prognosis of systemic lupus erythematosus. *New England J. Med.* **260**: 1195-1204, 1959.