

PANCREATIC SCANNING WITH SELENIUM⁷⁵*-METHIONINE, UTILIZING MORPHINE TO ENHANCE CONTRAST

A Preliminary Report

ANTONIO RODRIGUEZ-ANTÚNEZ, M.D.

Division of Radiology

RADIOGRAPHIC visualization of the pancreas has been a difficult problem. Until recently, with the exception of selective angiography,¹ only indirect means have been available. The injection of the amino acid *methionine* tagged with selenium⁷⁵ (Se⁷⁵) has made possible some direct visualization of the pancreas. Blau and associates,^{2,3} and Haynie and associates^{4,5} have reported the use of Se⁷⁵-methionine in the visualization of the pancreas on scintigrams.

Physiologically amino acids are the substratum for the pancreatic synthesis of the digestive enzymes. The amino acid methionine contains sulfur in its molecule, and selenium being similar to sulfur can replace it in the methionine molecule without changing the properties of the amino acid. This substitution of selenium for sulfur has made Se⁷⁵-methionine the preferred substance for pancreatic scanning.

Various procedures for preparation of the patient before scanning have been recommended in order to enhance the concentration of Se⁷⁵-methionine within the pancreas.³ It has been reported⁵ that about 6 percent of this amino acid is present in the pancreas within two hours after injection. A disadvantage to the use of this amino acid is the fact that the liver competes with the pancreas in absorbing the administered Se⁷⁵-methionine. Thus, pancreatic scanning has been difficult for two reasons: (1) chemically, the liver diverts some of the radioactive material from the pancreas; and (2) physically, the liver overlaps part of the pancreas and interferes with the visualization of the pancreas and subsequently the interpretation of the scintigram.

In trying to avoid the above-mentioned difficulties, we recently modified the usual sequence and technic for diagnostic pancreatic scanning. This preliminary report presents the results in a few patients (15), and a comparison of the scintigrams of the normal person with those of patients who have various pathologic entities that we have been able to detect. Confirmation of some of the diagnoses has been obtained at laparotomy.

Technic

Preceding the scanning, food and fluids by mouth are withheld from the patient from six o'clock in the evening until the following morning, when a fat-free breakfast is given. The patient is served fruit juice, chicken broth, jello, eggnog

*The radioactive material was obtained on authorization of the United States Atomic Energy Commission, Washington, D.C.

made with skim milk, tea, and three or four packets of sugar. Approximately one-half hour after the beginning of breakfast, from 3 to 3.5 μc . per kilogram of body weight of Se^{75} -methionine is slowly injected intravenously. At the same time, $\frac{1}{4}$ gr. of morphine is injected intramuscularly. We believe that the known effect of the morphine on the sphincter of Oddi helps to avoid the excretion of enzymes containing the isotope into the duodenum. About one-half hour after the injection of Se^{75} -methionine the scan is started. The patient is positioned, on the scanning table, slightly rotated to the right side.

Results*

Normal pancreas. Our criterion of a normal pancreas is that which shows an even distribution of radioactivity and the absence of distortion in the shape and outline of the pancreas on the scan. In our limited experience with this isotope the failure to visualize the pancreas is almost pathognomonic of pancreatic disease. *Figure 1* shows the image, as seen on the television screen, of a normal pancreatic

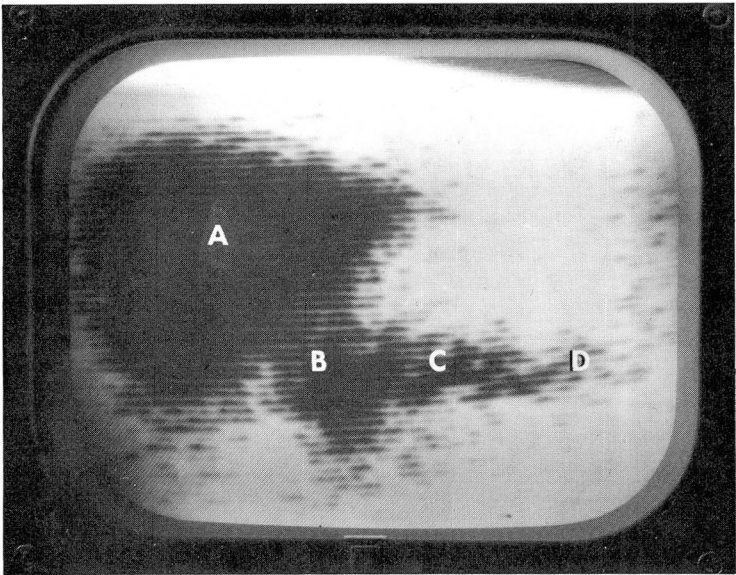


Fig. 1. The Se^{75} -methionine scan of a normal pancreas: A, right lobe of liver; B, head of pancreas; C, body of pancreas; D, tail of pancreas. The distribution of radioactivity is fairly even and there is no distortion of the contour or displacement of the gland. The clinical preoperative diagnosis was "possible pancreatitis"; at laparotomy the pancreas was found to be normal.

scintigram in which the anatomic shape and position of the gland are readily evident. The scan of the liver does not overlap that of the pancreas. The pancreatic tissue concentrates the Se^{75} -methionine well, in a fairly uniform distribution.

*Operations on the patients discussed were performed by Stanley O. Hoerr, M.D., or Robert E. Hermann, M.D., both of the Department of General Surgery.

Tumors of the pancreas. Pancreatic tumors have been identified in the scan by the following five distinctive signs: (1) Localized filling defects in an otherwise normally shaped gland (*Fig. 2*). (2) Displacement of pancreatic tissue outside the normal outline of the pancreas (*Fig. 2*). (3) Distortion and narrowing of any seg-

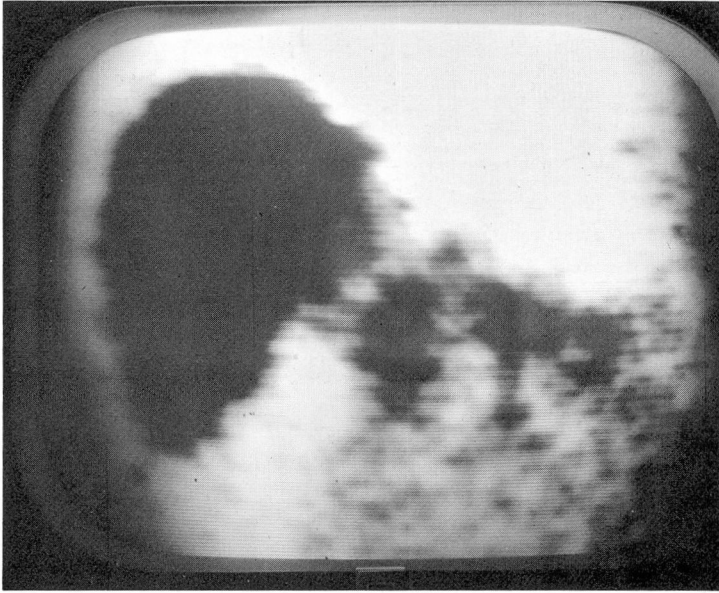

Fig. 2. This Se⁷⁵-methionine scan of the pancreas demonstrates a filling defect in the neck of the pancreas, and there is evidence of displacement of active pancreatic tissue easily recognizable outside the outline of the gland. At operation the patient was found to have carcinoma of the neck of the pancreas.

ment of the organ (*Fig. 3 and 4*). (4) Lack of visualization of the entire or part of the pancreas, because of invasion by tumor (*Fig. 5 and 6*); in the case of *Figure 5*, at operation the entire body of the pancreas was involved by tumor and only the head was partially free (incidentally, the patient was not jaundiced). (5) Presence of filling defects in the liver because of metastasis; *Figure 4* shows a rather extensive carcinoma of the pancreas with a large metastasis to the liver as demonstrated in the scan by a big filling defect in its center.

Summary

The technic of pancreatic scanning with selenium⁷⁵-methionine has been modified by giving the patients morphine at the same time as the radioactive material. Pancreatic scans have indicated carcinoma of the pancreas, and appear to be a useful diagnostic procedure in these difficult cases. Whether or not pancreatic scanning with this technic will be of diagnostic value for smaller tumors of the pancreas remains to be seen. Further studies with pancreatic scanning, includ-

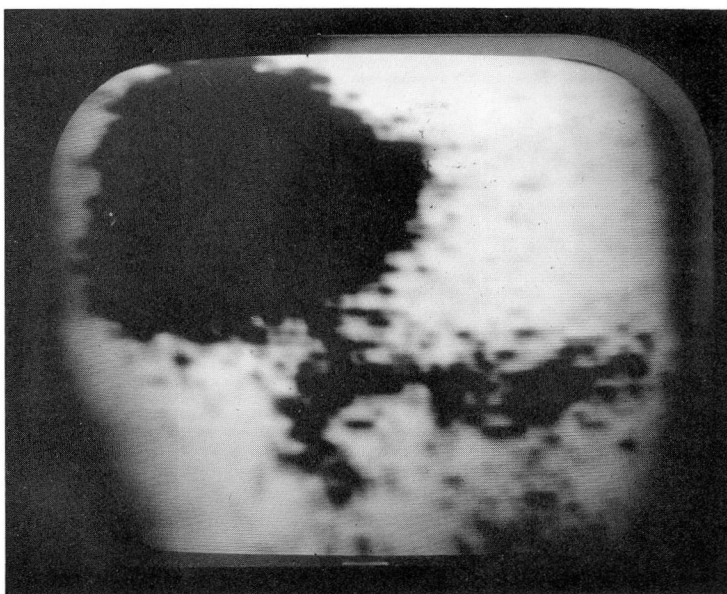


Fig. 3. This Se^{75} -methionine scan shows an obviously abnormal pancreas; however, the patient refused surgery, and the diagnosis therefore could not be confirmed or refuted.

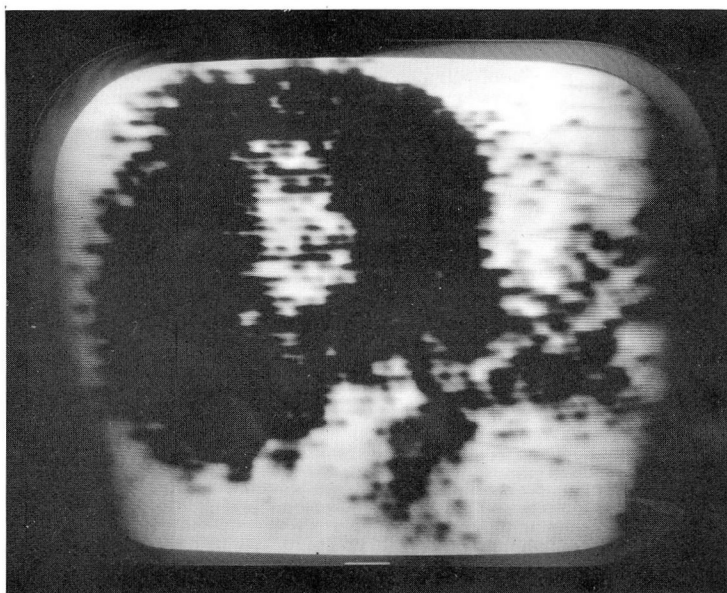


Fig. 4. This Se^{75} -methionine scan shows the pancreas of a patient who had a painless jaundice of one month's duration. Distortion of the contour of the gland and a big filling defect in the center of the liver are demonstrated. A diagnosis of pancreatic tumor with metastasis to the liver was made and was confirmed at laparotomy.

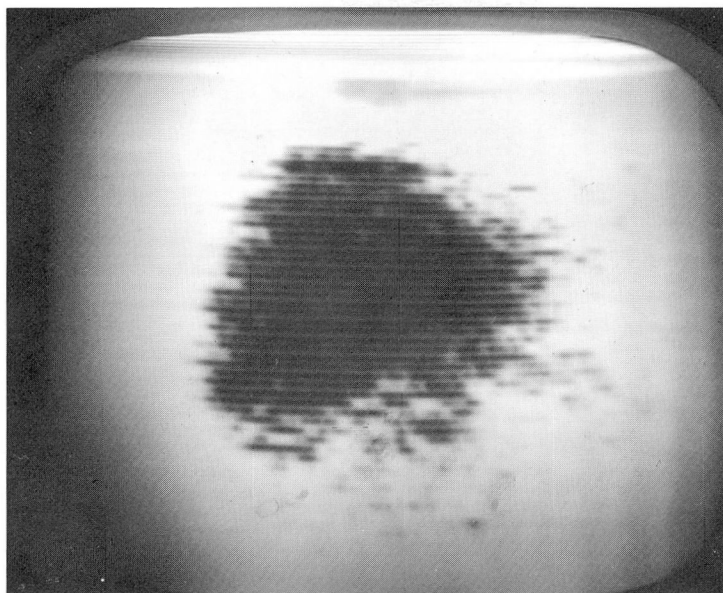


Fig. 5. This Se^{75} -methionine scan is of the pancreas of a man with a history of weight loss and abdominal pain but no jaundice; the body and tail of the pancreas are not visualized. At operation an extensive carcinoma of the pancreas was found. We believe that the lack of visualization of the pancreas is pathognomonic of a pathologic process involving the gland.

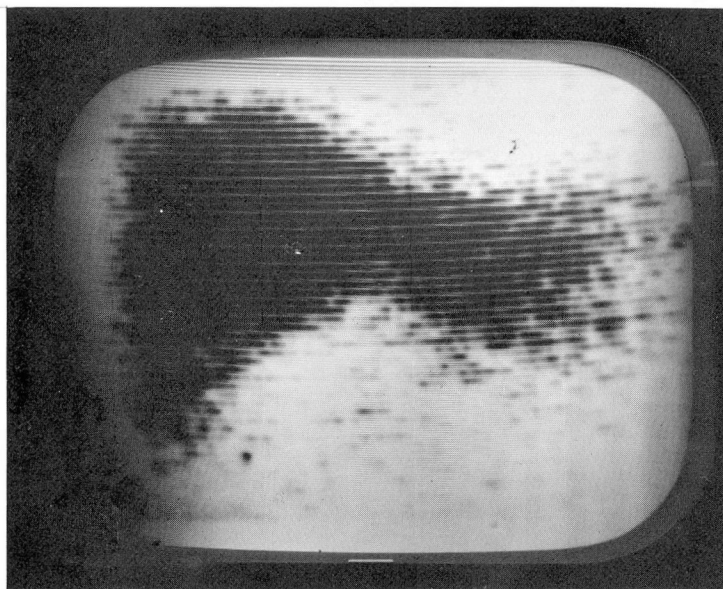


Fig. 6. This Se^{75} -methionine scan failed to demonstrate pancreatic tissue. At operation a massive tumor of the pancreas was found.

ing studies in patients with pancreatitis, benign cysts of the pancreas, and other lesions are indicated.

These preliminary observations are based on studies of a small number of patients; with additional experience it is hoped that definitive criteria may be established in regard to pancreatic scanning after injections of selenium⁷⁵-methionine and morphine.

Acknowledgment

The author gratefully acknowledges the assistance of Miss Janet L. King, R.N., Miss Helen M. Bliss, R.T.-I. (A.R.R.T), and Mr. Bernard B. Tautkins, in this study.

References

1. Meaney, T. F.; Winkelman, E. I.; Sullivan, B. H., Jr., and Brown, C. H.: Selective splanchnic arteriography in diagnosis of pancreatic tumors. *Cleveland Clin. Quart.* **30**: 193-197, 1963.
2. Blau, M., and Manske, R. F.: Pancreas specificity of Se⁷⁵-selenomethionine. *J. Nuclear Med.* **2**: 102-105, 1961.
3. Blau, M., and Bender, M. A.: Se⁷⁵-selenomethionine for visualization of pancreas by isotope scanning. *Radiology* **78**: 974, 1962.
4. Haynie, T. P.; Svoboda, A. C., and Zuidema, G. D.: Diagnosis of pancreatic carcinoma by photoscanning. (Abstract.) *Clin. Res.* **10**: 291, 1962.
5. Haynie, T. P.; Svoboda, A. C., and Zuidema, G. D.: Diagnosis of pancreatic disease by photoscanning. *J. Nuclear Med.* **5**: 90-94, 1964.