

EFFECTIVE SPONTANEOUS PORTACAVAL VENOUS SHUNT

Report of Two Cases

B. H. SULLIVAN, JR., M.D., CHARLES H. BROWN, M.D.,

Department of Gastroenterology

THOMAS F. MEANEY, M.D.,

Division of Radiology

and

EARL K. SHIREY, M.D.

Department of Pediatric Cardiology and Cardiac Laboratory

INCREASED resistance to blood flow in the liver or portal venous system results in portal venous hypertension and the development of collateral pathways bypassing the liver and shunting the blood into the systemic circulation. Reversal of direction of flow through the coronary and short gastric veins shunts blood by way of the esophageal and paraesophageal veins into the azygos and hemiazygos system and the superior vena cava. Esophageal and gastric varices so formed may be the source of fatal hemorrhage. Other channels of venous outflow include reversed flow in the inferior and superior mesenteric vessels with ultimate passage to the inferior vena cava.

In addition, new channels may appear through enlargement or recanalization of small veins, or the growth of new vessels in fibrous adhesions. These new channels may be numerous, and sometimes are of a caliber that approaches the surgically produced portasystemic venous shunts. However, they usually are of small caliber, tortuous, and almost never effective in reducing the portal blood pressure to normal levels. Rarely, spontaneous shunts of large diameter have developed between the splenic and left renal veins,^{1,2} yet have not brought the portal pressure within the normal range.

Our report concerns two cases in which a large venous channel developed and emptied into the inferior vena cava, mimicking a surgically produced end-to-side portacaval shunt, and in one case serving as a hemodynamically effective run-off channel preventing significant elevation of portal venous pressure.

Report of Cases

Case 1. A 56-year-old woman was first admitted to the Cleveland Clinic Hospital on May 2, 1963, for consideration for a portacaval venous shunt operation. She had been a heavy drinker for seven years, but she had abstained from alcohol since July, 1962. In March, 1962, after a fall, she was hospitalized because of jaundice, ascites, peripheral edema, and high blood pressure. These manifestations of disease subsided, and in two weeks she was discharged from the hospital. Jaundice and mental confusion in July, 1962, prompted readmission to the hospital. Massive hematemesis occurred, necessitating the use of the Sangstaken-Blakemore tube and numerous blood transfusions. Abdominal paracentesis was also performed. She left the hospital after one month and was fairly well except for weakness. There was episodic mental confusion

and disorientation early in 1963; melena was noted in March. A blood ammonia determination at that time was 250 $\mu\text{g.}$ per 100 ml.; she was referred to the Cleveland Clinic for further study.

Physical examination showed her to be obese, alert, and cooperative. She was not jaundiced; three small spider angiomas were on the chest. There was a small umbilical hernia; ascites was not present. The liver was palpable 10 cm. below the right costal margin in the midclavicular line; the spleen was not palpable.

Esophagoscopy and gastroscopy demonstrated no varices or other lesions. Radiographic findings of the upper gastrointestinal tract and of the chest were normal. Liver tests were normal except for 7 percent sulfobromophthalein retention 45 min. after administration of 5 mg. of dye per kilogram of body weight. The blood ammonia level was 80 $\mu\text{g.}$ per 100 ml. Liver biopsy showed mild portal cirrhosis.

On May 6, 1963, a splenoportogram was made (*Fig. 1*). The splenic pulp pressure was 20

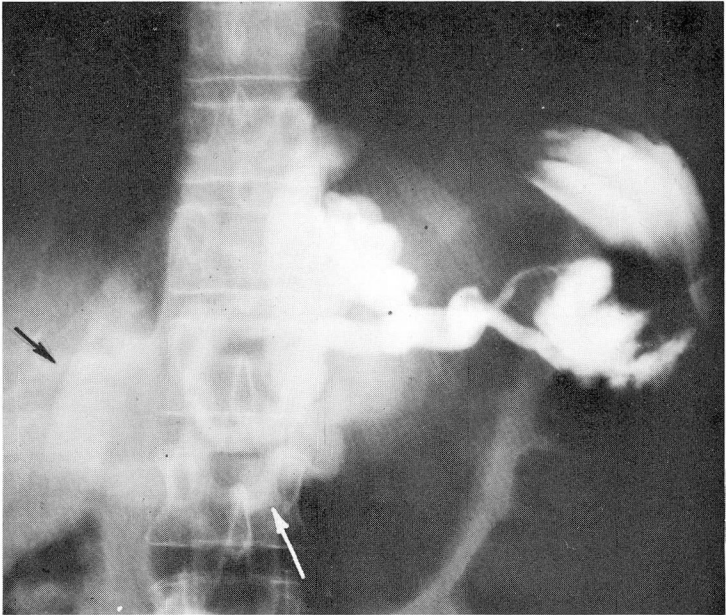


Fig. 1. Case 1. Splenoportogram demonstrates many collateral veins arising from splenic vein. Portal vein is not opacified. White arrow indicates spontaneous portacaval shunt. Black arrow points to opacified inferior vena cava.

mm. of Hg. The caliber of the splenic vein was normal; the gastric and coronary venous systems showed large collateral vessels, but no esophageal varices were evident. There was no perfusion of the portal vein, and the entrance of the superior mesenteric vein was not detected. A large collateral channel arose from the vicinity of the splenic vein and emptied into the inferior vena cava. The identity of the vena cava was confirmed by a venacavagram.

On May 10, 1963, venous catheterization and venograms were performed from the right median basilic vein. Mean pressure determinations with the catheter tip in the right atrium, free hepatic vein, and in the hepatic wedged position, were 6, 6, and 10 mm. of Hg, respectively. In the inferior vena cava above and below the renal veins, the mean pressure range was 12 to 13 mm. of Hg. Slightly above the left renal vein, the catheter was advanced into a large anomalous vessel with an intraluminal mean pressure of 18 mm. of Hg. Selective contrast visualization of this vessel utilizing high speed cineradiography demonstrated a rapid velocity of flow compared to that in a renal venogram studied in the same manner. The large orifices and lumen diameter of the main channel (*Fig. 2*), and the tapered proximal segment communicating with several small veins (*Fig. 3*), constitute the major physical characteristics of the unusual spontaneous venous shunt.

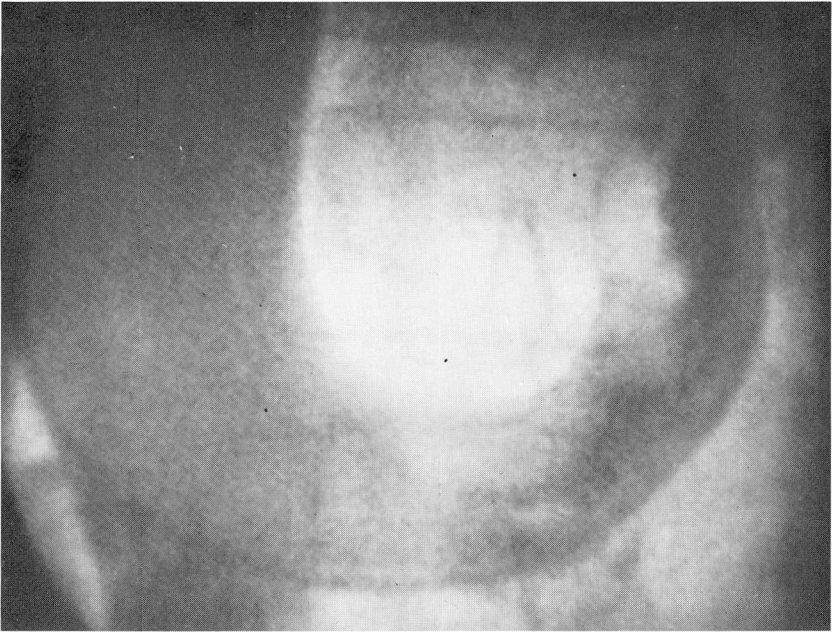


Fig. 2. Case 1. One year later the spontaneous shunt is still patent, and some contrast material is seen in the portal vein, indicating recanalization.

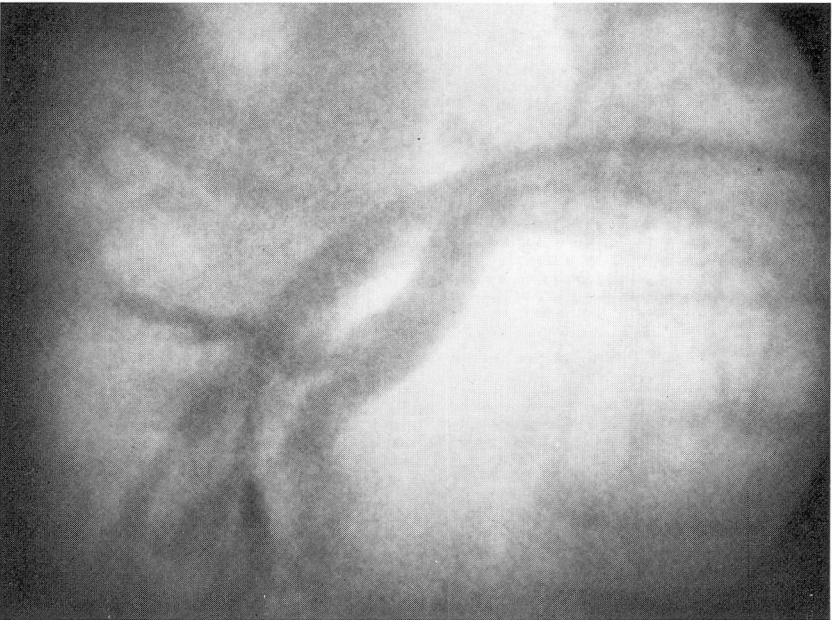

Fig. 3. Case 1. Venous catheter, passed via inferior vena cava (on the left in the photograph), has entered spontaneous shunt and demonstrates size of this vessel.

A portacaval shunt operation was considered unnecessary and the patient was discharged from the hospital.

She was examined again in April, 1964. There had been no further hemorrhage or manifestation of hepatic disease. Her weight had remained stable at 150 pounds. She had required an occasional diuretic for mild edema of the ankles. The margin of the liver was at the costal border and was somewhat tender; the spleen was not palpable.

There was no change in the roentgenographic findings. Results of esophagoscopy were again normal, as were those of the various laboratory tests. Splenoportography (Fig. 4) showed a splenic pulp pressure of 10 mm. of Hg. There were large gastric varices. The spontaneous shunt

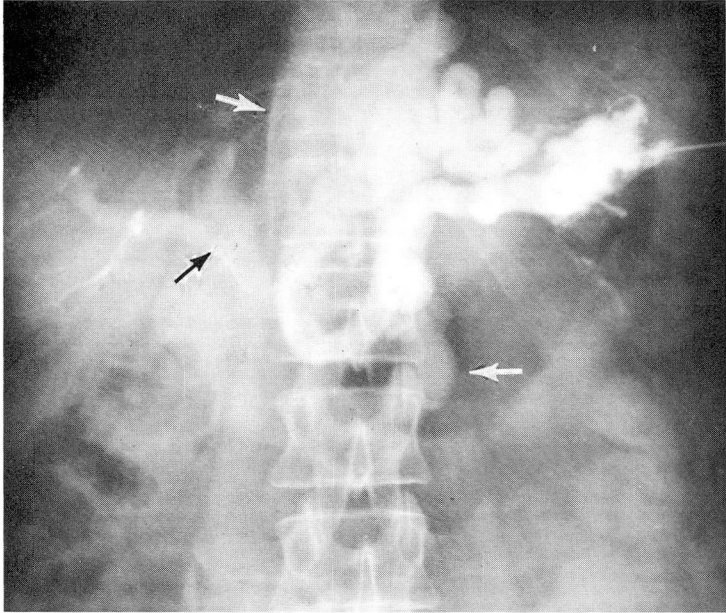


Fig. 4. Case 1. Venous catheter has been advanced to region of splenic hilum.

was still present, but, in addition, some contrast medium was seen to flow through the portal vein into the liver. A liver biopsy specimen was diagnosed as moderate postnecrotic cirrhosis, with some increase in the degree of portal lymphocytic infiltration over that in the previous biopsy specimen.

Comment. It is thought that the large fatty liver developed in relationship to alcohol ingestion and inadequate diet, and that sometime in July, 1962, portal vein thrombosis occurred. This was associated with hematemesis and hepatic encephalopathy. The development of a large spontaneous shunt between the portal system and the vena cava allowed decompression of the portal venous system. Subsequently the patient abstained from alcohol, and in time the fat was mobilized from the liver. At the same time, recanalization of the portal vein began. When she was first seen in May, 1963, the portal vein pressures, while elevated, were within the range one would expect after a successful portacaval shunt operation. It was therefore decided to postpone surgical intervention. The studies in April, 1964, showing a normal-sized liver and normal portal vein pressure indicated that operative intervention might not be necessary in this patient.

Case 2. A 75-year-old woman was admitted to the Cleveland Clinic Hospital on September 7, 1963, because of ascites. Splenomegaly, anemia, and abdominal enlargement had first been noted in July, 1959. In the interval, the spleen size had varied, but the blood hemoglobin content remained less than 10 gm. per 100 ml. She stated that she did not drink liquor, wine, or beer.

Physical examination revealed an elderly, wrinkled, cachectic woman without jaundice or spider angiomas. Ascites was present and no abdominal organs could be palpated. After the

removal of 4 l. of cloudy ascitic fluid by paracentesis, the liver could be felt 2 cm. below the costal margin; the edge was sharp and somewhat tender. The spleen extended 5 cm. below the left costal margin. Liver biopsies on three occasions yielded normal findings. With the evidence of portal hypertension (splenomegaly, ascites) a diagnosis of thrombosis of the hepatic vein³ was considered.

Hepatic vein catheterization on September 19, 1963, showed all venous channels to be patent, but they narrowed more abruptly than normal ones, and arborization was decreased. Injection of contrast medium into the inferior lateral hepatic vein was followed by rapid opacification of another large venous channel, possibly of the portal system. The pressures were: wedged hepatic vein, 10 mm.; free hepatic vein, 7.5 mm.; inferior vena cava, 7.5 mm.; and right atrium, 7.5 mm. of Hg.

Splenoportography did not demonstrate the portal vein (*Fig. 5*). There were numerous

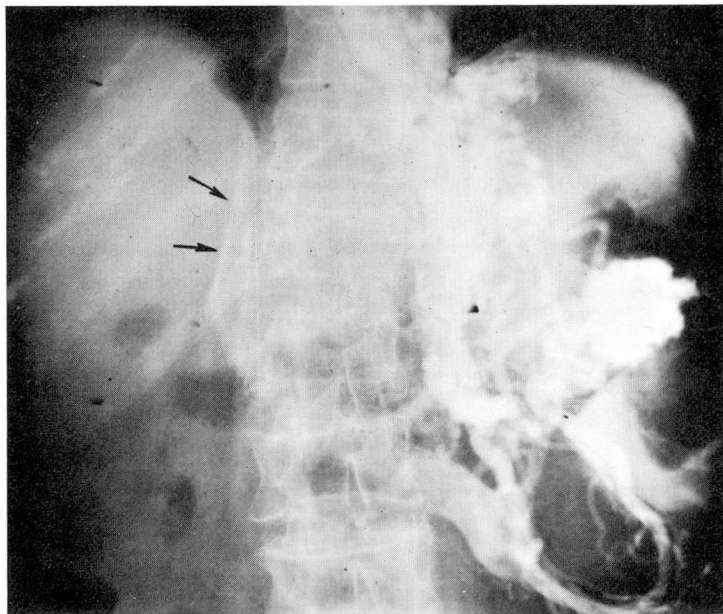


Fig. 5. Case 2. Splenoportogram demonstrates multiple collateral venous channels, including the spontaneous portacaval shunt. Arrows indicate opacified vena cava. The portal vein is not seen.

collateral venous channels in and about the spleen and azygos system. One of these channels communicated directly with the vena cava, which was opacified by the contrast medium for a short distance. Laparotomy* was performed immediately after splenoportography. At operation the liver and spleen each was about three times normal size. There was a large retroperitoneal mass in the left upper quadrant of the abdomen behind the stomach. Many enlarged lymph nodes were found along the lesser curvature of the stomach; microscopic examination of one of the lymph nodes showed the tumor to be reticulum-cell sarcoma. Construction of a portacaval shunt was thought to be inadvisable in view of the presence of neoplasm.

Postoperatively the patient received three 5-mg. intravenous injections of nitrogen mustard. The ascitic fluid had reaccumulated by October 3, and right pleural effusion developed two days later. Thoracentesis, abdominal paracentesis, and various supportive measures were used, but she died on October 5, 1963.

Comment. This 75-year-old patient had splenomegaly for four years. Sometime in the course of her illness occlusion of the portal vein occurred, probably because of pressure of the reticulum-

*Surgery was performed by Robert E. Hermann, M.D., of the Department of General Surgery.

cell sarcoma in lymph nodes about the vessel. It is likely that the spontaneous shunt provided sufficient decompression of the portal venous system to avoid serious complications until the final stage of her illness, when ascites developed.

Discussion

In every patient with portal hypertension, collateral pathways spontaneously develop (as evidenced by esophageal varices, the caput Medusae, dilated abdominal wall veins) shunting the venous return from the portal to the vena caval system. However, most of these spontaneous shunts are inefficient and ineffective in reducing portal hypertension.

These two cases demonstrate the diagnostic approach to the patient with portal hypertension. The site of the obstruction (hepatic vein, liver, or portal vein) must be shown by appropriate studies before a surgical portacaval shunt is undertaken. Such studies include splenoportography, determination of splenic pulp pressure, hepatic vein catheterization, determination of wedged hepatic vein pressure, and liver biopsy.

Portal hypertension is often classified by the site of the obstruction to blood flow: (1) presinusoidal, as in splenic and portal vein occlusion, Schistosomal liver disease,⁴ Wilson's disease, and certain other poorly defined entities;^{5,6} (2) intrasinusoidal, as in hepatic cirrhosis; and (3) postsinusoidal as in hepatic vein occlusion (Budd-Chiari syndrome). The proper classification of the individual case thus requires pressure measurements on each side of the liver by determinations of the intrasplenic pressure and the wedged hepatic vein pressure. If portal hypertension is present, the splenic pulp pressure will be elevated above the normal value of about 13 mm. of Hg. Presinusoidal obstruction is associated with normal wedged hepatic vein pressures, but with intrasinusoidal obstruction the wedged hepatic vein pressure is equivalent to the portal vein pressure; i.e., greatly increased. Hepatic vein (postsinusoidal) occlusion will also give normal values, about 10 mm. of Hg or less. In both of our patients the wedged hepatic vein pressure was within the normal range. The splenic pulp pressure was elevated in the one patient (case 1) when first determined, but normal one year later.

With the catheterization studies (case 1) the pressure in the collateral channel emptying into the vena cava was 18 mm. of Hg, which pressure compares well with the 20 mm. of Hg measured in the spleen at splenoportography. We believe that no previous similar determination has been reported. Not only does it substantiate our belief that the anomalous vessel represents a spontaneous portacaval venous shunt, it also reinforces our confidence in the identity of the portal vein pressure with the splenic pulp pressure.

As Brown and associates⁷ have pointed out, there must be certain skepticism in accepting the diagnosis of portal vein thrombosis on splenoportographic evidence alone. If there is a retrograde flow, or complete stasis of blood in the portal vein at the time of the study, no contrast medium will flow from the splenic vein into

the liver, and the diagnosis of portal vein occlusion will be erroneously assumed. In each of our two patients a large collateral vessel was present carrying a great volume of blood into the vena cava. It is evident that little or no blood flowed through the highly resistant portal vein pathway, and that most of the blood and all of the contrast material passed through the spontaneous portacaval shunt.

It is possible that the portal vein occlusion in case 2 was due to extrinsic pressure and not to thrombosis. The normal wedged hepatic vein pressure in case 1 is strong confirmatory evidence of presinusoidal obstruction and, together with the splenoportographic evidence, establishes the diagnosis of portal vein occlusion. Recanalization of this channel was associated with a reduction in portal venous pressure, as would be expected. Brown and co-workers⁷ reported splenoportographic demonstration of recanalization of the portal vein in three patients. Cavernous transformation of the portal vein, the most common cause of portal hypertension in infants, is thought to be the result of portal vein occlusion with subsequent recanalization and development of collateral channels.⁸

Although variations in portal venous pressure are common, and esophageal varices have been seen to diminish in size or even to disappear, experienced students of the disease have cautioned that the need for portal decompression remains.⁹ The collateral circulation is said to develop only in response to hypertension, and so cannot reduce the pressure to normal, nor be maintained should the pressure fall to normal. In our case 1 the improvement in the hepatic disease and associated reduction in the resistance to flow of portal vein blood was manifested by the fall in splenic pulp pressure and the opacification of the portal vein at splenoportography. It is too early to be sure that there will be no further progression of the hepatic disease and recurrence of portal hypertension. Should there be recurrence, the patient would enjoy the unusual protection of the spontaneous portacaval shunt. However, if this shunt proved inadequate, it is doubtful that a surgically prepared shunt could provide further benefit, unless thrombosis or impairment in the adequate spontaneous shunt developed.

Summary

Two cases of portal hypertension are reported, in which a collateral venous channel of considerable magnitude developed from the neighborhood of the splenic hilum to the inferior vena cava, mimicking a surgically produced end-to-side portacaval shunt. The portal vein was thrombosed in each case.

In one case, catheterization of the collateral channel via the brachial vein and vena cava showed a pressure of 18 mm. of Hg compared to 20 mm. of Hg in the splenic pulp. It was also shown not to be a renal vein. One year later the splenic pulp pressure had decreased to normal, and both the portal vein and the spontaneous shunt were visualized by splenoportography.

A large spontaneous portacaval venous shunt may have sufficient hemodynamic

effectiveness that the need for surgical intervention is obviated in certain cases of portal hypertension due to portal vein thrombosis.

References

1. Rousselot, L. M.; Moreno, A. H., and Panke, W. F.: Studies on portal hypertension. IV. Clinical and physiopathologic significance of self-established (nonsurgical) portal systemic venous shunts. *Ann. Surg.* **150**: 384-412, 1959.
2. Hamilton, L. C., and Sullivan, B. H.: Natural portosystemic venous shunts in portal hypertension. *M. Ann. District of Columbia* **30**: 654-659, 1961.
3. Britton, R. C.; Brown, C. H., and Shirey, E. K.: Intrahepatic veno-occlusive disease in cirrhosis with chronic ascites: diagnosis by hepatic phlebography and results of surgical treatment. *Ann. Surg.* **158**: 370-382, 1963.
4. Aufses, A. H., Jr.; Schaffner, F.; Rosenthal, W. S., and Herman, B. E.: Portal venous pressure in "pipestem" fibrosis of liver due to schistosomiasis. *Am. J. Med.* **27**: 807-810, 1959.
5. Tisdale, W. A.; Klatskin, G., and Glenn, W. W.: Portal hypertension and bleeding esophageal varices; their occurrence in absence of both intrahepatic and extrahepatic obstruction of portal vein. *New England J. Med.* **261**: 209-218, 1959.
6. Polish, E.; Christie, J.; Cohen, A., and Sullivan, B. H., Jr.: Idiopathic presinusoidal portal hypertension (Banti's syndrome). *Ann. Int. Med.* **56**: 624-627, 1962.
7. Brown, C. H.; Britton, R. C.; Whitcomb, F. F., Jr., and Turksel, R.: Thrombosis of portal vein with recanalization in hepatic cirrhosis. *Cleveland Clin. Quart.* **29**: 189-196, 1962.
8. Foster, J. H.; Holcomb, G. W., and Kirtley, J. A.: Results of surgical treatment of portal hypertension in children. *Ann. Surg.* **157**: 868-881, 1963.
9. Palmer, E. D.: On natural history of esophageal varices which are secondary to portal cirrhosis. *Ann. Int. Med.* **47**: 18-26, 1957.