

CERVICAL ESOPHAGOSTOMY

Technic and Use

BOYNTON T. WOODBURN, M.D.,* SHATTUCK W. HARTWELL, JR., M.D.,
and

ROBIN ANDERSON, M.D.

Department of Plastic Surgery

CERVICAL esophagostomy is useful in patients who require prolonged tube feedings. Klopp¹ utilized this approach in the treatment of an obstructing esophageal carcinoma. Although routinely employed by a few surgeons, notably Ketcham² who reported 168 esophagostomies, most surgeons are not acquainted with this procedure and therefore perform the conventional gastrostomy. We have found cervical esophagostomy to be of special benefit, and therefore present a description of the technic and a discussion of its use.

Technic

It is helpful to insert a nasogastric catheter preoperatively. Through a short incision two fingerbreadths above and parallel to the clavicle (*Fig. 1A*) the anterior border of the sternocleidomastoid muscle is exposed. It is important to avoid an

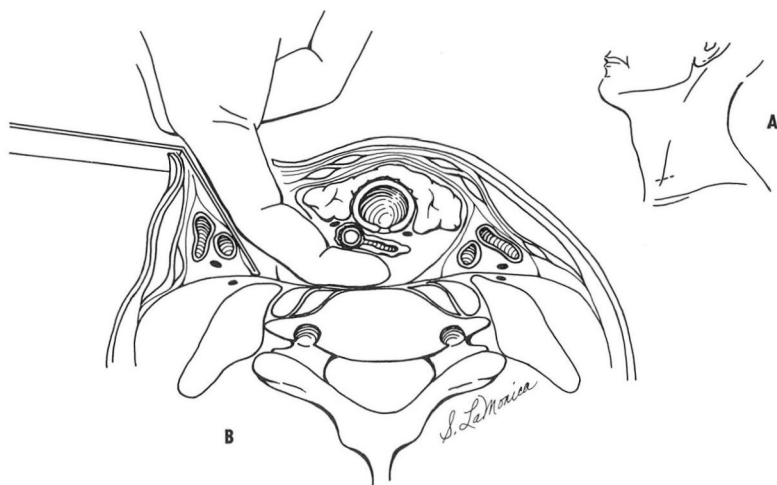


Fig. 1. A, Sketch showing placement of incision for esophagostomy. B, Surgeon's finger is shown with the contents of the carotid sheath retracted laterally and the thyrolaryngeal structures anteromedially.

*Formerly Fellow in the Department of Plastic Surgery, Cleveland Clinic; present address: 1421 Woodland Avenue, Des Moines 14, Iowa.

incision too high in the neck, as the area of esophagus to be opened should be retrotracheal. The investing fascia is opened sharply, and by blunt dissection the sternocleidomastoid muscle is retracted laterally. The areolar tissues are spread, and the contents of the carotid sheath are retracted laterally until a finger inserted into the incision in a posteromedial direction contacts the prominence of the seventh vertebral body. The thyrolaryngeal structures and trachea are anteromedial to the field of dissection.

The surgeon's index finger easily feels the preoperatively placed nasogastric tube in the esophagus (*Fig. 1B*). With gentle finger dissection the esophagus is mobilized behind the upper trachea. The esophageal wall is grasped or held with traction sutures, and an incision is made large enough to admit a 16-French Levin tube which is advanced into the stomach. The preoperatively placed nasogastric tube is removed. The esophageal wound is not closed around the Levin tube. The only sutures necessary are placed in the skin, and they should be spaced so as to allow free drainage. The tube itself acts as a wound-drain, and it should be firmly anchored to the adjacent skin with strong suture. The precaution of careful suture or fixation of the tube as it emerges from the wound is important lest the tube come out before a well-established tract is formed.³

The blunt dissection for exposure of the esophagus will often reveal the recurrent laryngeal nerve and the inferior thyroid artery coursing in the field, but they are easily kept aside. Bleeding is minimal throughout the procedure, which should take from 10 to 20 minutes to complete. Anesthesia, in our experience, has been endotracheal when the operation is done in addition to another procedure about the head or neck, or it has been a general anesthetic administered through a mask. A local anesthetic may be used.²

The esophagostomy tube may be removed and cleaned or changed any time after the first week. The tract is then well established, permitting easy reinsertion of the tube; but there must be no delay in reinserting the tube, for the tract quickly narrows. After the initial change only a simple adhesive tape fixation to the cervical skin is required, and the tube may be conveniently coiled beneath a blouse or shirt when not in use (*Fig. 2*). Closure of the fistula rapidly takes place after removal of the tube.

Results

From July, 1963, to July, 1964, nine cervical esophagostomies were made at the Cleveland Clinic Hospital. The preoperative diagnoses were squamous-cell carcinoma of the tongue (3 patients), recurrent squamous-cell carcinoma of the buccal mucosa (2 patients), malignant melanoma of the maxillary mucoperiosteum (2 patients), squamous-cell carcinoma of the floor of the mouth (1 patient), and fibrosarcoma of the maxilla (1 patient). One of the above-mentioned patients, with far-advanced metastatic carcinoma of the floor of the mouth, has been successfully nourished with a feeding cervical esophagostomy, and will doubtlessly maintain

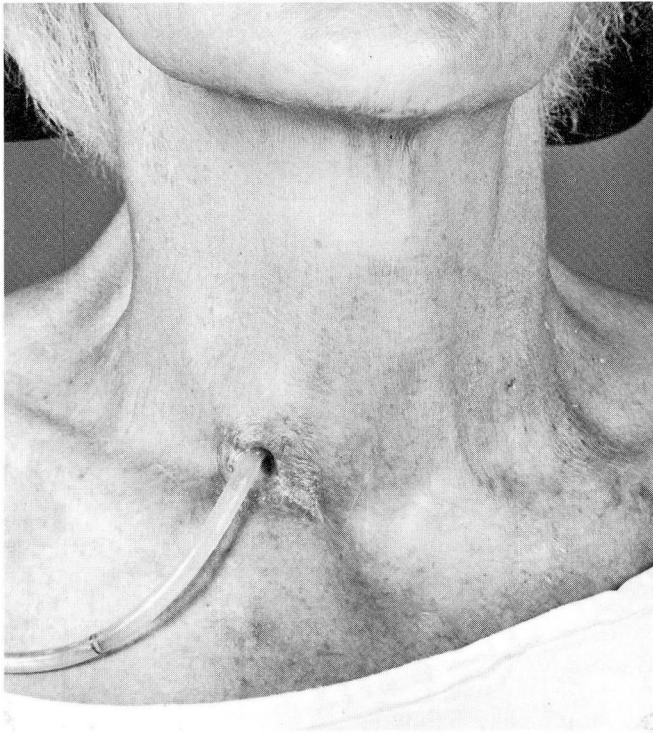


Fig. 2. Photo of conveniently located and mature tract in the lower neck, with the Levin tube in place.

the opening for the rest of his life. Another patient, with carcinoma of the tongue, is also using a feeding cervical esophagostomy; and one patient with squamous-cell carcinoma of the tongue, which was treated with interstitial radiation, used a feeding cervical esophagostomy for several weeks because of the inability to manage food by mouth.

Comment

Three features of the cervical esophagostomy may recommend it in place of gastrostomy: (1) the transperitoneal approach is avoided; (2) the operation should take less time; and (3) the reflux of feeding formula has not been a problem. Obviously, though, cervical esophagostomy is not helpful in the relief of distal obstruction.

Prolonged nasogastric intubation often causes nasopharyngeal discomfort and may result in posterior cricoiditis. However, for short periods of time where a nasogastric catheter is useful there is no need for an esophagostomy. If it is suspected that more than one week with an indwelling tube is necessary, we think the patient is more comfortable with a cervical esophagostomy.

Conditions in which esophagostomy is useful include: major resections in the oropharyngeal area; the acute response to interstitial or external irradiation of the tongue or other oropharyngeal structures, which makes eating difficult; and neurologic or neurosurgical conditions associated with bulbar palsy. Diet and medication are easily administered in familiar suspensions or liquid mediums.

Summary

Cervical esophagostomy is a simple and expedient procedure. The technic, uses, advantages, and disadvantages are discussed. Three features of the cervical esophagostomy may recommend it in place of gastrostomy: (1) the transperitoneal approach is avoided; (2) the operation should take less time; and (3) the reflux of feeding formula has not been a problem.

References

1. Klopp, C. T.: Cervical esophagostomy. *J. Thoracic Surg.* **21**: 490-491, 1951.
2. Ketcham, A. S.: Elective esophagostomy. *Am. J. Surg.* **104**: 682-685, 1962.
3. Dykes, E. R.: Technique for holding indwelling percutaneous tubes and catheters in place. *Surg. Gynec. & Obst.* **118**: 847, 1964.