

IDIOPATHIC RETROPERITONEAL FIBROSIS AND NECROTIZING VASCULITIS

Report of a Case, With Autopsy Findings and Etiologic Consideration

HOWARD E. REIDBORD, M.D.,* and WILLIAM A. HAWK, M.D.

Department of Anatomic Pathology

ORMOND,^{1,3} is generally considered to be the first person to recognize the entity of idiopathic retroperitoneal fibrosis. Since his report in 1948 numerous case reports have been published, with remarkably little variation in the clinical and pathologic findings. Kay⁴ recently reviewed the world literature and summarized the findings in 125 cases. The disease is believed to be increasing in incidence.⁵

The lesion is characterized by formation of a retroperitoneal fibrotic plaque that causes constriction and loss of function of involved structures. The extent of the fibrosis and the amount of inflammation vary considerably.¹⁻⁵ The disease seems to be self-limited, and operative intervention that frees the involved structures results in apparent cure. Etiologic concepts have been widely varied, and little progress has been made in defining the basic process involved.

The rarity of published autopsy studies of idiopathic retroperitoneal fibrosis, and an unusual combination of pathologic findings in a recent example of this disorder prompted the reporting of the following case.

Report of a Case

A 51-year-old white man, an electrician, was first admitted to the Cleveland Clinic Hospital, on April 22, 1964, because of severe anorexia of one month's duration, recently progressing to nausea and vomiting. During that month, tenderness and pain developed over the lumbosacral region, both thighs and calves associated with fatigability and weakness. There were daily febrile episodes of shaking chills, sweating, and elevation of temperature of from 99 to 102 F. orally. Intermittent edema of the ankles had occurred beginning eight months before admission, but no dyspnea or chest pain was present. In March, 1964, the patient was admitted to a local hospital, where blood tests, including a blood urea nitrogen determination, were normal, and an intravenous pyelogram was also reported as normal at that time.

Significant past findings were limited as follows. In February, 1956, swelling of the right side of the chest developed, over the sternum, with thickening of the manubrium demonstrated on roentgenograms. A biopsy of the mass revealed hyperostosis. Laboratory studies at that time disclosed no abnormalities. As a young man, the patient had asthma, but had been symptom-free for 13 years, since 1951. There was no history of peripheral joint symptoms.

On physical examination the patient appeared acutely and chronically ill, dehydrated, and pale. The blood pressure was 142/95 mm. of Hg, the pulse rate was 104 and regular; the temperature was 99 F. There were fine inspiratory rales at both lung bases. A pericardial friction rub was present, and generalized muscular tenderness. Edema of the right leg to the level of the groin, and of the left leg to the level of the knee was demonstrated and was pitting in character. Motion of the spine was limited.

Laboratory findings included: Blood hemoglobin content, 10.9 gm. per 100 ml.; cell volume, 33 percent; white blood cell count, 14,000 per cubic milliliter, with 85 percent neutrophils, 1 percent band forms, 1 percent eosinophils, 3 percent lymphocytes, and 10 percent monocytes. Urinalysis revealed a specific gravity of 1.014, 1+ albumin, and a pH of 5; there were numerous

*Formerly Fellow in the Department of Anatomic Pathology; present address: Armed Forces Institute of Pathology, Washington, D.C. 20025.

red blood cells, white blood cells, and granular casts; 1.3 gm. of protein was excreted per 12 hours. The blood urea nitrogen was 109 mg. percent; creatinine, 5 mg. percent; serum calcium, 8.6 mg. percent; and serum phosphorus, 4.9 mg. percent.

Roentgenograms revealed cardiac enlargement, and a proliferative bony lesion of the upper sternum and adjacent ribs, with an osteolytic lesion in the superior part of the sternum. The lumbosacral spine showed sclerosis, widening of the bodies, and ligamentous calcification. An intravenous pyelogram revealed no distortion, with normal pelvocalyceal and collecting systems.

On the fourth hospital day, a needle biopsy of the kidney revealed membranoproliferative glomerulonephritis with focal glomerular necrosis. Severe oliguria developed, and an increase in blood urea nitrogen content to 400 mg. percent. The patient became acidotic and required peritoneal dialysis. His course was steadily febrile. On the right leg a purpuric rash appeared which gradually spread over the rest of the body. The blood hemoglobin level dropped to 9.4 gm. per 100 ml., and atrial fibrillation, hypotension, and congestive heart failure developed. At no time was the patient hypertensive; he died 12 days after admission to the hospital.

Autopsy Findings

Gross Examination

The autopsy was performed three hours after death. Significant external findings were limited to the lower limbs. The entire right limb to the level of the femoral region and the lower left leg were edematous.

Internal organs. A diffuse fibrinous exudate, up to 0.4 cm. in thickness, covered the visceral and parietal pericardium. The right kidney weighed 305 gm., and the left kidney 295 gm. The subcapsular surfaces were smooth, pinkish gray, and distinctly soft. The calyceal and pelvic systems were normal on both sides, with slight distention of the right renal pelvis. Both ureters appeared thickened in the midportions and were definitely increased in diameter as they passed through a thickened region of the retroperitoneum at the pelvic brim where the ureters appeared to be functionally constricted, but the lumens were patent throughout.

In the retroperitoneum, a fibrous thickening extended from a point 3 cm. above the pelvic brim into the pelvis laterally along the iliac vessels, enclosing those vessels and the ureters bilaterally. The maximum thickness of this fibrotic area was 3.0 cm. It was whitish gray and produced a gritty sensation upon incision. The right iliac vein was completely obstructed by an intraluminal thrombus. The right femoral vein and the right external iliac vein were occluded with reddish-brown thrombus.

Microscopic Examination

Sections from the spleen, kidneys, prostate, adrenals, nerve (sciatic), retroperitoneal region and tissue adjacent to bone revealed an acute necrotizing arteritis involving the small and occasionally the medium-sized muscular arteries (*Fig. 1*). Changes in the arterial walls were characterized by circumferential segmental subintimal collections of basophilic material (fibrin) with polymorphonuclear leukocytic infiltrate. Many small arteries showed subintimal proliferation of fibrocytic cells with occasional cells of a large histiocytic type. The lumen in many vessels was reduced to a pinpoint size. A similar lesion occurred in some medium-sized vessels

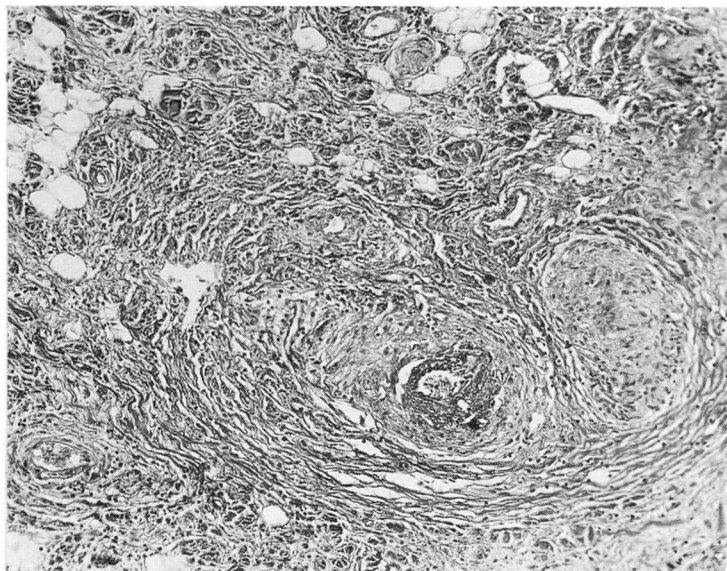


Fig. 1. Photomicrograph showing involvement of a small artery by necrotizing arteritis within the retroperitoneal fibrosis. Hematoxylin-eosin—methylene blue stain; magnification X 100.

where the necrosis (fibrin) was more medial in location. Perivascular lymphocytic accumulations occurred throughout, with some suggestion of concentric collagenic extension into the surrounding perivascular adipose tissue.

Kidneys. Glomeruli showed remarkable proliferation of cellular elements along with obliteration of Bowman's space and numerous synechiae (Fig. 2). Basophilic homogenous material was present in the stalk of most glomeruli, and this extended to the peripheral portion of the glomerular tufts in a fashion suggesting intraluminal distribution. Numerous polymorphonuclear leukocytes were present in the vessels and extended into Bowman's space. The periglomerular tissue was infiltrated with polymorphonuclear leukocytes of apparently glomerular origin. Many eosinophils were in the glomeruli and Bowman's space. Scattered arterioles and small arteries showed the necrotizing process as described above. Focal dark basophilic fragments (so-called nuclear dust) were in and adjacent to intraglomerular vessels.

Retroperitoneum. Scattered throughout the retroperitoneum were large areas of eosinophilic collagenous tissue. The margins were well demarcated and extended out as thin septa into the adjacent adipose tissue (Fig. 3). At many points these septa joined to form continuous sheets of eosinophilic tissue masses. Embedded deep within the collagenous tissue but apparently surrounded by occasional fat cells were vessels showing severe, acute, necrotizing vasculitis as described above. There were numerous perivascular histiocytes, many of which contained brown granular pigment resembling hemosiderin. The perivascular inflammation extended into the adipose tissue and between the collagenous bundles. The remnants of the

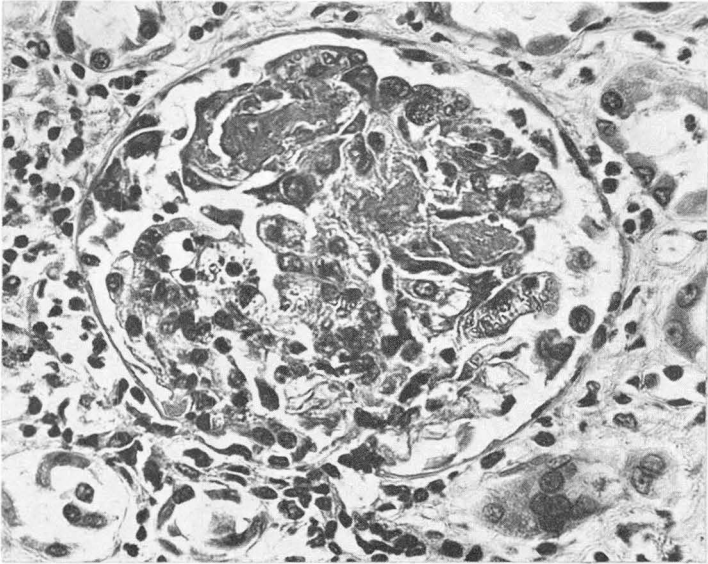


Fig. 2. A higher power view of a glomerulus showing the necrotizing vascular lesion associated with proliferation of cellular elements. Hematoxylin-eosin—methylene blue stain; magnification X 430.

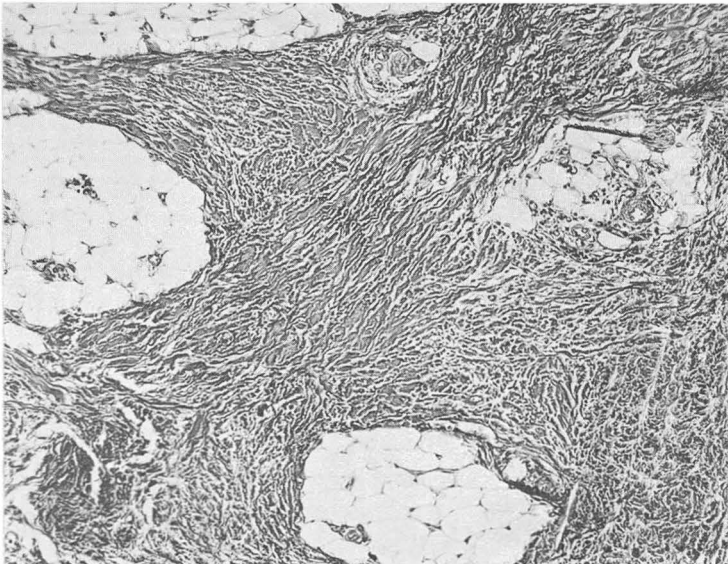


Fig. 3. This photomicrograph shows the extension of mature collagenous connective tissue into the adipose tissue of the retroperitoneum. Hematoxylin-eosin—methylene blue stain; magnification X 100.

vascular lumen showed multiple endothelial-lined channels. Scattered throughout the adipose tissue and among the collagenous bundles were numerous histiocytes with faintly to deeply eosinophilic, slightly granular cytoplasm, and hyperchromatic nuclei from small to moderate in size. The collagen bundles were characteristically wavy and appeared elaborated by elongated spindle-shaped cells with finely dispersed chromatin but no mitotic figures. Numerous capillaries were present.

The eosinophilic collagenous tissue stained with Masson's trichrome stain became the deep green characteristic of collagen. Patches of necrosis in the vascular walls were orange red, and the subintimal regions of the healing and healed vascular regions contained collagenous deposition extending into the perivascular adipose tissue. Phosphotungstic acid-hematoxylin stain demonstrated the red brown of collagenous tissue, and the light blue gray of histiocytes, and the distinctively bright blue of regions of vascular necrosis. A Verhoeff's elastic tissue stain demonstrated numerous wavy, deep-brown to black fibrils between the collagenous bundles and extending into the adipose tissue. The histiocytes showed no evidence of intracytoplasmic fibrillary material. There was considerable disruption of the elastica in all inflamed vessels.

Bone. Sections of the osteosclerotic process in the lumbosacral region showed evidence of mature bone formation with normal cement lines and no evidence of neoplasm. Changes in the sternum and in the region of the osteolytic lesion, described, likewise showed formation of mature bone. Adjacent to the bone there were foci of lymphocytes with some perivascular lymphocytic infiltration; there was evidence of considerable osteoblastic activity.

Discussion

The mass of fibrous tissue at the pelvic brim, involving both ureters and iliac arteries, found at autopsy in the case reported here, is an example of idiopathic retroperitoneal fibrosis first defined by Ormond¹ and subsequently reported in great detail by him^{2,3} and by others.⁴⁻¹⁵ Our patient fits well the classic description by Ormond³ concerning a middle-aged man with primary symptoms of anorexia and backache, in whom oliguria and azotemia subsequently developed. Of the signs and symptoms produced by idiopathic retroperitoneal fibrosis, classification into two general groups is possible, i.e. (1) those caused by obstruction of the ureters, and (2) those produced by invasion of other retroperitoneal structures. The clinical picture in this present case cannot be attributed to obstructive uropathy, inasmuch as the ureters were not significantly obstructed. However, vascular constriction occurred and accounts for the edema of the lower extremities predominantly of the right leg. Edema of the lower extremities has been reported,^{4,8,10} and in some cases inferior venal caval obstruction has been cited as the cause.⁸ In our patient, obstruction of the right iliofemoral vein explained the predominantly unilateral edema. In addition to the characteristic presenting complaints, the reversal of the albumin-to-

globulin ratio and the anemia have been previously reported as occurring in retroperitoneal fibrosis.⁴

Intravenous pyelograms characteristically show medial deviation with obliteration of the midureters in idiopathic retroperitoneal fibrosis.³ The absence of such change in our patient is most unusual. The passage of catheters into the ureters is usually accomplished with ease in cases of retroperitoneal fibrosis, despite the presence of a periureteral fibrotic lesion. However, the ability to pass a catheter is not diagnostic, as complete obstruction of the ureters has been reported several times.^{5,6}

The fibrotic lesion appears to begin in the vicinity of a large retroperitoneal vessel,³ and spreads laterally. Extensive involvement can even affect the biliary tree.^{7,15} The most severe involvement occurs at the site where the ureter passes beneath the iliac artery.^{4,7,11} The perivascular involvement as occurred in our patient, with adjacent ureteral involvement is usual. In spite of the extreme retroperitoneal fibrosis, the nature of the lesion is one of constriction rather than of invasion, and the lumens of the ureter and the great vessels usually remain patent. Lack of peristalsis in the ureter because of the thickening of the adventitial structures accounts for the signs of obstruction.⁷ Constriction of the great veins in the retroperitoneum similarly accounts for the frequency of thrombosis with subsequent edema as observed in the case just reported.

Microscopic examination of the fibrotic area reveals dense bundles of collagenous tissue with typical fibrous connective tissue cells. The collagenous tissue is noted to surround and to compress retroperitoneal structures, but invasion is significantly absent. The amount of inflammatory change varies considerably in the reported cases, but generally is described as lymphocytic in nature.^{2,3} Although mention is made of the tendency to confuse the inflammatory infiltrate with lymphosarcoma,²⁰ this diagnostic pitfall can be avoided by histocytologic study, which will reveal characteristically benign nuclei in the idiopathic retroperitoneal fibrosis.

The nonspecific nature of the change in the retroperitoneum has prompted numerous theories as to the origin. Noted by many observers^{4,6,10} was the tendency toward perivascular accumulation of the infiltrates, sometimes suggestive of granuloma formation. The general appearance has suggested similarity to that seen in Riedel's struma.^{5,13} The coincidence of a primary vasculitis of a hypersensitivity type and retroperitoneal fibrosis is a distinctly unusual occurrence. Hoffman and Trippel¹⁰ reported one case of generalized vasculitis in association with idiopathic retroperitoneal fibrosis. The authors believed that the vascular changes were highly suggestive of periarteritis nodosa. However, the illustrations depict perivascular round-cell infiltrates, and are not the typical changes seen in cases of periarteritis nodosa.^{7,16} The unequivocal necrotizing angiitis in our case in association with characteristic necrotizing focal glomerulonephritis provides the relatively rare opportunity of studying this combination of disease processes. Until 1962, we have

found that only 12 autopsy cases of retroperitoneal fibrosis with associated necrotizing angitis have been reported.³ The type of arteritis observed in the present case is that first recognized by Zeek¹⁶ as being distinct from the typical periarteritis nodosa variety of vasculitis. The similar age of the vascular lesions, the predominant involvement of small vessels, and the characteristic necrotizing glomerulitis, place the present case in the hypersensitivity angitis category.

Much speculation has arisen over the role of arteritis in an idiopathic retroperitoneal fibrosis. The frequent finding of perivascular round-cell infiltrate and the occasional description of arteriolitis have spurred speculation as to an etiologic relationship.^{4,6,8,10} Hackett⁸ noted that idiopathic retroperitoneal fibrosis was similar to Dupuytren's contracture and Peyronie's disease, and that vascular disease may be the only common factor in this group. It is fascinating that the combination of Peyronie's disease and vasculitis was previously noted.¹⁸ Charnock, Riddell, and Lombardo¹¹ suggested that the first phase in the development of retroperitoneal fibrosis may be pathologic changes in the small blood vessels. Hoffman and Trippel¹⁰ provide strong evidence for a relationship between retroperitoneal fibrosis and vasculitis.

One of the most popular theories as to the cause of generalized and severe hypersensitivity angitis is that an autogenic agent is introduced, and subsequently the antigen-antibody response affects primarily the vascular tree. Relationships to vasculitis and drug ingestion, bacterial toxin, or ingestion of foreign protein are well documented.¹⁶ Since hypersensitivity angitis follows a relatively benign course in the absence of renal involvement, complete recovery occurs frequently.¹⁹ In our case, the severe renal disease was unquestionably the major cause of death. This case possibly affords the unusual opportunity to observe retroperitoneal fibrosis in an early stage of development. If there is a relationship between this fibrotic process and vascular disease, it is then quite possible that idiopathic retroperitoneal fibrosis is caused by hypersensitivity angitis without renal involvement, and therefore most patients survive the initial attack, but the fibrotic process continues, bringing on the symptoms of ureteral obstruction. The extensive treatment given our patient accounts for the early healing lesion seen in the retroperitoneal area, and one might theorize that complete recovery would have occurred in the absence of the severe renal involvement.

The presence of joint symptoms in association with idiopathic retroperitoneal fibrosis seems to have been reported only once previously.⁴ The patient's presenting symptom was an unusual sternal lesion that histologically most closely resembled the so-called March fracture, that is an area of osteoblastic activity with the formation of mature bone seen in repeatedly stressed bones. The changes in the spine, seen both at autopsy and on roentgenograms, were characteristic of rheumatoid spondylosis. This unique combination of retroperitoneal fibrosis, vasculitis, and rheumatoid change suggests a primary etiologic collagen disease.

Summary

This report describes the clinicopathologic correlations in a case of hypersensitivity angitis with renal failure and retroperitoneal fibrosis revealed at autopsy. The sclerosing process did not produce an obstructive uropathy as is generally encountered in retroperitoneal fibrosis; the renal failure developed on the basis of the glomerular lesions. The retroperitoneal lesion appeared to have been in its early stages of formation and offered an opportunity to describe the process in its incipency. It is possible that this case supports speculation that an arteritis and/or arteriolitis bears an etiologic relationship to retroperitoneal fibrosis. The possible relationships among the various disease processes described in this report are discussed.

References

1. Ormond, J. K.: Bilateral ureteral obstruction due to envelopment and compression by inflammatory retroperitoneal process. *J. Urol.* **59**: 1072-1079, 1948.
2. Ormond, J. K.: Idiopathic retroperitoneal fibrosis: established clinical entity. *J.A.M.A.* **174**: 1561-1568, 1960.
3. Ormond, J. K.: Idiopathic retroperitoneal fibrosis: Ormond's syndrome. *Henry Ford Hosp. M. Bull.* **10**: 13-20, 1962.
4. Kay, R. G.: Retroperitoneal vasculitis with perivascular fibrosis. *Brit. J. Urol.* **35**: 284-291, 1963.
5. Hawk, W. A., and Hazard, J. B.: Sclerosing retroperitonitis and sclerosing mediastinitis. *Am. J. Clin. Path.* **32**: 321-334, 1959.
6. Park, H., and Jones, I.: Periureteric fibrosis. *Lancet* **I**: 195-196, 1958.
7. Raper, F. P.: Idiopathic retroperitoneal fibrosis involving ureters. *Brit. J. Urol.* **28**: 436-446, 1956.
8. Hackett, E.: Idiopathic retroperitoneal fibrosis; condition involving ureters, aorta, and inferior vena cava. *Brit. J. Surg.* **46**: 3-9, 1958.
9. Samellas, W.: Ureteral obstruction due to compression by idiopathic retroperitoneal inflammatory process. *J. Urol.* **85**: 928-933, 1961.
10. Hoffman, W. W., and Trippel, O. H.: Retroperitoneal fibrosis: etiologic considerations. *J. Urol.* **86**: 222-231, 1961.
11. Charnock, D.; Riddell, H. I., and Lombardo, L. J., Jr.: Retroperitoneal fibrosis producing ureteral obstruction. *J. Urol.* **85**: 251-257, 1961.
12. Thompson, R. J., Jr.; Carter, R.; Gibson, L. D.; Reiswig, O. K., and Hinshaw, D. B.: Acute idiopathic retroperitoneal fibrosis. *Ann. Surg.* **153**: 399-406, 1961.
13. O'Regan, R.; Treahy, P. A., and Prior, I. A.: Idiopathic retroperitoneal fibrosis. Case presenting with renal failure, treated effectively with adrenal steroids. *New Zealand M. J.* **60**: 518-521, 1961.
14. Harrow, B. R., and Sloane, J. A.: Idiopathic retroperitoneal fibrosis. *J.A.M.A.* **182**: 38-43, 1962.

15. Schneider, C. F.: Idiopathic retroperitoneal fibrosis producing vena caval, biliary, ureteral and duodenal obstructions. *Ann. Surg.* **159**: 316-320, 1964.
16. Zeek, P. M.: *Periarteritis nodosa*: critical review. *Am. J. Clin. Path.* **22**: 777-790, 1952.
17. Reidbord, H. E., and McCormack, L. J.: Primary vasculitis (necrotizing angiitis) and related disorders. I. Autopsy study of twenty-seven cases. *In preparation*.
18. Reidbord, H. E., and McCormack, L. J.: Primary vasculitis (necrotizing angiitis) and related disorders. II. Clinicopathologic correlation of thirty-two patients with biopsy evidence of primary vasculitis. *In preparation*.
19. McCombs, R. P.; Patterson, J. F., and MacMahon, H. E.: Syndromes associated with "allergic" vasculitis. *New England J. Med.* **255**: 251-261, 1956.
20. Levine, M.; Schwartz, S.; Allen, A., and Narciso, F. V.: Lymphosarcoma and periureteral fibrosis. *Radiology* **82**: 90-95, 1964.