

# ALTERATION OF COLLAGEN IN GENERALIZED SCLERODERMA (PROGRESSIVE SYSTEMIC SCLEROSIS) AFTER TREATMENT WITH DIMETHYL SULFOXIDE

## Preliminary Report

ARTHUR L. SCHERBEL, M.D.,  
*Department of Rheumatic Disease*

LAWRENCE J. McCORMACK, M.D.,  
*Division of Pathology*

and

MARTIN J. POPPO, M.D.\*  
*Department of Rheumatic Disease*

**D**IMETHYL SULFOXIDE<sup>†</sup> is a versatile commercially available solvent possessing many chemical properties that have industrial value. It can reduce the freezing point of water, moisten and disperse particles, and form complexes with many inorganic salts. Lovelock and Bishop<sup>1</sup> reported that dimethyl sulfoxide prevented damage to living cells and tissues, during low-temperature preservation, by preventing formation of water crystals and by reducing the concentration of intracellular salt. Dimethyl sulfoxide has been used to preserve red blood cells, white blood cells, bone marrow, bovine spermatozoa, and whole organs before transplantation, by low temperature or freezing technics.<sup>2-6</sup> Numerous observations on the clinical effects of dimethyl sulfoxide have been reported by Jacob, Bischel, and Herschler<sup>7</sup> and by Rosenbaum and Jacob.<sup>8</sup> Toxicity reactions have not been significant in more than 1000 patients who have received dimethyl sulfoxide.<sup>9</sup> In our experience, the most dramatic and consistent effect resulting from the topical application of this chemical is relief of pain resulting from musculoskeletal trauma, acute bursitis, tendinitis, or myalgia. Less dramatic relief of pain and stiffness has occurred in patients with osteoarthritis; and variable relief of pain, swelling and stiffness in the joints has occurred in patients with rheumatoid disease. In April, 1964, we began a study of the effect of dimethyl sulfoxide on the ischemic ulcers and cutaneous manifestations in 10 patients who have generalized scleroderma (progressive systemic sclerosis).

## Methods

Of the 10 patients with scleroderma, six were treated primarily for multiple ischemic ulcerations of fingertips, and four patients were treated for cutaneous

\*Fellow in the Department of Rheumatic Disease.

†Supplied through the courtesy of James M. Shaffer, M.D., Medical Director, Merck Sharp & Dohme, West Point, Pennsylvania.

manifestations. Skin biopsy specimens from fingers, dorsa of the hands, and forearms were obtained before treatment and serially thereafter at from three- to four-week intervals.

### Administration of Dimethyl Sulfoxide

Topical administration of dimethyl sulfoxide is much more complicated than we originally anticipated. In our experience the concentration of dimethyl sulfoxide must be individualized for each patient as well as for various parts of the body. Usually a burning or sharp prickling sensation associated with transient erythema occurred during the application of dimethyl sulfoxide. This then subsided in from 30 to 60 minutes after the chemical penetrated the skin. In some patients temporary blistering of the skin occurred or prolonged severe itching, or hives appeared, especially when the concentration of dimethyl sulfoxide was excessive for the individual.

Cutaneous reactions usually subsided in the majority of patients after one week, at which time the strength of dimethyl sulfoxide could be increased and there was no recurrence of cutaneous reactions. We believe that perhaps an intracutaneous Herxheimer-like reaction occurs from the release of certain substances, possibly tissue amines (histamine, serotonin, norepinephrine) or a peptide (bradykinin). If this concept is correct, it can be assumed that after tissue depletion has occurred in patients with scleroderma, the tolerance for increased concentrations of dimethyl sulfoxide will increase. Therefore, in most instances a 50 percent concentration of dimethyl sulfoxide was used initially, the concentration gradually being increased during the next course in from one week to three weeks until 100 percent was reached or the highest concentration tolerated by the patient.

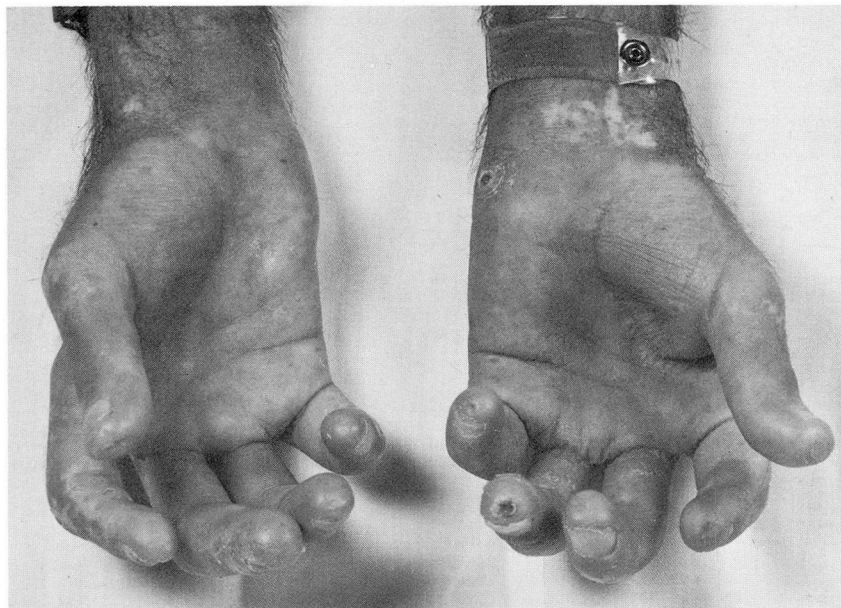### Effect of Dimethyl Sulfoxide on Ischemic Ulcers

Six patients with ischemic ulcers of the fingers, for six months or longer without spontaneous improvement, received 90 percent concentration of dimethyl sulfoxide directly on the ulcers. In four patients the ulcers began to heal after one or two days and were completely healed after two weeks. In one patient the ulcers healed completely after six weeks, and in one patient a burning sensation and severe pain occurred despite application of only a 50 percent concentration of dimethyl sulfoxide. Each attempted increase in the concentration of the chemical resulted in more pain. After four weeks, therapeutic efforts were discontinued; there was no change in the appearance of the ulcer.

The following is a brief case summary that describes the usual effect of dimethyl sulfoxide on the healing of the persistent ischemic ulcers.

**Case 1.** A 28-year-old man was admitted to the Cleveland Clinic Hospital on July 26, 1964, because of severe scleroderma of three years' duration. Four ischemic ulcers were present: a large one at the tip of the fourth finger of the left hand, two smaller ones adjacent to the eponychium

of each index finger, and one over the pisiform bone (*Fig. 1*). The ulcers had been present constantly for six months and were extremely painful. A 90 percent solution of dimethyl sulf-



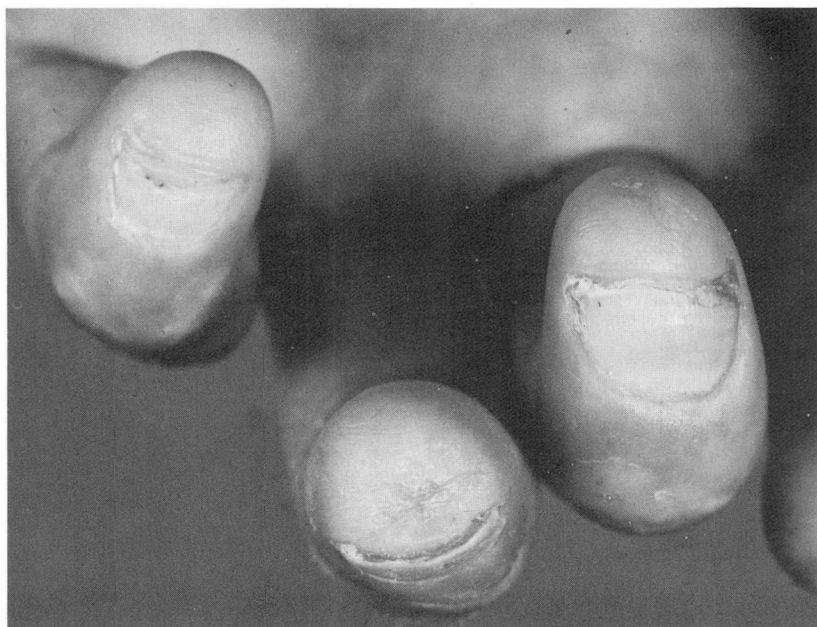**Fig. 1.** Case 1. Hands of 28-year-old man with scleroderma of three years' duration before treatment with dimethyl sulfoxide. Note deep ulcerations over the tip of the fourth finger and over the pisiform bone of the left hand.

oxide was applied to the lesions with a small piece of cotton. Initially the pain increased for a few minutes and then subsided completely. Repeated applications of 1 ml. of 90 percent dimethyl sulfoxide at three-hour intervals alleviated the pain that previously was persistent and severe. On the second day of treatment the ulcer on the tip of the fourth finger started to heal and closed completely on the tenth day of treatment (*Fig. 2*). The ulcers on the index fingers were treated by immersing the fingertips in 90 percent dimethyl sulfoxide solution for one minute every two hours. After one week, a slight softening of the skin over the fingertips and a slight increase in flexibility of each distal phalangeal joint were observed.

#### Effect of Dimethyl Sulfoxide on Cutaneous Manifestations of Scleroderma

Because of the subtle but definite improvement in the terminal phalanges of the patient cited above, it was decided to apply dimethyl sulfoxide topically on large areas of the body in other patients. Four patients with scleroderma were treated in this manner. Two patients initially received dimethyl sulfoxide topically over the entire body twice daily, and two patients over the extremities three times daily.

In general, the upper portion of the body was more sensitive to dimethyl sulfoxide than the lower portion. Most patients tolerated a dilute concentration of dimethyl sulfoxide over the face, neck, chest, and upper extremities. The axillae were usually more sensitive to dimethyl sulfoxide than the arms. In some patients the strength of dimethyl sulfoxide could not be increased and, therefore, a weak



**Fig. 2.** Case 1. Close-up of third, fourth, and fifth fingers of left hand of same patient as in *Figure 1* after 10 days of treatment with dimethyl sulfoxide. Note complete healing of ulcer on tip of fourth finger.

concentration was used at frequent intervals during the day. In most patients tolerance for the higher concentrations of dimethyl sulfoxide occurred in certain areas of the body, whereas for other areas a dilute concentration only could be tolerated.

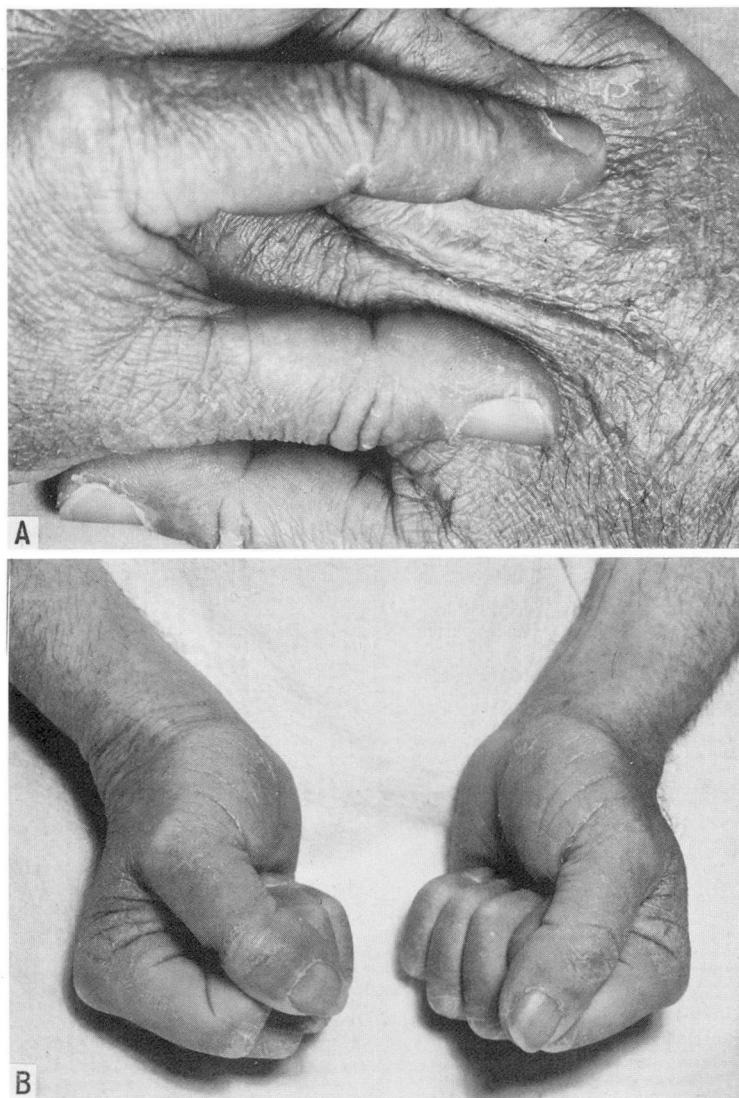
**Case 2.** A 64-year-old man weighing 57 kg. was admitted to the Cleveland Clinic Hospital on September 3, 1964, because of rapidly progressive scleroderma of approximately 15 months' duration, clinically manifested by generalized cutaneous and pulmonary involvement. On November 6, 1964, dimethyl sulfoxide, 90 percent strength, was applied topically to the entire body. After one application the concentration was reduced to 50 percent because of severe burning sensation and itching. With this dilution of dimethyl sulfoxide only a burning sensation over the neck and the trunk of the body was noted. The chemical was applied topically twice daily; after one week the concentration was increased to 70 percent for the upper extremities, and to 90 percent for the lower extremities. A burning sensation occurred over the trunk each time the concentration was increased in that area. After four weeks of treatment, grip strength that initially was 120 mm. of Hg increased to 210 mm. of Hg. Flexion of the fingers, which had been restricted 50 percent, increased 20 percent. The tight skin over the hands, fingers, and forearms began to loosen (*Fig. 3A*). During the second week of treatment, joint motion increased both in extension and in flexion. At the end of eight weeks, grip strength had increased to 250 mm. of Hg bilaterally and the skin was loose and pliable over the hand; the patient was able to flex completely the fingers of both hands (*Fig. 3B*).

Serial skin biopsy specimens were obtained at adjacent sites from a finger, the dorsum of the hand, and from the left upper mid-forearm at three-week intervals. After five weeks he was discharged from the hospital and was advised to continue topical application of dimethyl sulfoxide. During his tenth week of treatment, pain in the chest and a cough associated with chills and fever developed. A roentgenogram of the chest revealed pneumonitis, which was treated with



an antibiotic, and application of dimethyl sulfoxide was discontinued. Treatment with dimethyl sulfoxide was maintained for 10 weeks. Two weeks later the patient was readmitted to the hospital because of persistent dyspnea.

The daily dosage of dimethyl sulfoxide received during the first 10 weeks of treatment is estimated to be 0.7 gm. per kilogram of body weight. During this time 3000 gm. of dimethyl sulfoxide were given to this patient. This is a crude estimate of the total dosage, inasmuch as an



**Fig. 3.** Case 2. Hands of 64-year-old man with scleroderma (of 15 months' duration) after four weeks of treatment with dimethyl sulfoxide. Note pliable skin (A) and complete flexion (B) of all fingers.

undetermined amount of the solution was lost during application, and it is not possible to determine accurately the amount absorbed through the skin. The problem of estimating the total dosage that this patient received also applies to those of other patients who are included in this report.

**Case 3.** A 68-year-old woman weighing 53 kg. was admitted to Cleveland Clinic Hospital on July 28, 1964, with scleroderma of 10 years' duration. During that time she noted generalized tightening of the skin and subcutaneous tissue over the extremities and the face. For eight years, ischemic ulcers of the fingertips recurred, but usually healed spontaneously. During the last year, recurrent ulcers of the fingertips became persistent and increasingly painful. Initially, small amounts of 90 percent concentration of dimethyl sulfoxide were applied to the ulcers. Four of the five ulcers healed rapidly during a period of 10 days. One large ulcer became irritated from the application of dimethyl sulfoxide, which was then discontinued for one week. The concentration of dimethyl sulfoxide was then reduced to 50 percent, but healing did not occur. Further attempts to apply dimethyl sulfoxide in higher concentrations resulted in a severe burning sensation of the fingers, which was not tolerated by the patient. Therefore, dimethyl sulfoxide was not applied to the fingers, but the rest of the upper extremities and the entire lower extremities were covered three times daily with 70 percent dimethyl sulfoxide. After two weeks the concentration was increased to 90 percent. After two months it was reduced to one application daily. The patient's daily dosage is estimated to be 0.12 gm. per kilogram of body weight. The total dosage is estimated to be 768 gm. during a period of four months. Biopsy sections of skin from a finger and of skin from the forearm obtained before treatment, six weeks after treatment, and 14 weeks after treatment depict morphologic changes believed to be associated with the cutaneous application of this chemical.

The morphologic changes observed in this patient seem to be representative of those in the group of patients. Sections from the arm that had been treated with dimethyl sulfoxide for six weeks showed a zone beneath the epidermis that appeared loose and edematous and stained less brilliantly than the untreated area (control) in the hematoxylin-and-eosin-stained preparations. Sections stained by the Rinehart—Abul Haj method (Fig. 4) and by the Alcian-blue

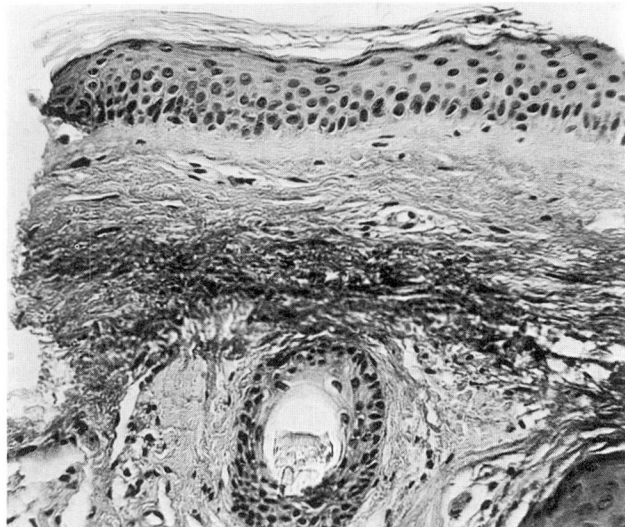
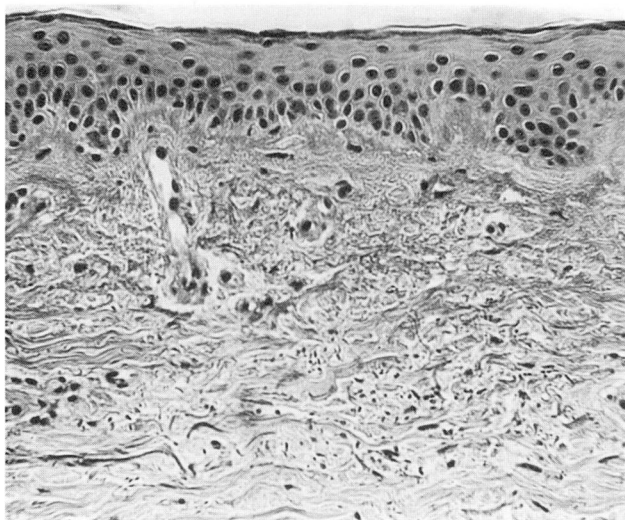


Fig. 4. Photomicrograph of forearm showing a darkly staining colloidal-iron-positive zone in the dermis which is characteristic of acid mucopolysaccharides. A small "horn cyst" is seen immediately beneath the zone of activity. Rinehart—Abul Haj stain; magnification X 220.

periodic acid—Schiff method showed a positively staining area that had the appearance of acid mucopolysaccharide immediately beneath the epidermis. The coloration was removed by hyaluronidase. The collagen was actually decreased in density, as evidenced by a less amount of periodic acid—Schiff positive collagen bundles. The elastic tissue stain (Gomori's aldehyde



fuchsin) dyed a concentration of elastic fibers within the same area. The section from the ring finger that was not treated showed none of these changes (*Fig. 5*), and there was a uniform and scattered distribution of elastic tissue.



**Fig. 5.** Photomicrograph of control area (finger) showing epidermis and a dense subepidermal zone characteristic of scleroderma. Rinehart—Abul Haj stain; magnification X 220.

Eight weeks later, tissue from areas adjacent to the previous biopsies showed further changes. The pale subepidermal zone was still present in the hematoxylin-and-eosin-stained sections from the treated forearm, as well as a decrease in periodic acid—Schiff positive material (mature collagen), but acid mucopolysaccharide material (Rinehart or Alcian-blue positive) was absent. There was a large concentration of elastic fibers in the superficial dermis in the area where the previous positivity for acid mucopolysaccharides was noted. No further histologic changes were apparent in the skin from the ring finger; the elastic tissue was still evenly dispersed.

**Case 4.** A 55-year-old woman weighing 60 kg., with scleroderma of five years' duration, was admitted to the Cleveland Clinic Hospital on October 8, 1964. On October 13, 1964, total body topical application, twice daily, with 75 percent concentration of dimethyl sulfoxide was started. After the first week of treatment slight loosening and softening of the skin became noticeable. During the second week, excessive drying of the skin occurred, and lanolin cream was applied twice daily. Slow but progressive generalized improvement in musculoskeletal mobility has continued since treatment was started. After four months of treatment all fingers could be extended to 180 degrees and the patient could make a full grip with each hand. Moderate morning stiffness is still present in the right hand, but only slight transient stiffness in the left hand. This patient continues to apply a 75 percent concentration of dimethyl sulfoxide once daily to all extremities. Her daily dosage is estimated at 0.12 gm. per kilogram of body weight. She has applied approximately 840 gm. in four months.

**Case 5.** A 59-year-old woman weighing 60 kg., with scleroderma that was present for two and one-half years, was examined at the Cleveland Clinic on October 10, 1964. At that time, there were swelling and tightness of the skin of fingers, forearms, face, chest, and lower extremities. Deep pigmentation was present over the face and extremities. On October 15, treatment with 90 percent dimethyl sulfoxide was started, consisting of topical applications of the chemical twice daily to all extremities. The arms were covered liberally from the shoulders to the fingertips, and the legs were covered from the hips to the toes. One month after treatment was started the patient noted slight increase in mobility of the fingers, wrists, knees, and ankles. Before treatment was begun she could flex her fingers only to approximately one-half inch from the thenar and hypothenar eminences; two months later the fingers could be flexed completely

into each palm. Slow and progressive improvement was manifested by further loosening of the skin and more flexibility of the joints, for a period of three months, but no change was apparent in the deeply pigmented skin. During the fourth month of treatment increased stiffness of the fingers again became noticeable. The daily dosage of dimethyl sulfoxide is estimated to be 0.3 gm. per kilogram of body weight. She has absorbed approximately 2,025 gm. in four months.

## Discussion

The application of dimethyl sulfoxide on ischemic ulcers of scleroderma appeared to hasten the healing of chronic lesions in five of six patients treated. The pharmacologic action responsible for this effect is not known, but it seems logical to assume that increased permeability of the tissue surrounding the ulcers results in increased oxygen and nutrition necessary for normal healing to occur.

The histologic alterations in collagen fibers as noted in serial skin biopsy specimens from four patients receiving topical application of dimethyl sulfoxide over large areas of sclerodermatous skin indicate that unusual focal biochemical activity in regard to collagen is taking place. In our experience these morphologic changes have not been observed previously in patients with scleroderma. However, the elastic tissue changes evidenced as an intense concentration of fibers in the subepidermal zone may not be the result of the therapy but may be a manifestation of the disease itself.

Our preliminary clinical observations on cutaneous manifestations of scleroderma after long-term topical application of dimethyl sulfoxide suggest that the amount of collagen within the skin and subcutaneous tissue is slowly but progressively decreasing in these patients. Joint motion may increase to hyperextensibility (*Fig. 6*). The clinical impression is confirmed by the histologic alterations in collagen. The unusual morphologic changes observed in these patients are similar to changes observed in the skin of the forearms in persons with Cushing's syndrome: these patients show an edema of the dermis with an apparent loss of collagen, and the appearance of material simulating either edema or acid mucopolysaccharide deposition.<sup>10</sup> We are unable to determine from these studies whether or not the destruction and eventual disappearance of collagen is directly related to a pharmacologic action of dimethyl sulfoxide; or whether or not dimethyl sulfoxide merely initiates collagen destruction by increasing cellular permeability and allowing for the release of increased quantities of proteolytic enzymes (lysosomes, collagenase) which then destroy collagen. The abundance of elastic tissue fibers that remain apparently unaltered after collagen has been removed would suggest that the biochemical reaction responsible for the histologic changes described herein is selective for collagen.

In the serial laboratory determinations of these patients, obtained at weekly intervals for the first month of treatment and subsequently at monthly intervals, no abnormal values have been observed in regard to the blood hemoglobin, total white blood cell count, differential blood cell count, routine urinalysis, blood



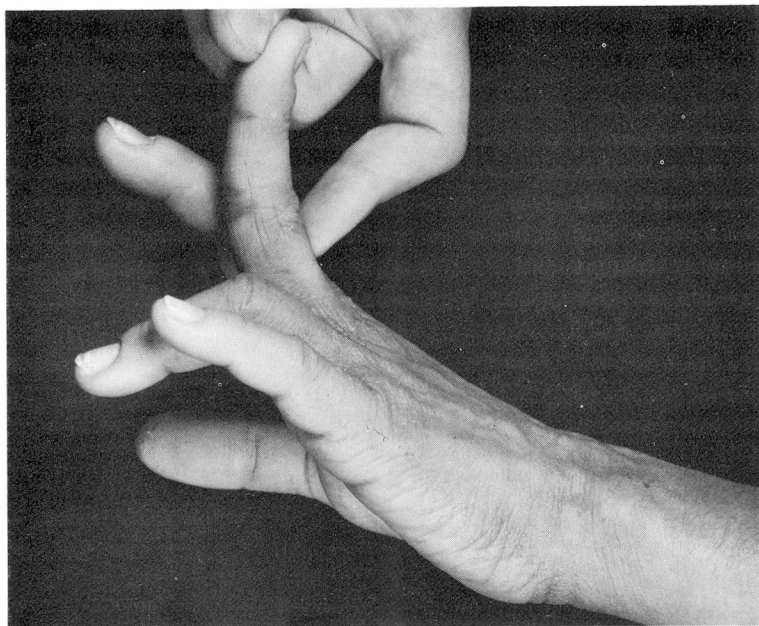

Fig. 6. Case 3. Hands of patient with scleroderma. Note hyperextensibility of fingers in patient with scleroderma after three months of topical treatment with dimethyl sulfoxide.

urea, serum transaminase, serum alkaline phosphatase, and fasting blood sugar.

It is clear that more study is necessary before a definite opinion can be given in regard to these initial observations. Furthermore, no conclusions can be made at this time concerning the overall value of dimethyl sulfoxide in the treatment of scleroderma. It is well known that many systems of the body may become involved in this disease, and it is unlikely that collagen deposition in other organs or systems, such as heart, kidneys, lungs, gastrointestinal tract, and central nervous system, is significantly influenced by cutaneous absorption of dimethyl sulfoxide. If destruction of elastic tissue fibers would result from the administration of dimethyl sulfoxide, this chemical would obviously be contraindicated as a therapeutic agent. At the present time we do not have histologic evidence that the elastic tissue fibers are altered in any way from the use of this chemical. The effects of dimethyl sulfoxide on cutaneous collagen in scleroderma appear to be significant and are in need of further clarification.

### Summary

1. Persistent ischemic ulcers of the fingertips in five of six patients with scleroderma healed rapidly with repeated topical applications of dimethyl sulfoxide.

2. Cutaneous manifestations characterized by tightening of the skin and binding of the subcutaneous tissue lessened in four patients receiving long-term repeated total body topical application of dimethyl sulfoxide.

3. Morphologic changes from serial skin biopsies showed an initial increase in acid mucopolysaccharides that eventually disappeared.

4. Inasmuch as scleroderma is a multiple-system disease, no conclusions can be made at this time concerning the overall value of topical application of dimethyl sulfoxide in the treatment of this disease.

### References

1. Lovelock, J. E., and Bishop, M. W. H.: Prevention of freezing damage to living cells by dimethyl sulphoxide. *Nature* **183**: 1394-1395, 1959.
2. Ashwood-Smith, M. J.: Preservation of mouse bone marrow at  $-79^{\circ}$  C. with dimethyl sulphoxide. *Nature* **190**: 1204-1205, 1961.
3. Conferences. Preservation of bone-marrow; from correspondent. *Lancet* **2**: 657, 1961.
4. Deshpande, P. J.; Fellman, J., and Jacob, S. W.: Studies on viability of hearts following depression of freezing point. (Abs.) *Circulation* **26** (part 2): 708, 1962.
5. Rowe, A. W., and Fellig, J.: Freezing experiments with rabbit bone marrow. (Abs.) *Blood* **19**: 521-522, 1962.
6. Rowe, A. W., and Rinfret, A. P.: Controlled rate freezing of bone marrow. (Abs.) *Blood* **20**: 636-637, 1962.
7. Jacob, S. W.; Bischel, M., and Herschler, R. J.: Dimethyl sulfoxide (DMSO): New concept in pharmacotherapy. *Current Ther. Res.* **6**: 134-135, 1964.
8. Rosenbaum, E. E., and Jacob, S. W.: Dimethyl sulfoxide (DMSO) in acute musculoskeletal injuries and inflammations: I. Dimethyl sulfoxide in acute subdeltoid bursitis. *North-west Med.* **63**: 167-168, 1964.
9. Rosenbaum, E. E.: Personal communication, February 15, 1965.
10. Hazard, J. B., and Curtis, G. H.: Personal communication, February 1965.