

# STRESS FRACTURE IN CHILDHOOD

## Report of Two Cases

SAMUEL SAWMILLER, M.D.,\* WILLIAM M. MICHENER, M.D., M.S. (PEDIAT.),  
*Department of Pediatrics*

and

J. TED HARTMAN, M.D.  
*Department of Orthopedic Surgery*

**S**TRESS fracture in childhood is a relatively rare injury, apparently only 71 cases having been reported in the English literature to 1963.<sup>1</sup> The entity is also recognized by the name 'fatigue fracture,' or, in the special case of the foot, 'march fracture.' According to Meyerding and Pollack,<sup>2</sup> in 1855 Breithaupt described the complication occurring in soldiers after long marches. In 1897, soon after the advent of roentgenograms, the stress injury was demonstrated to be a hairline fracture.

An early description of stress fractures in children is that of Roberts and Vogt<sup>3</sup> in 1939. Their report concerned 12 children each with a painful limp and no history of trauma. All of the children subsequently proved to have fractures involving the upper third of the tibia a few inches below the epiphysis. In a recent paper by Devas,<sup>1</sup> stress fractures are reported as having occurred in the tibia, fibula, humerus, rib, pelvis, sesamoid bones, metatarsals, and femora of children up to 16 years of age. In the "series of more than 40 patients," it was noted that the tibia was the bone most commonly fractured in children. The child usually has a painful limp of gradual onset, avoids the bearing of weight, and feels most comfortable when at rest. Examination reveals some swelling around the area of fracture (usually the upper tibia) accompanied by tenderness up and down the shaft.

Limp in children often poses a problem of differential diagnosis, especially if there is no history of trauma. The little-known entity of stress fracture is an interesting and easily proved diagnosis that may be added to the list of possible diagnoses. This paper discusses diagnosis and treatment, and reports the cases of two children who had tibial stress fractures, the primary symptom of which was limping with no pain.

### Pathogenesis and Diagnosis

The etiology of stress fracture remains obscure, but it is thought to be the repeated small strains and insults to an area much like those associated with fatigue stress in metal.

Speed and Blake<sup>4</sup> in 1933 demonstrated the typical roentgenographic course of the stress fracture. At the time of onset of symptoms, roentgenograms show evidence only of soft tissue swelling near the affected site. In from one to three

\*Intern, Cleveland Clinic Hospital.

weeks the next appearance is that of periosteal fuzziness; an accompanying hairline fracture may or may not be visible. The periosteal fuzziness then progresses to evidence of abundant formation of callus surrounding the fracture. The final stage is the formation of overabundant spindle-shaped callus.

The problem of differential diagnosis was discussed by Hartley<sup>5</sup> in 1942. Because the lesions occur without a history of acute trauma, and do not always show typical changes on roentgenograms when they are first studied, they may easily be mistaken for bone tumors or infectious processes. The excessive proliferation of callus that accompanies the fracture closely resembles the new bone seen in osteogenic sarcoma. Linscheid and Coventry<sup>6</sup> stated that a biopsy should be performed if any doubt exists as to the diagnosis. Yet, even a biopsy specimen can present a confusing picture, much like that seen in osteogenic sarcoma. The biopsy tissue in this situation must be cautiously interpreted, with full knowledge by the clinician and the pathologist of the clinical course and the roentgenographic appearance.

### Treatment

The treatment of stress fracture of the tibia is rest and/or immobilization in a walking cast. The following two case histories demonstrate that stress fractures should be included in the differential diagnosis of a child with a limp, and that pain may be minor or entirely absent.

### Report of Cases

**Case 1.** A 6½-year-old boy was first examined at the Cleveland Clinic on May 31, 1962, because of a limp of three weeks' duration which the parents described as "favoring the left leg." There was no history of trauma. During the three weeks, examinations by two physicians disclosed no abnormality. The knees according to the roentgenograms were normal. One examiner attributed the limp to new shoes.

The patient's history and family history were noncontributory.

Physical examination revealed the child to be 45½ in. tall and to weigh 48¾ pounds. All of the findings were entirely normal with the exception that the left leg was favored in walking, and the left foot was held in external rotation. The deep-tendon reflexes were active and equal bilaterally. There was no limitation of motion or pain in either the hips or the knees, nor was there evidence of external trauma to the lower extremities.

The routine laboratory tests were normal. The sedimentation rate (modified Rourke-Ernestene method) was 0.65 mm. per minute on the day of examination, but decreased to 0.25 mm. per minute two days later. Serum values were: calcium, 10.2 mg. per 100 ml.; phosphorus, 5.6 mg. per 100 ml.; alkaline phosphatase, 3.6 Bodansky units. The chest and hips were normal according to roentgenograms. Anteroposterior views of the lower extremities revealed evidence of periosteal reaction of the left upper tibia approximately 4 cm. distal to the tibial epiphysis. The bone in this area appeared somewhat sclerotic. Selected regional views showed more clearly a small radiolucent line traversing the area. These changes were believed to be consistent with a stress fracture (*Fig. 1*).

The patient was placed in a long-leg cast with a walking heel, and was discharged to his home. After five weeks, the cast was removed, and there was no tenderness over the tibia and no limp. Progress roentgenograms showed good formation of callus, and solid union of the fracture (*Fig. 2*).

**Case 2.** A 6-year-old boy was first examined at the Cleveland Clinic on June 18, 1962, because of a limp, involving the right leg, of three weeks' duration. At no time had he complained of pain in the legs or hips. There was no history of trauma. The patient had been examined by an orthopedic surgeon who prescribed corrective shoes for a structural defect thought to be

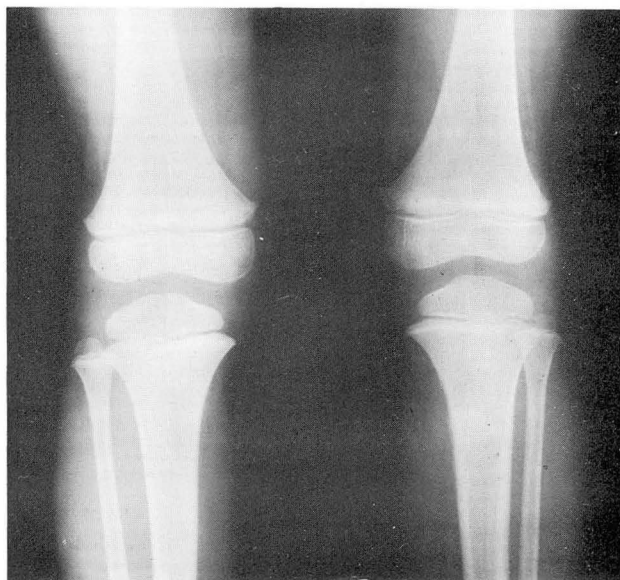

Fig. 1. Case 1. Roentgenogram taken on May 31, 1962, showing stress fracture of the left tibia.

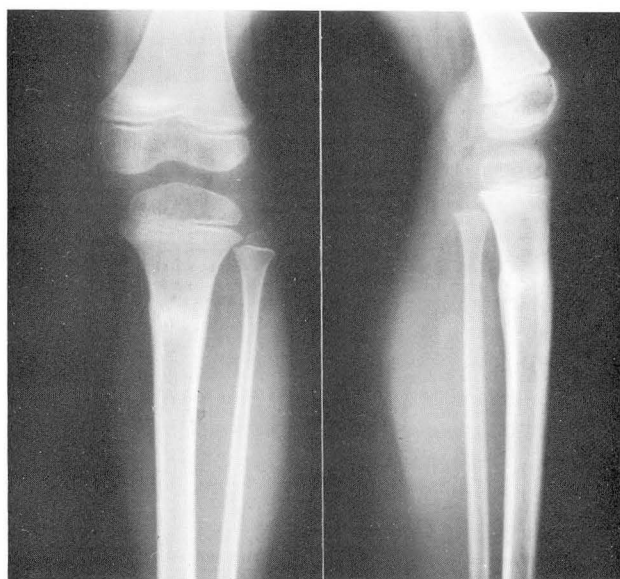
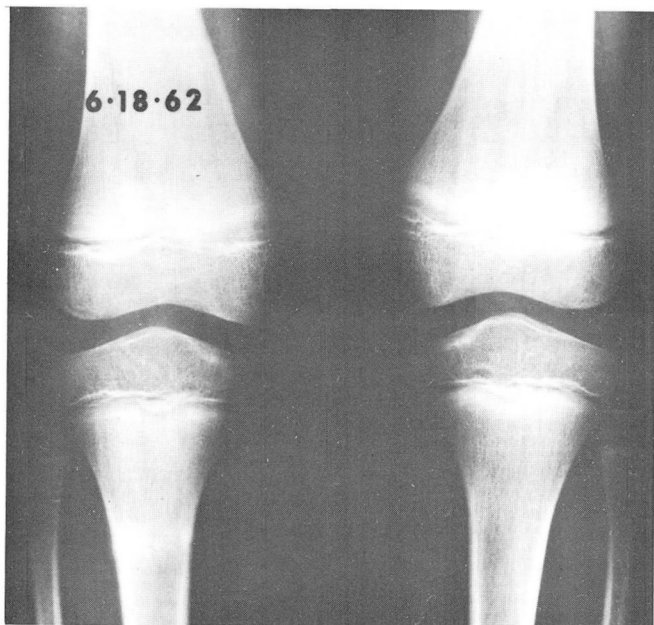
Fig. 2. Case 1. Progress roentgenogram taken on July 3, 1962, showing the healed fracture.

present in the arches. There was improvement of the limp for several days after wearing of the shoes; then the limp returned and persisted.

At the physical examination the boy appeared to be healthy and cooperative. He was 49 in. tall and weighed 66 pounds. The findings were entirely normal and there was no evidence of external trauma to the lower extremities. The patient walked with a definite limp favoring the right leg.

The laboratory tests were all within normal limits. Roentgenograms of the legs revealed evidence of a stress fracture of the right upper tibia (*Fig. 3*).



*Fig. 3.* Case 2. Roentgenogram taken on June 18, 1962, showing stress fracture of the right tibia.

A long-leg walking cast was applied and worn for five weeks. When the cast was removed, progress roentgenograms showed evidence of a well-healed stress fracture (*Fig. 4*).

#### Comment

The two boys had typical stress fractures, and the presenting symptom in each was a painless limp that developed without prior trauma. It should be noted that these two patients were seen in the early stage of injury, obviating the differential diagnostic problems in relation to a possible tumor or an infectious process. Typically, the stress fractures were undiagnosed until the changes had become apparent on roentgenograms.

#### Summary

Stress fractures in children are discussed with the object of calling the clinician's attention to an unusual condition to be considered in the differential diagnosis of limp of children. The true incidence of this condition in children is probably not

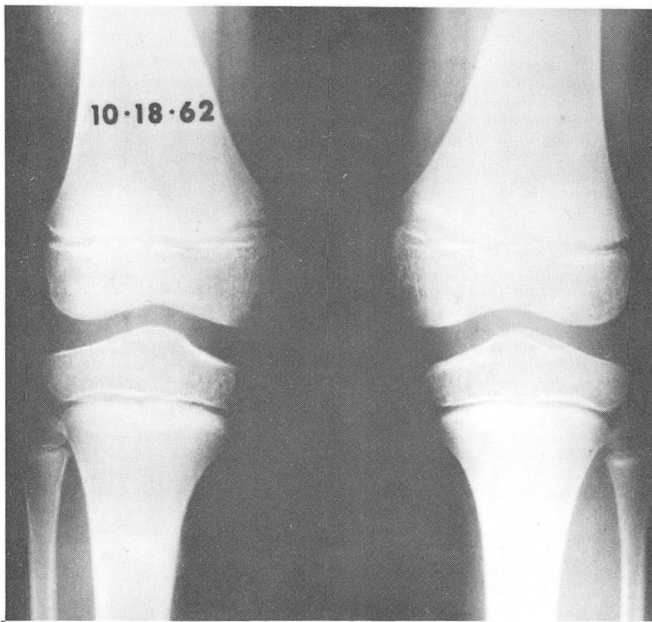


Fig. 4. Case 2. Progress roentgenogram taken on October 18, 1962, showing the healed fracture and callus.

accurately reflected by the fact that apparently relatively few cases have been reported. The tibia is the most common site of involvement in children, and the limp usually is of gradual onset. Generally there is no history of trauma to the region. Physical examination reveals slight swelling at the site of the fracture and a tenderness along the shaft. Evidence of the fracture may not be roentgenographically apparent until after the onset of symptoms. Stress fractures in the leg respond well when treated with a walking cast, and recovery from them is complete.

#### References

1. Devas, M. B.: Stress fractures in children. *J. Bone & Joint Surg.* **45-B**: 528-541, 1963.
2. Meyerding, H. W., and Pollock, G. A.: March fracture; Deutshlaender's Krankheit, Marschgeschwulst, Fussgeschwulst, Marschfraktur, fracture-de-recrue, pied debile, pied forcé, pied de marche, l'enflure du pied, pied surchargé. *Surg. Gynec. & Obst.* **67**: 234-242, 1938.
3. Roberts, S. M., and Vogt, E. C.: Pseudofracture of tibia. *J. Bone & Joint Surg.* **21**: 891-901, 1939.
4. Speed, J. S., and Blake, T. H.: March foot. *J. Bone & Joint Surg.* **15**: 372-382, 1933.
5. Hartley, J. B.: Fatigue fracture of tibia. *Brit. J. Surg.* **30**: 9-14, 1942.
6. Linscheid, R. L., and Coventry, M. B.: Unrecognized fractures of long bones suggesting primary bone tumors. *Proc. Staff Meet. Mayo Clin.* **37**: 599-606, 1962.