

'MISSED' APPENDICITIS: A CONTINUING DIAGNOSTIC CHALLENGE

Report of a Case

RICHARD G. FARMER, M.D.,

Department of Gastroenterology

and

RUPERT B. TURNBULL, JR., M.D.

Department of General Surgery

DESPITE advances in diagnostic technics the early recognition of appendicitis continues to be a major diagnostic problem. Approximately 200,000 cases of appendicitis are recognized in the United States each year, associated with an overall mortality rate of about 1 percent.¹ Perforation with abscess and/or peritonitis continues to be the most important factor in mortality.²⁻⁴ This complication occurs in about one patient in six,¹ and the mortality rate increases significantly among those patients with coexisting systemic disease, the very young, the very old, and pregnant women.^{1,2}

In the effort to prevent appendiceal perforation an early diagnosis must be made and an operation be performed within 36 or 48 hours after the onset of symptoms.⁵ Obviously, this diagnosis requires a high index of suspicion on the part of the physician, and attempts have been made to categorize the early symptoms suggestive of appendicitis. Cope⁶ described the following sequence of symptoms and findings for appendicitis: epigastric or umbilical pain, nausea or vomiting, local iliac tenderness, fever, and leukocytosis. Bonilla, Hughes, and Bowers⁵ consider that the features suggesting appendiceal rupture are: duration of symptoms for longer than 48 hours, elevation of body temperature to more than 103 F., physical signs of peritonitis, leukocyte count of more than 20,000 per cubic millimeter, and a palpable abdominal mass. However, development of generalized peritonitis after appendiceal perforation is not inevitable, and a pelvic abscess of considerable proportion may develop without other characteristic features.^{2,7} Cope⁶ described the perforated pelvic appendix as "... one of the most easily overlooked, and therefore one of the most dangerous, conditions which may occur in the abdomen."

We recently examined a patient in whom the onset of the symptoms occurred three weeks before examination, and for whom the diagnosis of appendicitis could be made only retrospectively. Because of the atypical manifestations of such a common condition as appendicitis in this patient, we believe that this case warrants publication.

Report of a Case

A 17-year-old student was admitted to the Cleveland Clinic Hospital on January 6, 1965, because of pain in the lower abdomen, fever, and diarrhea since December 17, 1964. The patient

was able to recall that on that date he experienced fatigue and malaise, and chills and fever to 105 F. developed. He seemed to have symptoms of an upper respiratory infection with nasal discharge, and had vomited several times. The abrupt onset of watery diarrhea occurred, and was explosive, foul smelling, and without blood, but there were no cough, dyspnea, joint pains, or urinary symptoms. He was treated by his local physician with antidiarrheal agents and antibiotics. During the next 10 days the symptoms decreased, and by December 28 there was only one loose bowel movement daily. On January 1, 1965, pain in the lower abdomen began, which the patient described as similar to a "muscle strain." Fever and diarrhea recurred on January 2. He also noted abdominal distention, and the pain became dull, aching, and more or less continuous. Another antibiotic was prescribed on January 2; the symptoms were not relieved. He had never previously experienced similar symptoms.

His history, his family's history, and a review of the physiologic systems were noncontributory. His only hospitalization had been for a tonsillectomy at the age of 7 years.

At the physical examination the patient was 69½ in. tall and weighed 151 pounds (this represented a 21-pound weight loss in the three weeks' duration of the illness). The temperature was 102 F., pulse rate was 104 and regular, and the blood pressure was 140/70 mm. of Hg. The patient was well oriented and appeared moderately ill; there was no jaundice. The head, neck, chest, heart, and lungs were normal. The tongue was mildly dry but there was no inflammation of the pharynx. The abdomen was tense, but there was no rebound tenderness and no mass could be palpated. The lower part of the abdomen appeared somewhat distended, but a definite mass could not be palpated. Results of the rectal examination and the remainder of the physical examination were normal.

Sigmoidoscopic examination to a level of 7 in. revealed considerable spasm, but the mucosa was normal. Between 4 and 6 in. on the anterior wall of the rectum there were considerable edema and fixation, and it was difficult to advance the sigmoidoscope beyond that point. The clinical impression was that an extraluminal mass was present.

Results of initial laboratory studies were: blood hemoglobin, 14.8 gm. per 100 ml.; cell volume, 47 ml. per 100 ml.; white blood cell count, 14,600 per cubic millimeter, with 73 percent segmented neutrophils, and 14 percent nonsegmented neutrophils. A white blood cell count the next day was 20,100 per cubic millimeter and 81 percent segmented neutrophils. Other initial laboratory data included normal urinalysis, serum calcium, serum phosphorus, blood urea, and sugar values. The serum electrolyte values were: carbon dioxide, 27.7 mEq. per liter; chloride, 94 mEq. per liter; potassium, 4.7 mEq. per liter; and sodium, 140 mEq. per liter. A serum protein electrophoretic pattern revealed 3.07 gm. of albumin, 0.64 gm. of α -1-globulin, 1.21 gm. of α -2-globulin, 0.77 gm. of β -globulin, and 1.41 gm. of γ -globulin per 100 ml. of blood. The stool culture was negative for *Staphylococcus*, *Salmonella*, and *Shigella*. The chest roentgenogram was normal. A plain film of the abdomen (Fig. 1) was reported as follows: "There is considerable distention of the colon with gas to the region of the sigmoid. There is a large soft tissue mass filling the pelvis. There is also considerable gas in the small intestine suggesting an obstructing lesion in the sigmoid. No evidence of free air beneath the diaphragm." A roentgenogram after barium enema (Fig. 2) showed no filling of the appendix, and was reported as follows: "There is a long area of sigmoid colon which is narrowed and has a coiled spring appearance much like that seen in intussusception. An area of approximately 4 cm. is incompletely filled and there is disruption of the mucosal pattern. The colon proximal to this area in the sigmoid is considerably dilated. A large mass filling the entire pelvis is causing extrinsic pressure upon the tip of the cecum. On the evacuation film a portion of the terminal ileum is visualized and is displaced by this large pelvic mass. It is impossible to determine whether this mass arises from the area in the sigmoid or from other pelvic structures and is causing extrinsic pressure on the sigmoid. This could represent a large inflammatory mass in the sigmoid and terminal ileum, but suspect that it may represent a large neoplasm such as a lymphoma which is filling the pelvis." Because of the patient's age and the location and suggested inflammatory character of the abdominal mass, appendicitis with abscess was considered a likely diagnosis. A lymphangiogram (Fig. 3) and an intravenous urogram proved the mass to be within the peritoneal cavity.

Subsequent laboratory studies included normal blood hemoglobin determinations on January 8 and January 11; the white blood cell counts were 14,500 and 7,600 per cubic millimeter, respectively.

After the first day in the hospital the patient experienced symptomatic improvement. The temperature rose to 102 F. within the first 24 hours of admission, but after midday of January 8 (less than 48 hours after admission) he became afebrile and remained so. He was given a liquid diet, but intubation was not performed nor was he given fluids intravenously. The abdominal distress and diarrhea decreased rapidly with symptomatic therapy. He was given a course of tetracycline, 250 mg., four times daily for two weeks, and was discharged from the hospital on January 13. He was examined again on January 22, at which time his weight was 164 pounds,

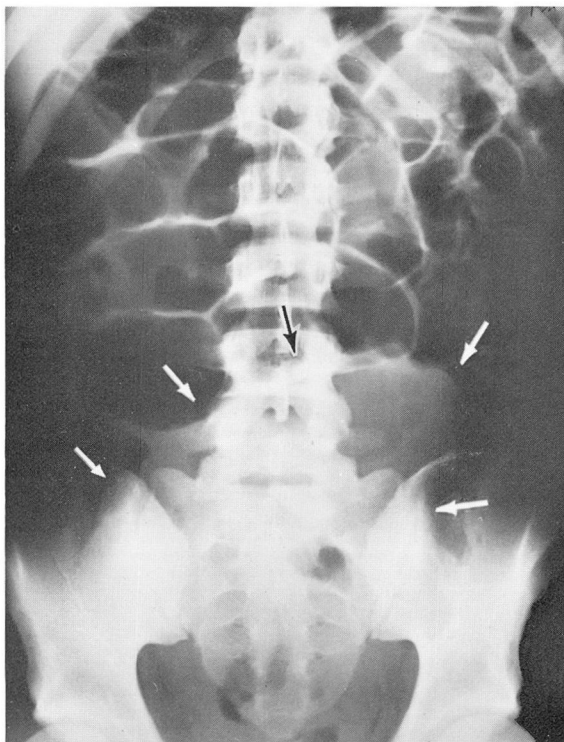


Fig. 1. Roentgenogram (plain film) of the abdomen, showing evidence of partial intestinal obstruction and a large pelvic mass.

an increase of 13 pounds. There had been no diarrhea, and only mild discomfort in the lower abdomen. At that time the abdomen was soft and not tender and no mass could be palpated. The results of the rectal examination were normal.

The patient was next examined on February 3, 1965, at which time he was asymptomatic and had returned to school. Sigmoidoscopic examination to a level of 10 in. revealed entirely normal tissues. There were no mucosal edema, no difficulty in passing the sigmoidoscope, and no sign of extraluminal pressure. There had been no fever, diarrhea, or abdominal discomfort since he had completed the course of tetracycline therapy. The blood hemoglobin was 14.7 gm. per 100 ml., and the white blood cell count was 6,200 per cubic millimeter, with a normal differential blood count. A plain roentgenogram of the abdomen was normal. A roentgenogram of the colon (Fig. 4) after barium enema was normal, with no sign of a pelvic mass. The patient was seen on March 8 and May 10, 1965, and was well and asymptomatic.

Discussion

Although there are many studies on the diagnosis and course of appendicitis, in approximately 3 percent of patients an appendiceal abscess will be recognized. The mortality rate among those patients remains about 12 percent despite the use of modern therapeutic methods.^{2,8} The duration of symptoms longer than 48 hours, abdominal pain that may intensify and then recede, and the subsequent develop-

ment of pronounced leukocytosis, fever, diarrhea, and a palpable abdominal and/or rectal mass, have been considered the hallmarks of a perforated appendix with abscess formation.^{5,6} After the development of a pelvic abscess, the symptoms

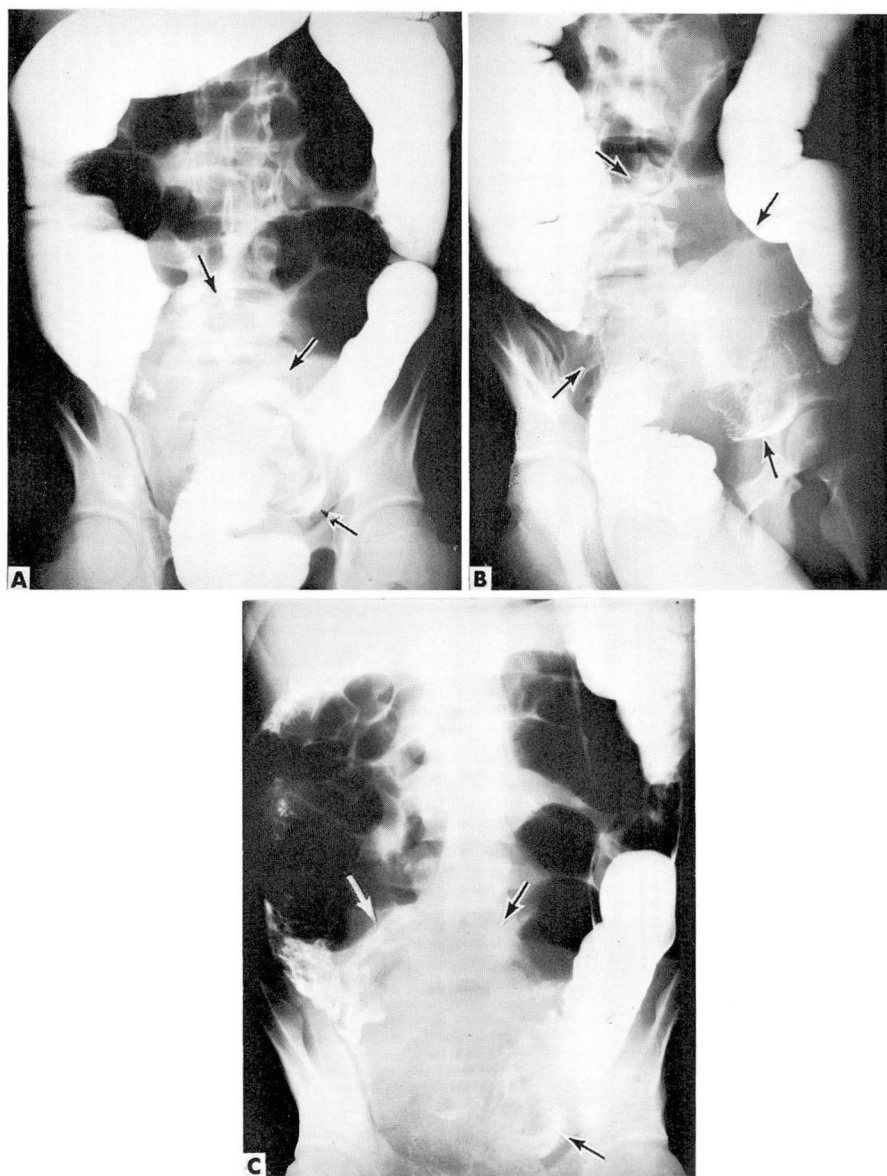


Fig. 2. Roentgenogram of the abdomen after barium enema, showing pelvic mass with extrinsic pressure on the sigmoid colon and irregularity of the cecum.

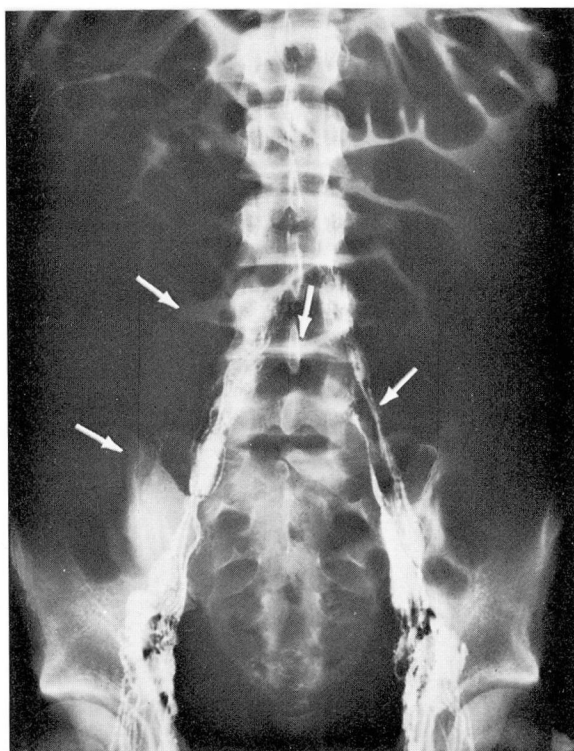


Fig. 3. Lymphangiogram showing normal lymphatic structures. Note outline of pelvic mass.

may be alleviated and a biphasic symptom pattern may be present, as in the case we have reported. Likewise the diagnosis can be suspected after a sigmoidoscopic examination and from roentgenograms taken after a barium enema.⁹ In the case just described, abdominal examination did not reveal signs of diffuse peritonitis, but a large pelvic mass was readily demonstrable by sigmoidoscopy, a plain roentgenogram of the abdomen, and a roentgenogram after a barium enema. A lymphangiogram and an intravenous urogram were normal, and helped to localize the mass in the abdomen rather than in the retroperitoneal space.

The diagnostic dilemma of a long-standing appendiceal abscess (missed appendicitis) may be difficult to resolve, but the therapeutic dilemma may be even more of a problem. Since the published report by Crile¹⁰ that an appendiceal abscess can be treated conservatively with antibiotics, other surgeons have agreed that after the appendiceal abscess has developed, therapy with antibiotics is as successful as surgery.^{3,11} If the symptoms of an appendiceal abscess are recognized early, most investigators continue to recommend operation, but Hawk, Becker, and Lehman¹¹ showed that there was no difference in outcome whether or not opera-

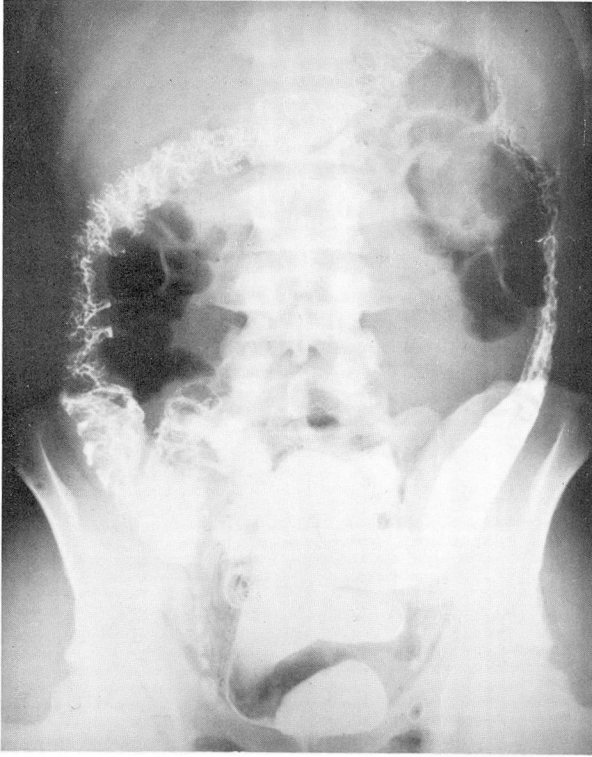

Fig. 4. Roentgenogram after barium enema, showing normal structures.

tion was performed. Likewise, it has been pointed out that appendiceal abscesses may resolve spontaneously, with or without antibiotic therapy.^{9,10} The mortality rate of 12 percent may well reflect attempts to operate on an appendiceal abscess when conservative therapy with antibiotics would have been more appropriate. Furthermore, surgical drainage of the abscess often is not possible initially.² Although there is no general agreement, in two standard textbooks^{3,9} conservative therapy is recommended when the symptoms have been of long duration and are subsiding.

The case just reported emphasizes the difficulty of early diagnosis, the temporary alleviation of symptoms and the subsequent recurrence (presumably at the time of development of an appendiceal abscess), and the rather severe systemic reaction present. It is easy to realize the potential seriousness for a patient who was not in good general health at the time of onset of symptoms of appendicitis. Because mortality for appendiceal abscesses remains high, the importance of early diagnosis is self-evident. Furthermore, it behooves the physician to maintain a high index of suspicion for the atypical manifestations of such a common disease, in order that

appropriate measures may be instituted rapidly. Ruptured appendix with abscess should be the first diagnostic consideration for any young patient with signs of pelvic inflammation, fever, abdominal pain, mass, and leukocytosis. We agree with Crile¹⁰ that all patients for whom the diagnosis of appendiceal abscess is suspected should receive a course of antibiotic therapy under careful observation, and that immediate operation is not indicated under such circumstances.

Summary

A case of 'missed' appendicitis—appendicitis with ruptured appendix and late development of a pelvic abscess—is presented, and the diagnostic pitfalls as well as the severity of the clinical illness are described. Conservative therapy was considered to be appropriate under the circumstances, and the pelvic abscess resolved completely in one month. The importance of early diagnosis of appendicitis and appendectomy before development of an abscess is emphasized, as well as the potential seriousness of the appendiceal abscess.

References

1. Editorial. Appendicitis. *J.A.M.A.* 180: 154, 1962.
2. Barnes, B. A.; Behringer, G. E.; Wheelock, F. C., and Wilkins, E. W.: Treatment of appendicitis at Massachusetts General Hospital (1937-1959). *J.A.M.A.* 180: 122-126, 1962.
3. Zollinger, R. M., and Howe, C. T.: The Small and Large Intestine, p. 664-722, in Davis, L. (ed.): *Christopher's Textbook of Surgery*, 8th ed. Philadelphia: W. B. Saunders Co., 1964, 1481 p.
4. Thieme, E. T.: Appendicitis; 15-year survey. *A.M.A. Arch. Surg.* 70: 207-212, 1955.
5. Bonilla, K. B.; Hughes, C. W., and Bowers, W. F.: Experiences with management of ruptured appendix. *Am. J. Surg.* 102: 439-443, 1961.
6. Cope, Z.: The Early Diagnosis of the Acute Abdomen, 11th ed. London: Oxford University Press, 1957, 188 p.; p. 45-74.
7. Howie, J. G.: Too few appendectomies? *Lancet* 1: 1240-1242, 1964.
8. Collins, D. C.: 71,000 human appendix specimens. Final report, summarizing forty years' study. *Am. J. Proctol.* 14: 265-281, 1963.
9. Raffensperger, E. C.: The Appendix, chap. 80, p. 1088-1121, in Bockus, H. L.: *Gastroenterology*, vol. 2, 2d ed. Philadelphia: W. B. Saunders Co., 1964, 1241 p.
10. Crile, G., Jr.: Peritonitis of appendiceal origin treated with massive doses of penicillin; report of 50 cases. *Surg. Gynec. & Obst.* 83: 150-162, 1946.
11. Hawk, J. C., Jr.; Becker, W. F., and Lehman, E. P.: Acute appendicitis and analysis of 1003 cases. *Ann. Surg.* 132: 729-741, 1950.