

MALIGNANT ARGENTAFFINOMA

Report of a Case of an Eleven-Year-Old Boy

DAVID H. BARBER, M.D.,* and WILLIAM M. MICHENER, M.D., M.S. (PEDIAT.)

Department of Pediatrics

ALTHOUGH the occurrence of argentaffinoma in the pediatric age group has been well documented,^{1,3} it is an unusual tumor of childhood. Field, Adamson, and Stoeckle¹ recently reviewed 19 reported cases of patients up to 16 years of age, and added a case of a functional tumor in a boy 15 years old. The majority of reported argentaffinomas in children have been isolated tumors of the appendix,² discovered at the time of laparotomy for appendicitis. Childhood extra-appendiceal argentaffinomas have occurred in a Meckel's diverticulum,³ as a single polypoid lesion of the stomach,⁴ and as ilial tumors producing intussusception.⁵ The case reported by Field, Adamson, and Stoeckle apparently is of the youngest patient in whom a preoperative diagnosis was made.

This report concerns a case of an extraappendiceal malignant argentaffinoma that developed in the ileum of a child aged 11 years.

Report of a Case

An 11-year-old white boy was first examined at the Cleveland Clinic Hospital in August, 1964, because of recurrent cramping abdominal pain of 11 months' duration. Cramping discomfort had been episodic, lasting from 10 to 15 minutes, confined to the lower abdomen, and characteristically after meals. For several months his parents had noted nocturnal borborygmi. There had been no change in bowel habits.

In November, 1963, two months after the onset of the illness, and again one week before examination at the Cleveland Clinic, the patient was admitted to a hospital. At the time of the initial hospitalization, upper gastrointestinal and colon barium-contrast studies were performed and were reported as disclosing no abnormality. Progression in the severity of the cramping abdominal pain with accompanying distention, nausea, vomiting, and obstipation had prompted the second hospitalization 10 months later. Barium-contrast roentgenographic studies again were normal.

On physical examination he appeared to be a well-developed child in acute distress, with severe abdominal cramping pain. The blood pressure was 116/68 mm. of Hg; pulse rate was 80; and temperature was 98.6 F. There was a slight malar flush. The heart and lungs were normal. The abdomen was slightly distended; no enlargement of the spleen or liver was noted. A distended loop of bowel was visibly evident and palpable transabdominally in the left lower abdominal quadrant. The rectal examination disclosed no abnormality.

Initial laboratory studies revealed a blood hemoglobin content of 14.4 gm. per 100 ml., and cell volume of 44 percent. The white blood cell count was 7,300 per cubic millimeter and 51 percent segmented neutrophils, 3 percent nonsegmented neutrophils, 14 percent monocytes, and 32 lymphocytes. The urinalysis was normal. The blood urea, carbon dioxide content, serum chloride, serum potassium, and serum sodium determinations were normal.

A roentgenogram of the chest disclosed a normal appearance of the heart, mediastinum, and lungs. A plain roentgenogram of the abdomen revealed residual barium in the colon from an examination conducted the previous day. A prominent loop of small bowel was noted in the left lower abdomen. During the course of the first two days in the hospital, the patient had intermittent lower abdominal pain, the periods of acute discomfort being accompanied by mild distention and the presence of a palpable tender distended loop of bowel in the left lower quadrant.

*Fellow in the Department of Pediatrics.

On the third hospital day a small-bowel roentgenographic study showed a region of narrowing in the midjejunum with distention of the proximal portion of the bowel (*Fig. 1*). The

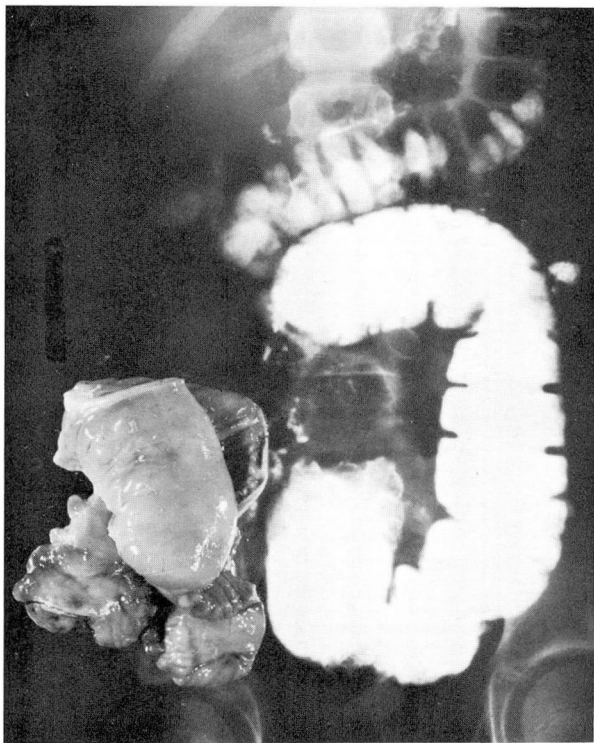


Fig. 1. Montage demonstrating the roentgenogram of the small bowel and the resected tumor in its relative position.

remainder of the small bowel was normal in appearance. A presumptive diagnosis of intermittent volvulus was considered and laparotomy* was undertaken on the same day.

A tumor was found, affecting the midportions of the ileum, which had stenosed the lumen of the intestine and had dilated the proximal bowel for a distance of 40 cm. There were several large mesenteric lymph nodes that were grossly affected by the tumor; enlarged lymph nodes could be palpated in the periaortic chain and the lower surface of the liver was studded with firm nodular masses. A mesenteric lymph node was excised, and frozen sections disclosed the tumor to be a malignant argentaffinoma (*Fig. 2 and 3*). A segment of small bowel, 59 cm. long, was resected, together with its mesentery. Secondary tumor was present in 6 of the 30 lymph nodes.

During the postoperative period, 24-hr. urine specimens were collected for determination of 5-hydroxyindoleacetic acid. The first specimen, on the ninth day, yielded 18 mg.; at three months, 32 mg.; and at eight months, 26 mg. Subsequently the patient made an excellent recovery, is free of all symptoms, and has gained 32 pounds, eight months postoperatively.

Summary

A case is reported of malignant argentaffinoma in an 11-year-old boy whose presenting symptoms were chronic intermittent small-bowel obstruction, without

*The operation was performed by Robert E. Hermann, M.D., of the Department of General Surgery.⁶




Fig. 2. Photomicrograph of low-power view of mass of tumor in the mesentery, extending into the muscularis of the bowel. Hematoxylin and eosin stains; magnification X 10.

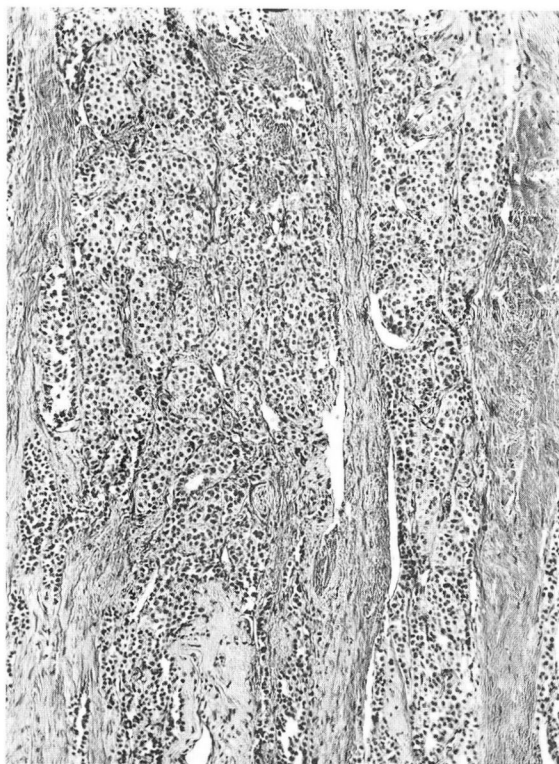


Fig. 3. Higher power view than that in *Figure 2*, showing sheets of uniform tumor cells within the muscularis of the ileum. Hematoxylin and eosin stains; magnification X 100.

the symptoms usually associated with metastatic spread of the tumor. Postoperative urinary assays confirmed the presence of more than normal amounts of 5-hydroxyindoleacetic acid. No treatment other than surgical excision of the obstructing primary neoplasm was undertaken. Eight months postoperatively the patient is free of symptoms despite elevation of urinary 5-hydroxyindoleacetic acid values.

References

1. Field, J. L.; Adamson, L. F., and Stoeckle, H. E.: Review of carcinoids in children; functioning carcinoid in 15-year-old male. *Pediatrics* 29: 953-960, 1962.
2. Oeconomopoulos, C. T.: Argentaffin cell tumors (carcinoids) of appendix in children. *Pediatrics* 27: 134-139, 1961.
3. Hicks, J. A. B., and Kadinsky, S.: "Carcinoid tumour" of Meckel's diverticulum. *Lancet* 2: 70, 1922.
4. Lutzow-Holm, G.: Carcinoid tumors of stomach; two cases. *Acta chir. scandinav.* 104: 193-200, 1952.

5. McCartney, E. T., and Stewart, I.: Argentaffin tumour of ileum with intussusception. *Brit. M. J.* **1**: 769, 1959.
6. House, H. C., and Hermann, R. E.: Review of nine cases of functioning malignant carcinoid treated at Cleveland Clinic. In preparation.