

# Cleveland Clinic Quarterly

Volume 32

JULY 1965

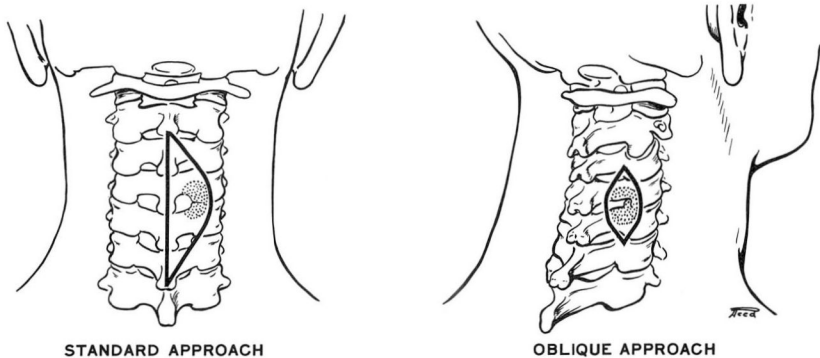
No. 3

## AN OBLIQUE APPROACH FOR CORDOTOMY OR FOR CERVICAL DISC EXCISION

JOHN S. COLLIS, JR., M.D.

*Department of Neurologic Surgery*

**C**ORDOTOMY or cervical disc excision may be accomplished through the currently standard incision or through a new oblique approach (*Fig. 1*).



**Fig. 1.** Sketch showing the currently standard approach and the new oblique approach to the spinal canal. The oblique approach affords greater accessibility to the disc, the spinal nerves, and the spinal cord.

This paper discusses the new method, which is believed to be reported for the first time.

The oblique approach is simple and safe. It offers a minimum of surgical trauma

to all tissues encountered. Only a small incision is necessary, yet optimum exposure is provided either for cordotomy or for disc excision.

### Technic

The technic for the oblique approach consists of a small paramedian opening made directly over an interlaminar space, rather than a larger midline incision followed by a subperiosteal dissection and lateral retraction for the same exposure.

The essential steps of the oblique approach follow.

1. General endotracheal anesthesia is administered, and the patient is positioned, prone or sitting. If disc excision is to be performed, precise localization of the incisional site is necessary, and the first of two lateral cervical roentgenograms is made. For cordotomy, roentgenographic localization is not necessary.

2. A small paramedian incision is made directly over the desired interspace, from 2 to 5 cm. to the right or left of the midline. The larger the neck, the farther the incision is made from the midline.

3. The paramedian incision is deepened, in a slightly medial direction, until the laminae and an interspace are reached. All tissues encountered are divided in the same plane. Hemostasis is promptly achieved with a suction-cautery apparatus. (If disc excision is to be performed, a radiopaque marker is inserted at the interspace, and the second lateral cervical roentgenogram is made; in accordance with roentgenographic localization the incision is then enlarged or centered.) The walls of the incision are then spread apart and are thus maintained with a self-retaining retractor having adjustable blades of appropriate length.

4. A small bony opening is made just medial to the facets by removing adjacent bits of laminae with a narrow, angled rongeur. (A 3-mm. 40-degree-angled bone punch is ideal, although a dental drill, or other instrument may be used.)

5. The ligamentum flavum thus exposed is removed.

6. The epidural vessels may then be elevated and electrocoagulated if necessary.

7. a. If cordotomy is to be performed, the dura is opened by a longitudinal incision, and the edges are retracted by two silk sutures anchored in the lateral muscle walls. No rotation of the spinal cord is necessary for the actual cordotomy, since the lateral aspect of the cord is seen when the dura is opened.

- b. If disc excision is to be performed, the currently routine method is used.

8. The incision is closed with interrupted sutures of black silk.

### Comment

The oblique approach can be used for cordotomy or for unilateral cervical disc excision. Cordotomy may be performed in the cervical or thoracic regions. If *bilateral* cordotomy is to be performed, then two separate oblique approaches are made.

The oblique approach is simple, safe, and offers minimum surgical trauma to all tissues encountered. The incision is small, yet optimum exposure is provided for either cordotomy or disc excision. The bony opening is small and the facets are not damaged. Epidural bleeding is either avoided or easily controlled. No rotation of the spinal cord is needed for cordotomy since the lateral aspect of the cord is viewed when the dura is opened. Manipulation of the nerve roots for disc exposure is kept at a minimum. The small incision is closed easily and efficiently. Postoperative discomfort is significantly lessened.

Roentgenographic localization is needed in cases of disc excision; this is not necessary for cordotomy.

The spinal accessory nerve may be injured if a transverse skin incision is used for a high cervical opening. Damage to the accessory nerve however, has not occurred in a series of more than 50 operations in four years.

Lumbar disc excisions have been performed by the oblique approach at the Cleveland Clinic Hospital on several occasions. The only advantage over the usual lumbar approach is the improved surgical accessibility to midline lumbar herniations.

In cases in which lengthening of the incision might be necessary, such as when a neoplasm is present, the usual posterior approach is preferable. The possibility of finding an unsuspected tumor instead of a disc herniation, can be eliminated by confirming equivocal myelographic findings with cervical discography.

### Summary

An apparently new surgical technic—an oblique approach to the spinal canal—is described. This approach for cordotomy or for cervical disc excision has several advantages over the currently standard, midline incision.