

## NECROTIZING ANGIITIS: II. FINDINGS AT AUTOPSY IN TWENTY-SEVEN CASES

HOWARD E. REIDBORD, M.D.,\* LAWRENCE J. MCCORMACK, M.D.,

*Division of Pathology*

and

JOHN D. O'DUFFY, M.B.

*Department of Rheumatic Disease*

IN the study of inflammatory lesions of blood vessels, some basic problems have remained unsolved since Rokitansky first described the gross pathologic features of the lesions in 1852 (cited by Zeek<sup>1</sup>). Widely varying views are held on the classification of this group of disorders in spite of the extensive literature on the subject. The differentiation of polyarteritis nodosa from the vascular lesions designated by Zeek and associates<sup>2</sup> as hypersensitivity angiitis has stimulated many of the recent studies. Some authors<sup>2-4</sup> clearly distinguish polyarteritis nodosa from hypersensitivity angiitis, while others<sup>5, 6</sup> do not. Nosology of the significant vascular changes found in Wegener's granulomatosis,<sup>7</sup> allergic granulomatosis,<sup>8</sup> and a variety of less well defined generalized vascular diseases<sup>9, 10</sup> is also controversial.

Experimental data have failed to elucidate clearly the basic mechanisms in this perplexing disease group, and the morphologic examination of material from human beings remains a significant method of study. With these considerations in mind it was believed that a review of the autopsy findings in cases of these disorders would be valuable. From a review of the records of all autopsies performed here between 1942 and 1964, 27 cases of necrotizing angiitis were selected. The series of 27 cases was divided into three types: (1) polyarteritis nodosa, (2) hypersensitivity angiitis, and (3) Wegener's granulomatosis. The term 'necrotizing angiitis' is used to suggest that the fundamental process is vascular and not secondary to disease of other organ systems.

We have previously reported the clinical features of this group of cases.<sup>11</sup>

### Materials and Methods

The series is comprised of 27 cases of necrotizing angiitis observed at autopsy between January 1, 1942, and December 31, 1963. Cases showing the arteriolar changes of malignant hypertension which is considered not to be a primary vasculitis,<sup>12</sup> were excluded from the series. For microscopic examination, elastic tissue, phosphotungstic acid hematoxylin, and Mallory-Heidenhain stains were used in many instances. All vascular lesions were graded on the scale, 1+ to 4+, of increasing severity using the following criteria: (1) nature of the cellular infiltrate,

\*Formerly Fellow in the Division of Pathology; present address: Armed Forces Institute of Pathology, Washington, D. C. 20305.

i.e., polymorphonuclear leukocytes, monocytes, lymphocytes, fibroblasts, or eosinophils; (2) fibrin ('fibrinoid') deposition and necrosis; (3) giant cells; (4) fragmentation of nuclei (nuclear dust); and (5) thrombosis. Aneurysm formation, venous involvement, perivascular granulomas, and the layer of the vessel wall disturbed were also graded. The age of the lesion was designated as acute, healing, or healed. Vessels were classified as arterioles, small arteries (diameter from 0.1 to 0.5 mm.), medium arteries (from 0.5 mm. to 1.0 mm.), and large arteries (over 1.0 mm.).

## Results

### Findings at Autopsy

*Polyarteritis nodosa.* Twelve cases were included in the group designated as polyarteritis nodosa. Gross findings at autopsy were not highly suggestive of arteritis although in one case the coronary artery had nodularities from 0.1 to 0.4 cm. in diameter. In the 11 remaining cases the autopsy protocols contained no reference to nodularities of the vessels. The results of occlusive vascular disease were grossly evident in each of six cases as follows: (1) infarction of jejunum, (2) focal necrosis of the left lobe of the liver, (3) cerebral and splenic infarcts, (4) renal and pancreatic infarcts, (5) ileal perforation, and (6) infarction of pancreas and kidney. The infarctions of the solid viscera were small, wedge-shaped, and otherwise characteristic of ischemic necrosis.

Pericarditis was present in 4 of the 12 cases, hemopericardium in 1 case, and pleural effusions in 2 cases. Uremic pneumonitis was present in 2 cases.

Microscopic examination revealed vascular involvement of the various organs as shown in *Table 1*. The most distinctive microscopic feature of this group (observed in all 12 cases) was the presence of arterial lesions of varying ages at the time of autopsy; arterioles and veins were not disturbed. Healed arteritis was found in many sections adjacent to an acute actively necrotizing lesion. The medium and small muscular arteries were most frequently diseased. Branches of the renal and coronary arteries were the only large arteries involved (in one case the coronary artery became occluded, resulting in the patient's death). Angiitis of the respiratory vasculature was not seen. The occurrence of acute and healed vasculitis in the various organs is summarized in *Table 2*.

Necrosis with fibrinous exudation was present in 11 of the 12 cases. The fibrinous material was found most often in the media where it was characterized as basophilic to eosinophilic amorphous material, most often segmental in the vessel but occasionally circumferential (*Fig. 1*). In some cases the necrosis was prominent subintimally, the vessel's lumen being reduced in size with endothelial proliferations and focal fibrosis. Elastic tissue stains showed complete loss or focal segmental loss of the external and in many cases internal elastic lamina in the areas corresponding to the acute inflammation. Nuclear fragmentation was prominent in many cases. All vascular necrosis was accompanied by cellular infiltration and varying

# NECROTIZING ANGIITIS. II.

**Table 1.**—*Vascular involvement of the organs in 12 cases of polyarteritis nodosa and in 11 cases of hypersensitivity angiitis*

Organ	Polyarteritis nodosa*	Hypersensitivity angiitis*
Heart	5/10	2/11
Lungs	0/12	4/11
Coronary artery	2/3	0/11
Aorta	0/3	—
Spleen	4/11	2/11
Lymph node	1/4	0/6
Esophagus	—	0/2
Stomach	3/5	1/4
Small bowel	3/5	1/4
Large bowel	2/5	4/4
Liver	5/11	1/11
Gallbladder	3/3	1/3
Pancreas	8/11	3/11
Kidneys	11/11	10/10
Urinary bladder	2/4	3/5
Testes	2/5	2/4
Prostate	1/5	1/5
Adrenals	11/12	7/10
Thyroid	0/8	0/7
Pituitary	1/4	0/6
Brain	3/5	2/5
Nerves	4/5	1/2
Muscles	5/7	2/4
Skin	1/6	0/2
Breast	0/1	0/2
Uterus	—	1/2
Ovary	—	2/3
Bone marrow	0/11	0/8

\*Number of cases with involvement/number of cases examined.

amounts of nuclear dust, that is, small dark irregular fragments of deeply basophilic material. The presence of necrosis was associated with polymorphonuclear infiltration, mononuclear cells, and lymphocytes. Occasional plasma cells and infrequent eosinophils were noted. As the infiltrate became more chronic, fibroblasts and histiocytes replaced the fibrinous areas and were frequently arranged in a radial fashion. Laminated circumferential collagen fibers were noted in the media and

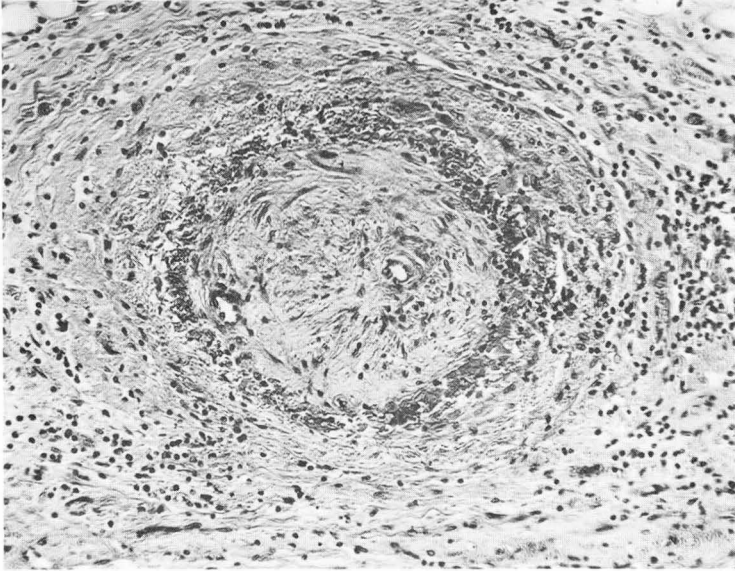
Table 2.—The occurrence of acute and healed vasculitis in 12 cases of *polyarteritis nodosa*

Organ	Acute only	Healed only	Both
	N u m b e r o f c a s e s		
Heart	4	—	1
Coronary artery	1	1	—
Spleen	2	1	1
Lymph nodes	1	—	—
Stomach	1	—	2
Small bowel	1	1	1
Large bowel	2	—	—
Liver	2	2	1
Gallbladder	—	2	1
Pancreas	4	2	2
Kidney	4	4	3
Urinary bladder	—	—	2
Testes	2	—	—
Prostate	1	—	—
Adrenal	3	4	4
Pituitary	—	1	—
Brain	2	1	—
Nerve	1	2	2
Muscle	3	1	1
Skin	1	—	—

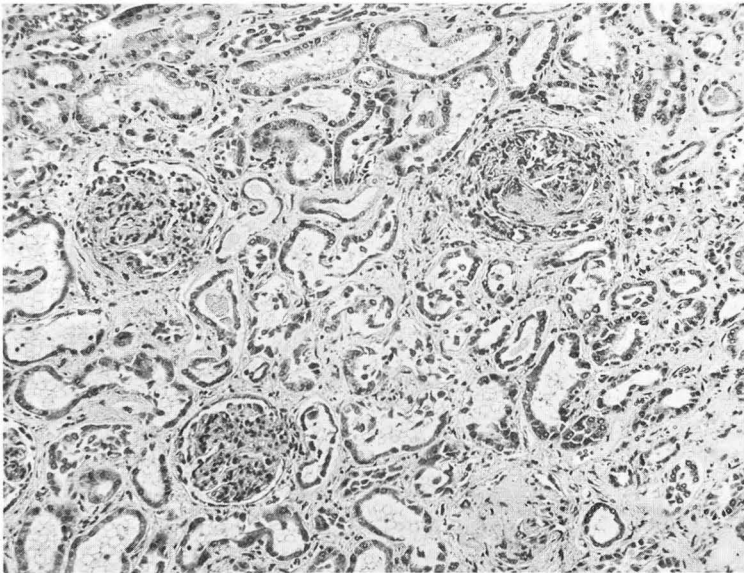
adventitia, and fibrosis was observed in all layers. Vascular occlusion when seen in acute lesions was due to a combination of subintimal necrosis, endothelial hyperplasia, and thrombosis; however, in most instances of the healed phase of the disease the lumen was reduced to a small eccentric endothelial-lined channel with extreme fibroplasia of the subintimal tissue.

The significant changes in all organs could be directly attributed to vascular occlusion; however, the additional changes in the kidney deserve mention. A membranoproliferative glomerulonephritis was present in one case (*Fig. 2*), focal membranous glomerulopathy in one, and hemoglobinuric nephrosis in one.

*Hypersensitivity angitis.* Gross autopsy findings in the 11 cases included in this group were surprisingly unremarkable with little overt evidence of vasculitis. A pericarditis was present in 3 of the 11 cases. Abnormalities of the kidneys were found however. Their surfaces were congested with mottled red and yellow areas of vague outline. Cross section revealed glomeruli as minute, bright red dots. The



**Fig. 1.** Healing vasculitis of a medium-sized artery from muscle in a case of polyarteritis nodosa. Proliferation of fibrous tissue is predominantly subintimal. Note necrosis in the media. Hematoxylin-eosin stain; magnification X160.

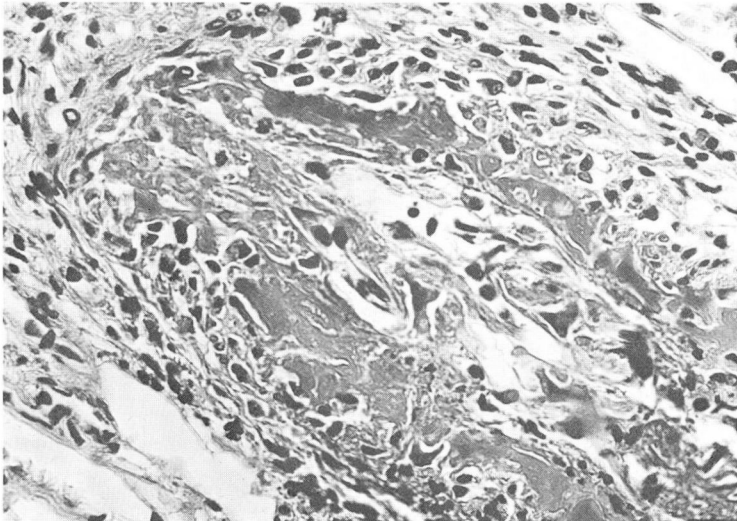


**Fig. 2.** Membranoproliferative glomerulonephritis in polyarteritis nodosa. Hematoxylin-eosin stain; magnification X110.



medullary areas appeared congested. One case was distinctive in that the cortex presented the pattern of cortical necrosis.

The arterial supplies of various organs showed microscopic changes with variable frequency (*Table 1*). Those of the kidneys were damaged in all cases examined. The adrenal arteries were involved in 7 of 10 cases, and the lungs in 4 of 11 cases. The arteries of large bowel and urinary bladder were commonly involved; the vessels of the remaining viscera were only occasionally distorted. The vascular lesions seemed to be acute as indicated by a definite polymorphonuclear infiltrate and considerable necrosis. Necrosis was characterized by amorphous eosinophilic and basophilic material found subintimally and less frequently in the media (*Fig. 3*).



**Fig. 3.** Definite subintimal fibrin (necrosis?) in small artery with endothelial proliferation partially occluding lumen. This lesion is characteristic of hypersensitivity angiitis. Hematoxylin-eosin stain; magnification X430.

Vascular occlusions were most frequently seen in the kidneys and the adrenal glands. In these instances, the vessel appeared to be occluded with eosinophilic fibrin-like strands with intermeshed red and white blood cells. Some small arteries and arterioles were completely thrombosed with eosinophilic amorphous plugs of material (*Fig. 3*). Occasional areas of lymphocytic infiltrate were observed but generally the inflammation was not prominent in the venous system. Eosinophils were not a prominent feature in any of the cases. Involvement of large vessels, aneurysmal dilatation of vessels, healed lesions, and significant infarction were not present.

Of particular interest is the common distortion of the renal glomeruli in this group. The changes are those of glomerulonephritis, varying from the membranoproliferative to the sclerosing type. Focal necrotizing glomerulitis was seen in four cases (*Fig. 4*).

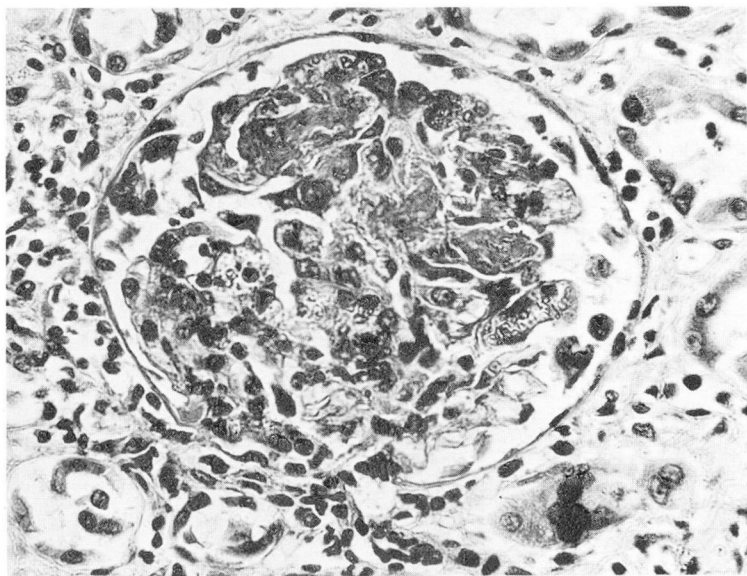


Fig. 4. Focal necrotizing glomerulonephritis in hypersensitivity angiitis. This lesion was not found in our cases of polyarteritis nodosa. Hematoxylin-eosin stain; magnification X430.

Two cases are worthy of special mention: one, reported previously,<sup>13</sup> with retroperitoneal fibrosis and partial ureteral obstruction in combination with the generalized necrotizing vasculitis, and one with bilateral renal cortical infarcts due to numerous small vascular thrombi.

*Wegener's granulomatosis.* This group comprises four cases with necrotizing lung lesions histologically related to a vasculitis and/or upper respiratory ulcerations, extrapulmonary vasculitis, and nephritis. At autopsy the findings in all four cases were similar, the lungs were noted to be involved with widespread consolidation in all and with ulceration of the trachea in one. The kidneys resembled those found in cases of hypersensitivity angiitis. No other significant gross findings were noted.

Microscopically, a severe necrotizing pneumonitis with granuloma formation was uniformly present, as well as a severe pulmonary vasculitis (Fig. 5). The vessels disturbed were arteries, medium to large size; the changes consisted of necrosis, giant cells, and marked inflammation of all coats of the vessel wall either segmental or circumferential; the arteries appeared to be centered in the areas of severe necrosis. Special stains and pulmonary cultures for fungi and acid-fast organisms were all negative.

The kidneys in all cases showed severe disease with necrotizing and proliferative glomerulonephritis, focal necrotizing glomerulonephritis, and sclerosing glomerulonephritis, with active membranoproliferative areas.

The extrapulmonary necrotizing vasculitis, also present in all cases, affected small arteries and arterioles with no venous component. Organs involved were:



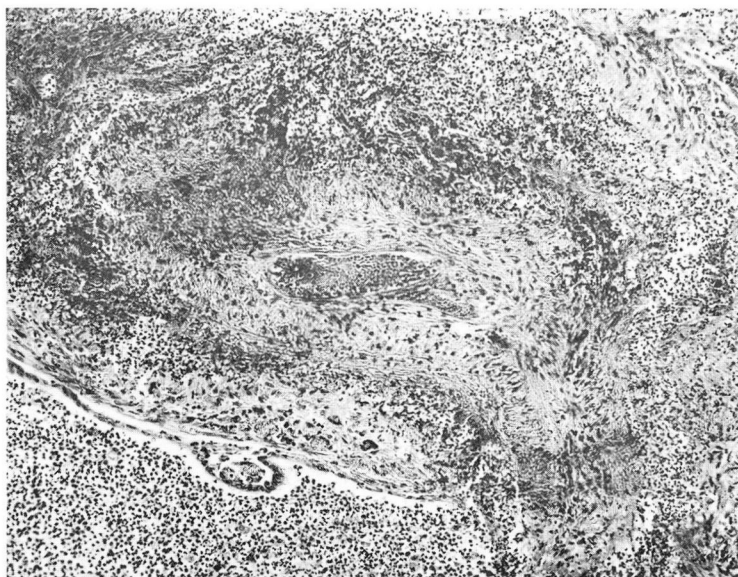

Fig. 5. Acute arteritis in lung characteristic of Wegener's granulomatosis. Perivascular granulation tissue and inflammatory cells are prominent. Hematoxylin-eosin stain; magnification X100.

spleen in three cases, skin, adrenal, and small bowel in one case each. The vascular lesions were microscopically identical to those in the group with hypersensitivity angiitis.

#### Antemortem Biopsy

*Results of antemortem biopsies* (Table 3). Histologic evidence of necrotizing vasculitis was present in only one case before death: that of Wegener's granulomatosis in which a skin biopsy was obtained three days before death. In none of the remaining cases in this series was a histologic diagnosis of vasculitis obtained although it was clinically suspected in almost all cases. Biopsies of the kidneys in one case of polyarteritis nodosa and in one case of necrotizing angiitis showed glomerulonephritis but no vascular change and hence were of no aid in diagnosing an angiitis. Five muscle biopsies were all normal.

#### Discussion

Zeek's<sup>2</sup> widely quoted classification of necrotizing angiitis is well known to students of vascular pathology. Important features stressed are: (1) the character of the early preexudative lesions, (2) their distribution in relation to the bifurcation of the vessels, (3) the size and type of vessel primarily affected, and (4) the presence or absence of lesions of the splenic follicles and pulmonary arteries. The usual division is generally into two major groups: (1) polyarteritis nodosa, and (2) hyper-



sensitivity angitis. Most valuable in differentiation are the frequent involvement of renal glomeruli and the significant changes in pulmonary vessels in hypersensitivity angitis; pulmonary arterial involvement is rare in polyarteritis nodosa. In Zeek's<sup>2</sup> original cases of hypersensitivity angitis, necrotizing and exudative glomerulonephritis was present in all, in contrast to cases of polyarteritis in which only proliferative glomerulonephritis was occasionally present. Despite the apparently clear-cut division it should be stressed that 9 of Zeek's 31 cases were not classified as either polyarteritis nodosa or hypersensitivity angitis but were considered unclassifiable into either of these groups alone. A subsequent publication<sup>1</sup> has extended the classification into five types of necrotizing angitis: (1) hypersensitivity angitis, (2) allergic granulomatous angitis, (3) rheumatic arteritis, (4) polyarteritis nodosa, and (5) temporal arteritis. Definite differentiation of polyarteritis nodosa from hypersensitivity angitis is stressed by the work of Blankenhorn and Knowles<sup>3</sup>

Table 3.—*Biopsies antemortem*

Disease, and site of biopsy	No. of cases biopsied*	Vasculitis	Comment
Polyarteritis nodosa			
Muscle	3	None	One case showed perivascular lymphocytes
Skin	2	None	
Kidney	1	None	Glomerulonephritis, membranoproliferative
Liver	1	None	
Hypersensitivity angitis			
Muscle	1	None	
Kidney	1	None	Glomerulonephritis, necrotizing and membranoproliferative
Liver	2	None	
Lung	1	None	Partial pneumonectomy for granuloma 4 months before death
Wegener's granulomatosis			
Muscle	1	None	
Skin	1	Yes	Biopsy 3 days before death
Lung	1	None	Chronic granulomatous inflammation, etiology undetermined

\*All biopsies were made one month or less before death except as noted in comment.

and Moscovitz, Baggenstoss, and Slocumb.<sup>14</sup> Rose and Spencer,<sup>5</sup> however, in a study of 111 histologically proved cases of necrotizing angitis found that hypersensitivity angitis could not be clearly distinguished from polyarteritis nodosa. McCombs<sup>4</sup> offers a classification more elaborate than that of Zeek, and a recent review of the literature offers still another classification.<sup>15</sup> As far as we can ascertain, the acute vascular lesion is totally nonspecific and separation of the various proposed entities at best is difficult and requires much correlation.

The criteria that we use for diagnosis of polyarteritis nodosa are those of Zeek.<sup>12</sup> Of the various pathologic characteristics that can be used finally to distinguish polyarteritis nodosa from the other entities, the presence of healed lesions is the most helpful. Although vascular lesions are described as often being grossly visible in polyarteritis,<sup>15, 16</sup> they were observed in only 1 of our 12 cases. In a review of 30 cases of arteritis, Patalano and Sommers<sup>6</sup> stated that one third showed no grossly evident arterial changes.

The 11 cases of hypersensitivity angitis included in this report conform to Zeek's criteria.<sup>1</sup> In agreement with the findings of many other observers, pulmonary vascular disease was not observed in our cases of polyarteritis nodosa whereas it was present in 4 of 11 cases of hypersensitivity angitis.

Involvement of the kidneys in polyarteritis nodosa is mainly vascular with glomerulonephritis present in only 3 of 12 cases; these three showed neither necrosis nor exudative change. Significant glomerulonephritis occurred in all 11 cases of hypersensitivity angitis, with focal necrosis of glomeruli in four cases. This is in accordance with the findings of Zeek,<sup>2</sup> who reported that of 15 cases of polyarteritis 3 had diffuse glomerulonephritis but none had necrotizing glomerulonephritis. Rose and Spencer<sup>5</sup> found approximately twice the incidence of glomerulitis in the "periarteritis nodosa with lung involvement group" than in their group "without lung involvement." Distinction should be made between ischemic infarction of the glomeruli seen in polyarteritis nodosa, and focal necrotizing glomerulitis associated with hypersensitivity angitis, in that the latter is characterized by focal necrosis and not loss of entire glomerular structure. Rose<sup>17</sup> found in a study of 54 necropsied cases of polyarteritis without lung involvement that 39 showed only arterial lesions in the kidneys (we have excluded such cases from the present series). It appears that focal necrosis of glomeruli in combination with a vasculitis occurs considerably more often in the hypersensitivity type of angitis than in polyarteritis nodosa; a similar conclusion was reached by Moskowitz and associates<sup>14</sup> in their study of 56 necropsied cases of vasculitis.

In 4 of our 11 cases of polyarteritis nodosa, the splenic arteries were diseased, a finding not reported by Zeek<sup>1</sup> in her series. Vascular disease in the gastrointestinal tract was similar in both diseases in our series.

Microscopic differentiation of primary vasculitis on the basis of examination of a single vessel as in a muscle or skin biopsy is difficult. Fragmentation of nuclei

(nuclear dust) has been suggested as indicating hypersensitivity angiitis,<sup>18</sup> but it was of no diagnostic value in our series. Radiating fibroblastic proliferation in the vascular wall observed in the early necrotizing lesions of polyarteritis nodosa<sup>2</sup> was not seen in our cases of hypersensitivity angiitis.

The findings in one of our cases suggested in part a 'healed' state of polyarteritis nodosa and resembled those in a case reported by Whiteley and Wilson.<sup>9</sup> These authors described an interesting example of intimal fibroplasia resulting in vascular occlusion. Their case was similar to ours morphologically in that intimal proliferation with reduction in luminal size was a predominant feature; however, the presence of fibrin and inflammatory infiltrate in our case prompted us to classify it as healing polyarteritis nodosa. The relation of this disorder to intimal fibroplasia of the renal arteries<sup>19</sup> and to diffuse thromboangiitis obliterans is of an entirely speculative nature.

Our cases classified as Wegener's granulomatosis morphologically fulfill the criteria set in the literature.<sup>7, 20, 21</sup> Most characteristic are the granulomatous lung lesions that were unquestionably associated with vasculitis. Without this peculiar inflammatory reaction a secondary necrotizing pneumonitis in cases of hypersensitivity angiitis or polyarteritis nodosa would be difficult to differentiate from Wegener's granulomatosis. The extrapulmonary vasculitis of Wegener's disease is similar to that of hypersensitivity angiitis with a predilection for small vessels. The kidney changes were indistinguishable from those in hypersensitivity angiitis, with a definite focal necrotizing glomerulonephritis the predominant lesion.

Etiologic considerations concerning necrotizing vasculitis have dealt mainly with discussions of hypersensitivity,<sup>22, 23</sup> bacterial infection of toxins,<sup>24</sup> and drugs.<sup>25</sup> Patterns of vascular disease can be produced in the experimental animal by manipulation of renal hypertension and renal insufficiency,<sup>26</sup> that are significantly different from those produced by the injections of foreign serum protein.<sup>27</sup> Although lesions identical to those in polyarteritis nodosa can be produced by increasing blood pressure in a rat,<sup>28, 29</sup> this development may be a species-specific reaction not applicable to human disease. No relationship was found between severe hypertension and arterial lesions in rabbits, but rather other factors were suggested as causing the lesions.<sup>30</sup> Although many observers suggest a causal relation between hypertension and vascular disease, not all patients with polyarteritis nodosa or hypersensitivity angiitis have hypertension.<sup>14</sup>

The possibility that antigen-antibody reaction plays a role in the pathogenesis of necrotizing vasculitis is supported by the occurrence of morphologic alteration of the vessel wall in immune reactions. Early localization of the antigen beneath the endothelium with subsequent vascular necrosis in the Arthus phenomenon is similar to the mechanism of vascular necrosis in cases of necrotizing vasculitis, and has experimental validation in the arteritis studied by Mellors and Ortega.<sup>31</sup> In hypersensitivity reactions the formation of fibrin from antigen-antibody action on platelets has been suggested,<sup>32</sup> and resultant fibrin deposition on vascular walls

could occur altering vascular permeability. Subendothelial fibrin would then appear as seen in hypersensitivity angitis. Similar endothelial fibrin deposition is noted in the vessels of transplanted kidneys in early rejection and suggests a host response to foreign protein.<sup>33, 34</sup> Definite subintimal proliferation with luminal narrowing is noted in vessels of transplanted kidneys at a later stage of rejection<sup>35</sup> and sometimes resembles the healed lesions in polyarteritis nodosa. Hypersensitivity angitis and polyarteritis nodosa may be the vascular response to antigen-antibody complexes with differing manifestations, somewhat analogous to the vascular changes observed in the rejection phenomenon of kidney transplantation.<sup>36</sup>

The nature of the antigen in this postulated reaction is, of course, unknown. The remarkable vasculitis in Aleutian mink disease<sup>36</sup> which can be transmitted successfully between animals, raises the possibility of a viral etiology in necrotizing angitis in the human being; Zeek<sup>1</sup> cites evidence that a lesion epidemic in deer closely resembles polyarteritis nodosa in human beings even to the absence of lung involvement.

The value of biopsy in the diagnosis of generalized vasculitis is dealt with more fully elsewhere.<sup>37</sup> The failure to obtain a definitive antemortem tissue diagnosis in this group of disorders is not unusual and reflects the focal nature of the vascular involvement.<sup>1, 6</sup>

### Summary

A review of all autopsies between 1942 and 1964 at the Cleveland Clinic Hospital resulted in the selection of 27 cases designated as necrotizing angitis. These were divided into three types: polyarteritis nodosa, comprising 12 cases; hypersensitivity angitis, 11 cases; and Wegener's granulomatosis, 4 cases. Gross and microscopic examination allowed separation of polyarteritis nodosa from hypersensitivity angitis mainly on the basis of the following characteristics of the latter disease: lack of involvement of large vessels, absence of healing lesions, and presence of severe renal disease. Wegener's granulomatosis was characterized by the peculiar granulomatous reaction related to the vasculitis in the lungs.

### References

1. Zeek, P. M.: Periarthritis nodosa: critical review. *Am. J. Clin. Path.* 22: 777-790, 1952.
2. Zeek, P. M.; Smith, C. C., and Weeter, J. C.: Studies on periarthritis nodosa; differentiation between vascular lesions of periarthritis nodosa and of hypersensitivity. *Am. J. Path.* 24: 889-917, 1948.
3. Blankenhorn, M. A., and Knowles, H. C., Jr.: Periarthritis nodosa: recognition and clinical symptoms. *Ann. Int. Med.* 41: 887-892, 1954.
4. McCombs, R. P.: Periarthritis Nodosa and Related Disorders of Blood Vessels, p. 1-31. *In* Disease-a-Month, The Yearbook Publishers, Chicago, August 1960.
5. Rose, G. A., and Spencer, H.: Polyarteritis nodosa. *Quart. J. Med.* 26: 43-81, 1957.



6. Patalano, V. J., and Sommers, S. C.: Biopsy diagnosis of periarteritis nodosa. Glomerulonephritis and renal arteriolitis as aids. *Arch. Path.* **72**: 1-7, 1961.
7. Godman, G. C., and Churg, J.: Wegener's granulomatosis; pathology and review of literature. *A.M.A. Arch. Path.* **58**: 533-553, 1954.
8. Churg, J., and Strauss, L.: Allergic granulomatosis, allergic angiitis and periarteritis nodosa. *Am. J. Path.* **27**: 277-301, 1951.
9. Whiteley, H. J., and Wilson, G. M.: Widespread intimal proliferation of arteries, with resulting thrombosis. *J. Path. & Bact.* **64**: 705-714, 1951.
10. Fisher, E. R., and Hellstrom, H. R.: Cogan's syndrome and systemic vascular disease. Analysis of pathologic features with reference to its relationship to thromboangiitis obliterans (Buerger). *Arch. Path.* **72**: 572-592, 1961.
11. O'Duffy, J. D.; Scherbel, A. L.; Reidbord, H. E., and McCormack, L. J.: Necrotizing angiitis: I. Clinical review of twenty-seven autopsied cases. *Cleveland Clin. Quart.* **32**: 87-98, 1965.
12. Zeek, P. M.: Medical progress: periarteritis nodosa and other forms of necrotizing angiitis. *New England J. Med.* **248**: 764-772, 1953.
13. Reidbord, H. E., and Hawk, W. A.: Idiopathic retroperitoneal fibrosis and necrotizing vasculitis. Report of case, with autopsy findings and etiologic consideration. *Cleveland Clin. Quart.* **32**: 19-27, 1965.
14. Moskowitz, R. W.; Baggenstoss, A. H., and Slocumb, C. H.: Histopathologic classification of periarteritis nodosa; study of 56 cases confirmed on necropsy. *Proc. Mayo Clin.* **38**: 345-357, 1963.
15. Alarcón-Segovia, D., and Brown, A. L., Jr.: Classification and etiologic aspects of necrotizing angitiides: analytic approach to confused subject with critical review of evidence for hypersensitivity in polyarteritis nodosa. *Proc. Mayo Clin.* **39**: 205-222, 1964.
16. Arkin, A.: Clinical and pathological study of periarteritis nodosa. Report of five cases, one histologically healed. *Am. J. Path.* **6**: 401-426, 1930.
17. Rose, G. A.: Natural history of polyarteritis. *Brit. M. J.* **2**: 1148-1152, 1957.
18. Winkelman, R. K., and Ditto, W. B.: Cutaneous and visceral syndromes of necrotizing or "allergic" angiitis; study of 38 cases. *Medicine* **43**: 59-89, 1964.
19. McCormack, L. J.: Vascular changes in hypertension. *M. Clin. North America* **45**: 247-257, 1961.
20. Fahey, J. L.; Leonard, E.; Churg, J., and Godman, G. C.: Wegener's granulomatosis. *Am. J. Med.* **17**: 168-179, 1954.
21. Anderson, W. A. D.: *Synopsis of Pathology*, 6th ed. St. Louis: C. V. Mosby & Co., 1964, 883 p.; p. 419-420.
22. Rich, A. R.: Role of hypersensitivity in periarteritis nodosa as indicated by 7 cases developing during serum sickness and sulfonamide therapy. *Bull. Johns Hopkins Hosp.* **71**: 123-140, 1942.
23. Rich, A. R., and Gregory, J. E.: Experimental demonstration that periarteritis nodosa is manifestation of hypersensitivity. *Bull. Johns Hopkins Hosp.* **72**: 65-88, 1943.
24. McCall, M., and Pennock, J. W.: Disseminated necrotizing vascularitis—toxic origin of periarteritis nodosa. *Am. J. M. Sc.* **206**: 652-659, 1943.

25. Symmers, W. S.: Occurrence of angitis and of other generalized diseases of connective tissues as consequence of administration of drugs. *Proc. Roy. Soc. Med.* 55: 20-28, 1962.
26. McGill, H. C., Jr.; Geer, J. C.; Strong, J. P., and Holman, R. L.: Two forms of necrotizing arteritis in dogs related to diet and renal insufficiency. *A.M.A. Arch. Path.* 65: 66-76, 1958.
27. Campbell, W. G., Jr., and Santos-Buch, C. A.: Widely distributed necrotizing arteritis induced in rabbits by experimental renal alterations. I. Comparison with vascular lesions induced by injections of foreign serum. *Am. J. Path.* 35: 439-465, 1959.
28. Masson, G. M.; McCormack, L. J.; Dustan, H. P., and Corcoran, A. C.: Hypertensive vascular disease as consequence of increased arterial pressure; quantitative study in rats with hydralazine-treated renal hypertension. *Am. J. Path.* 34: 817-833, 1958.
29. Smith, C. C., and Zeek, P. M.: Studies on periarteritis nodosa; role of various factors in etiology of periarteritis in experimental animals. *Am. J. Path.* 23: 148-157, 1947.
30. Campbell, W. G., Jr., and Santos-Buch, C. A.: Widely distributed necrotizing arteritis induced in rabbits by experimental renal alterations. III. Studies on activity and decay of necrotizing factors. *Am. J. Path.* 43: 131-141, 1963.
31. Mellors, R. C., and Ortega, L. G.: Analytical pathology; new observations on pathogenesis of glomerulonephritis, lipid nephrosis, periarteritis nodosa, and secondary amyloidosis in man. *Am. J. Path.* 32: 455-499, 1956.
32. Vassalli, P.; Simon, G., and Rouiller, C.: Electron microscopic study of glomerular lesions resulting from intravascular fibrin formation. *Am. J. Path.* 43: 578-617, 1963.
33. Hazard, J. B.: Personal communication, June 1965.
34. Porter, K. A.; Thomson, W. B.; Owen, K.; Kenyon, J. R.; Mowbray, J. F., and Peart, W. S.: Obliterative vascular changes in four human kidney homotransplants. *Brit. M. J.* 5358: 639-645, 1963.
35. Altman, B.: Tissue transplantation: circulating antibody in homotransplantation of kidney and skin. *Ann. Roy. Coll. Surg. England* 33: 79-104, 1963.
36. Leader, R. W.; Wagner, B. M.; Henson, J. B., and Gorham, J. R.: Structural and histochemical observations of liver and kidney in Aleutian disease of mink. *Am. J. Path.* 43: 33-53, 1963.
37. Reidbord, H. E.; Scherbel, A. L.; O'Duffy, J. D., and McCormack, L. J.: Necrotizing angitis: III. Correlation of clinical findings with biopsy evidence in thirty-one patients. In preparation.