

OSTEOPOROSIS RESULTING FROM HEPARIN THERAPY

REPORT OF A CASE

WILLIAM E. MILLER, M.D.,* and VICTOR G. DEWOLFE, M.D.

Department of Peripheral Vascular Disease

SODIUM heparin has gained widespread acceptance as a safe, effective anticoagulant. Complications, consisting mainly of bleeding phenomena, can be quickly and effectively treated with intravenous injections of protamine sulfate. Recently a syndrome of osteoporosis with multiple fractures due to long-term heparinization was reported.^{1, 2} The following case is an example of this syndrome occurring in a patient on relatively short-term but intensive heparin therapy.

REPORT OF A CASE

A 52-year-old white man, a factory worker, was first examined at the Cleveland Clinic Hospital in July, 1959, because of arteriosclerosis obliterans of the right femoral and popliteal arteries. A right femoropopliteal bypass dacron graft was implanted on July 17, 1959; full restoration of pulses ensued, and the patient was discharged from the hospital much improved.

On May 1, 1962, after an acute thrombosis in the graft, the patient underwent reoperation and a second femoropopliteal dacron graft was inserted in association with a right lumbar sympathectomy. A plain roentgenogram of the abdomen preoperatively showed a normal lumbosacral spine (*Fig. 1A*). Postoperatively, because of poor runoff, he received heparin sodium solution, 50 mg. subcutaneously every six hours. On May 8 this dosage was increased to 400 mg. of concentrated aqueous heparin injected subcutaneously once daily. Subsequently he was discharged from the hospital with instructions to administer this dosage of heparin daily at home.

About four months later, on September 20, 1962, the patient while lifting a heavy object experienced sharp, nonradiating pain in the lumbosacral area. Despite topical treatment with heat and mild analgesics, the pain persisted and, in November, 1962, the patient was admitted to a local hospital.

Roentgenograms of the spine were reported as showing "collapsed vertebrae and osteoporosis." Therapy with traction and the use of a back brace resulted only in minimal relief. In January, 1963, he entered the Cleveland Clinic Hospital for further treatment.

Physical examination on admission to the hospital was normal except for local tenderness over the lumbar spine. The right femoropopliteal graft was functioning well.

Laboratory studies revealed normal hemogram, urine, serum protein electrophoretic pattern, Addis count, blood urea, serum creatinine, serum carotene and serum xylose determinations. Bence Jones protein was not present in the urine. Repeated serum calcium determinations were between 9.5 mg. and 11.5 mg. per 100 ml. (normal for this laboratory is 9 mg. to 11 mg. per 100 ml.). Serum phosphorus levels ranged from 2.8 mg. to 4.8 mg. per 100 ml. (normal, 2.0 mg. to 3.5 mg. per 100 ml.). Three alkaline phosphatase determinations were normal. Calcium and phosphorus infusion tests also were normal.

Roentgenograms of the thoracic and lumbar spine (*Fig. 1B and C*), taken on the day of admission to the hospital, were interpreted as indicating generalized demineralization with compression fractures of the sixth and eighth thoracic vertebrae. Roentgenograms of the

*Fellow in the Department of Peripheral Vascular Disease.

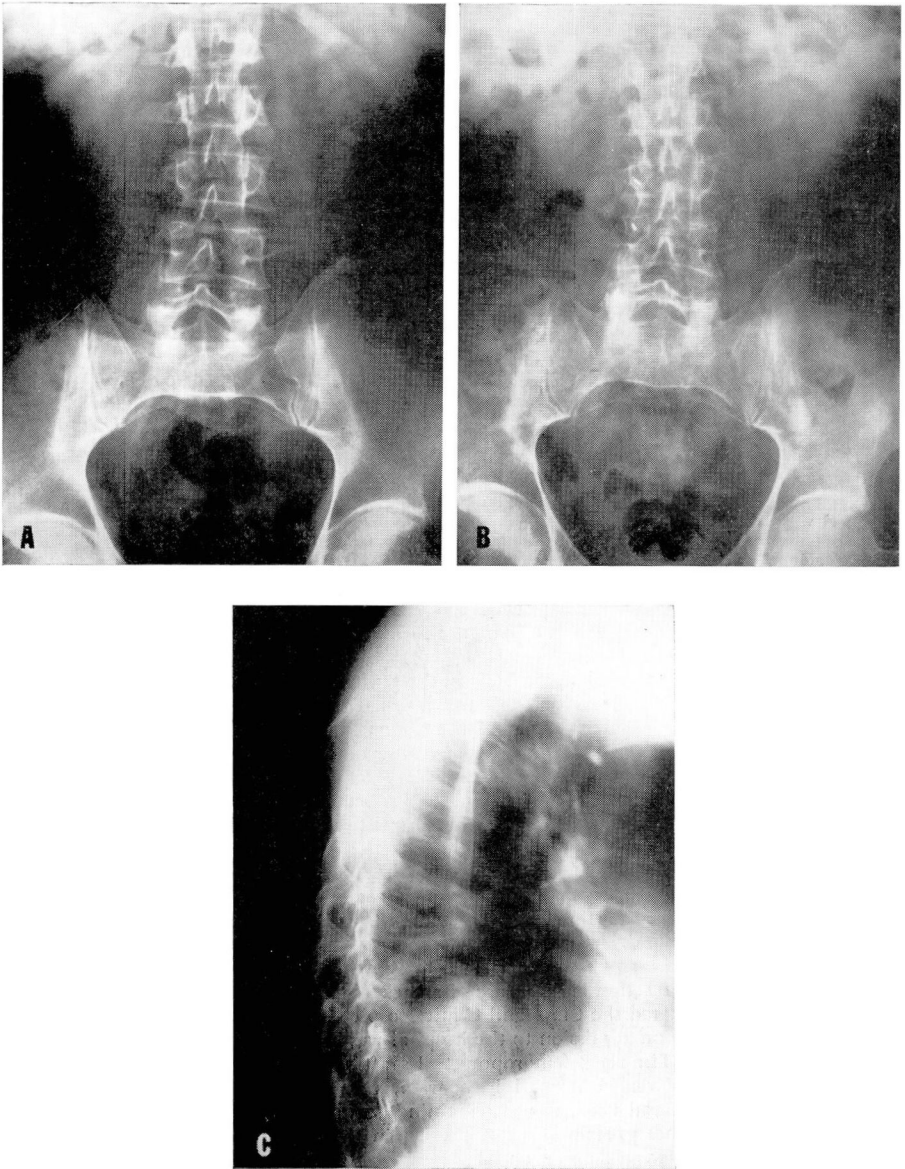


Fig. 1. Plain roentgenograms of the spine showing: A, a normal lumbar spine on April 30, 1962, just before heparin therapy was instituted; B and C, severe demineralization of the spine with compression fractures of the sixth and eighth thoracic vertebrae, on January 15, 1963, when the administration of heparin was discontinued.

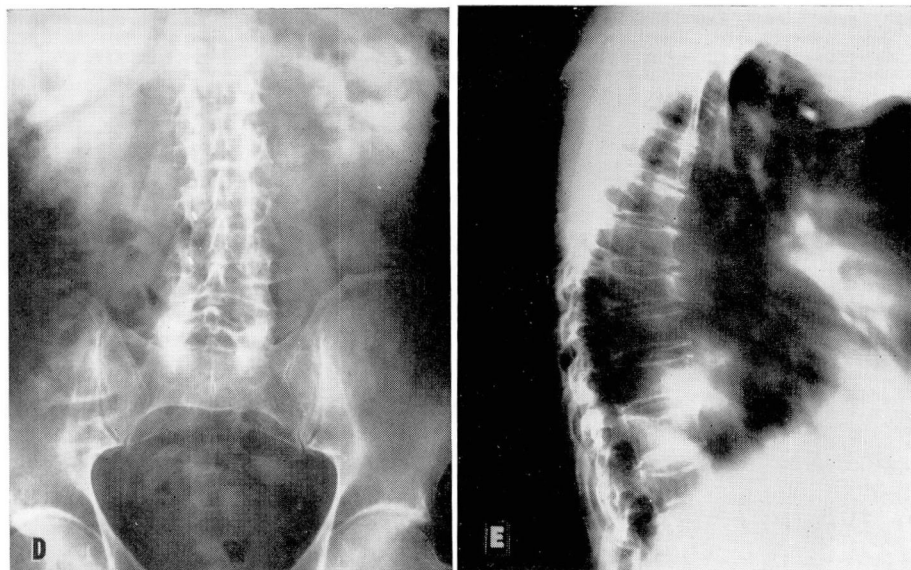


Fig. 1. Progress roentgenograms taken in April, 1965, showing: D and E, no evidence of recalcification and compression of sixth, seventh, eighth, and ninth thoracic vertebrae.

right hand showed periarticular demineralization but no subperiosteal changes to suggest hyperparathyroidism. Specimens of a Craig needle biopsy of the first lumbar vertebra were interpreted as indicating "no pathologic diagnosis."

The patient's daily injections of heparin were discontinued on February 8, 1963, and he was discharged from the hospital with the recommendation that 200 mg. of testosterone cypionate solution be given weekly by intramuscular injection. Calcium lactate (4 teaspoons four times a day by mouth), and a back brace were also prescribed.

The patient was readmitted to this hospital in April, 1965, because of a graft shutdown. At that time all his routine laboratory tests were normal, including a serum calcium of 10.1 mg. and a serum phosphorus of 2.3 mg. per 100 ml. Roentgenograms of the spine were reported as indicative of "considerable demineralization of the entire thoracic and lumbosacral spine with compression fractures of the sixth, seventh, eighth, and ninth thoracic vertebrae" (Fig. 1D and E). However, the patient was essentially asymptomatic during normal activity, having back pain only when he walked long distances.

DISCUSSION

Sodium heparin is the anticoagulant of choice in treating a wide variety of diseases, including myocardial infarction, venous thrombosis, pulmonary embolism, and during and after various vascular surgical procedures. Complications of therapy are few when the drug is used with care.²

Griffith and associates¹ reported the previously unrecognized syndrome of osteoporosis with multiple fractures in six of ten patients receiving from 15,000 to 30,000 units of heparin per day for six months or longer. Jaffe and Willis³ reported a similar case after the use of 20,000 units daily for 11 months. In each instance radiologic evidence of diffuse osteoporosis with

multiple fractures of the vertebrae or ribs was revealed. Cessation of heparin therapy was associated with remission of fractures and symptomatic improvement in each case, although no mention of skeletal recalcification was made.

We believe our case to be an example of heparin-induced osteoporosis occurring in a relatively short time while the patient was on rather large doses of heparin. It is important to note that additional compression fractures occurred after cessation of therapy even though the patient improved symptomatically. There was no evidence of recalcification (*Fig. 1D and E*) in spite of rather vigorous anabolic therapy and dietary supplements of calcium.

To date the exact pathogenesis of this syndrome is not known. It seems to be related to the dosage of heparin. Griffith and associates¹ speculated that perhaps heparin reduces lysosomal stability, thus releasing increased quantities of collagenase, leading to osteoporosis. Goldhaber⁴ demonstrated that the addition of small amounts of commercial heparin to a bone culture medium greatly enhanced the degree of bone resorption obtained with suboptimal concentrations of parathyroid extract. He theorized that heparin, available normally in mast cells, may be an important cofactor in bony resorption. Whatever the cause, recognition of this syndrome is of particular importance to the physician considering long-term therapy in the elderly, perhaps already osteoporotic, patient. Now, not only the level of anticoagulation must be considered, but also the duration of treatment. Periodic evaluation of the skeletal system is of the utmost importance.

SUMMARY

A case of osteoporosis, evidenced after heparin therapy, is reported, having occurred in a 55-year-old white man after he received 400 mg. of heparin sodium solution daily for four months. The importance of recognition of this complication of heparin therapy is stressed.

REFERENCES

1. Griffith, G. C.; Nichols, G., Jr.; Asher, J. D., and Flanagan, B.: Heparin osteoporosis. *J.A.M.A.* **193**: 91-94, 1965.
2. Dimond, E. G. (Moderator); Bauer, G.; Engelberg, H.; Griffith, G. C.; Donaldy, W. J.; Lyons, T. P.; Rapaport, S. T., and Zinn, W. J.: Panel Discussion. II. The clinical usage of heparin. *Am. J. Cardiol.* **14**: 49-54, 1964.
3. Jaffe, M. D., and Willis, P. W., III: Multiple fractures associated with long-term sodium heparin therapy. *J.A.M.A.* **193**: 158-160, 1965.
4. Goldhaber, P.: Heparin enhancement of factors stimulating bone resorption in tissue culture. *Science* **147**: 407-408, 1965.