

# CARPAL TUNNEL COMPRESSION CAUSED BY HEMATOMA ASSOCIATED WITH ANTICOAGULANT THERAPY

## REPORT OF A CASE

SHATTUCK W. HARTWELL, JR., M.D.,

AND

MINE KURTAY, M.D.\*

*Department of Plastic Surgery*

**A**NTICOAGULANT therapy has been known to cause symptomatic bleeding in many anatomic regions. The kidney, brain, nose, eye, lung, intestine, and the rectus abdominus sheath have all been the sites of this type of bleeding.<sup>1,2</sup> The following case, to our knowledge, is the first known reported instance of carpal tunnel compression caused by hematoma in a patient who had had long-term anticoagulant therapy.

## REPORT OF A CASE

A 60-year-old white man was first examined on October 1, 1965, in the Emergency Room of the Cleveland Clinic Hospital because of a swollen right hand with minimal discoloration and some tenderness in the midpalmar region. One year before this date the patient suffered a myocardial infarction and was treated with bishydroxycoumarin,† isosorbide dinitrate,‡ and chlorthalidone.§ One week before the onset of the present illness he fell, grasping hold of a fence for support with the right hand. After this sudden exertion the patient noted in the right ring finger some swelling and tenderness, which cleared without treatment. One day before the onset of the present illness the patient played in a golf match, and on reaching home he noted the palm of his right hand had become tender and swollen. There were no other accompanying symptoms.

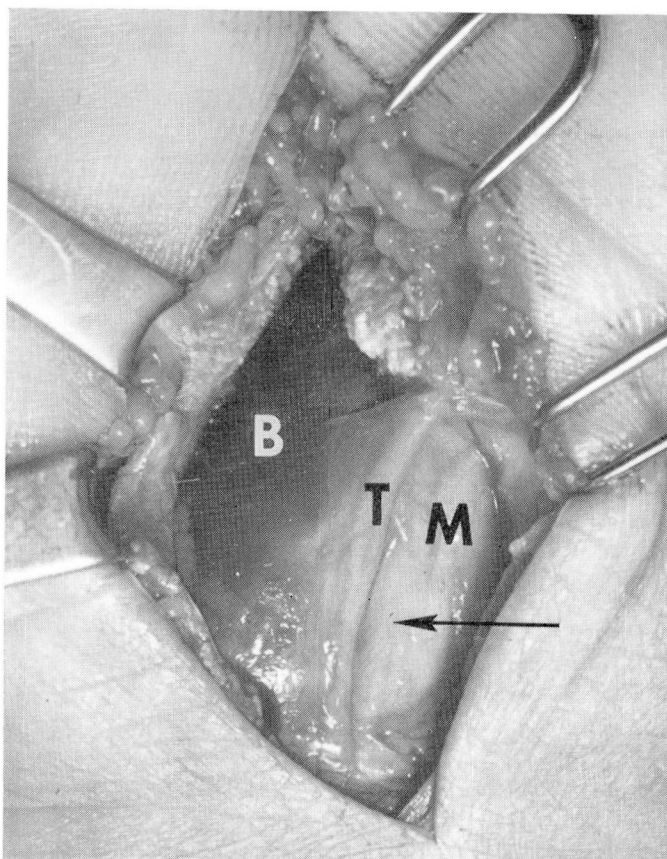
The history, the tenderness in the midpalmar region, and the swelling and discoloration of the volar aspect of the right forearm pointed to a diagnosis of hemorrhage induced by trauma. Analgesics, a gently compressive bandage, and elevation of the hand were advised. The third day after the golf game the patient experienced progressive numbness of the thumb, index, and middle fingers of the right hand, and increased swelling over both dorsal and volar aspects of the right hand. The patient was admitted to the hospital, and, with the preoperative diagnosis of carpal tunnel compression due to hemorrhage, was operated upon the next day. The preoperative anticoagulant medication was discontinued, and the prothrombin time promptly returned to normal values. With the patient under general anesthesia, and with a tourniquet on the right arm, the deep transverse carpal ligament was divided, and, after incising the synovial membranes and passing a fenestrated red-rubber catheter under suction into the palm, a large hematoma was evacuated. At the operation we observed that the median nerve was pinched and blanched at the point of constriction beneath the carpal ligament (*Fig. 1*). The next day the patient was discharged

\* Intern, Cleveland Clinic Hospital.

† Dicumarol, Abbott Laboratories.

‡ Isordil, Ives Laboratories, Inc.

§ Librium, Roche Laboratories.



**Fig. 1.** A longitudinal incision across the distal flexor crease on the right wrist has been carried distally (upward in the photo) into the base of the palm. The deep transverse carpal ligament is shown divided. Ulnarward (to the left in the photo) to the median nerve, M, can be seen the tendon of the superficial flexor, to the right middle finger, T, in a bulging, blood-filled, synovial membrane, B. The arrow indicates the point of visible pinching and blanching of the nerve.

from the hospital, and two weeks postoperatively all symptoms of carpal tunnel compression had subsided and the patient was feeling well. The function of the right hand is now completely normal in every respect.

#### COMMENT

A search of published information concerning bleeding in patients who are on courses of anticoagulant therapy has failed to disclose a single instance of bleeding into the carpal tunnel with subsequent compression symptoms. The history of the patient's golfing activities, the relationship of the strenuous activity to the onset of symptoms, and the knowledge that the patient had

been receiving anticoagulants made a definitive preoperative diagnosis an easy one to make. It is surprising that cases of carpal tunnel compression from hematomas in patients who regularly must take anticoagulants have not been reported.

It is generally appreciated that pressure from extravascular fluid, whether it be blood or edema fluid, is dangerous. The hazards of this kind of pressure are identical to those due to a tight and constrictive bandage. Bennett<sup>3</sup> and Kulowski<sup>4</sup> have reported that posttraumatic hemorrhage beneath the anti-brachial fascia can lead to Volkmann's ischemic paralysis, and the physician must be ever vigilant in suspecting pressure phenomena that could lead to serious difficulty.

There are recent reports<sup>2, 5</sup> of patients with hemorrhage into the compartment of the rectus abdominus muscle, who were receiving anticoagulant therapy. Physicians should be alert to the possibility that any patient who takes anticoagulant drugs may have symptoms that are referable to bleeding.<sup>6, 7</sup>

#### REFERENCES

1. Axelrod, M., and Kleinfeld, M.: Unusual hemorrhagic complications in Dicumarol therapy. *New York J. Med.* 51: 2789-2790, 1951.
2. Babb, R. R.; Spittell, J. A., Jr., and Bartholomew, L. G.: Hematoma rectus abdominis muscle complicating anticoagulant therapy. *Mayo Clin. Proc.* 40: 760-765, 1965.
3. Bennett, J. E.: Expanding forearm hematoma after apparent minor surgery. *Plast. & Reconstruct. Surg.* 36: 622-625, 1965.
4. Kulowski, J.: Subfascial tension hematoma and impending ischemia resulting from contusion of the forearm: case report. *Am. Surgeon* 24: 346-349, 1958.
5. Furste, W.: Hematoma of the abdominal wall. *Am. J. Surg.* 91: 540-551, 1956.
6. Naegeli, T., and associates: *Die thromboembolischen Erkrankungen, ein kurzes Handbuch.* Stuttgart: Schattauer, 1960, 1045 p.
7. Roos, J., and Joost, H. E. van: The cause of bleeding during anticoagulant treatment. *Acta med. scandinav.* 178: 129-131, 1965.