

HASHIMOTO'S THYROIDITIS AND GRAVES' DISEASE WITH EXOPHTHALMOS WITHOUT HYPERTHYROIDISM

JOHN J. EVERS MAN, M.D., PENN G. SKILLERN, M.D.,

Department of Endocrinology

AND

DONALD A. SENHAUSER, M.D.*

Department of Clinical Pathology

GRAVES' disease, in its classic form, is usually characterized by hypertrophy and hyperplasia of the thyroid, hyperthyroidism, and a specific type of ophthalmopathy.¹ It is well known that hyperthyroidism may exist without ophthalmopathy. The converse of this, although less well known, also exists; namely, the presence of this unique type of ophthalmopathy without hyperthyroidism. (No hyperthyroidism has developed in many such patients whose progress has been followed for several years.) From a standpoint of test procedures, patients with ophthalmopathy without hyperthyroidism resemble patients with typical Graves' disease. They frequently resist the suppressive influence of thyroid hormone on the uptake of I^{131} by the thyroid.² In addition, Liddle, Heyssel, and McKenzie³ found a long-acting thyroid stimulator (LATS) in the sera of five patients with ophthalmopathy without hyperthyroidism. Thus, it would seem that patients with this unique type of ophthalmopathy without hyperthyroidism have the same basic disease process as patients with typical Graves' disease.

The association of Hashimoto's (lymphocytic) thyroiditis with hyperthyroidism due to Graves' disease, with or without ocular signs has been reported to have occurred in about 5 percent of patients.⁴⁻⁹ The characteristic pathologic findings that were observed, in addition to various degrees of oxyphilia of the cytoplasm of the thyroid cells, included lymphocytic and plasma-cell infiltration, and fibrosis. (These changes are essentially the same as those reported to occur in previously euthyroid patients who had Hashimoto's thyroiditis without Graves' disease.) In such patients, the incidence of hypothyroidism after subtotal thyroidectomy has been high, ranging from 29 to 67 percent.⁶⁻⁹

From a paper presented at the meeting of the American Thyroid Association, May 10 to 12, 1962, New Orleans, Louisiana.

** Formerly member of the staff, Department of Clinical Pathology, Cleveland Clinic; present address: Department of Pathology, University of Missouri School of Medicine, Columbia, Missouri.*

Our report presents the clinical and laboratory findings in 15 patients with Graves' disease with progressive exophthalmic ophthalmoplegia, with and without goiter, in none of whom did hyperthyroidism develop. In some of these patients hyperthyroidism did not develop presumably because the thyroid was affected by lymphocytic thyroiditis.

MATERIALS AND METHODS

Fifteen patients, 13 women and 2 men, underwent clinical evaluation to establish the presence or absence of symptoms and signs of hyperthyroidism. Radioiodine (I^{131}) uptake values were determined by direct measurement with a scintillation counter over the thyroid glands. The normal range of values in our laboratory is from 15 to 49 percent at 24 hours. Thyroid suppression tests were performed on six patients, either by the administration of 4 gr. of U.S.P. desiccated thyroid* daily for two weeks or longer, or 75 μ g. of l-triiodothyronine† daily for three days or longer. A decrease in the 24-hr. thyroidal I^{131} uptake value of more than 50 percent of the original 24-hr. uptake value indicates adequate suppression of the thyroid gland. The thyroid-stimulating hormone (TSH) test was performed on four patients with from 5 to 10 units of U.S.P. TSH.* A response is considered normal when the I^{131} uptake increases by 50 percent (or more) over the original 24-hr. uptake value after the administration of TSH. Serum protein-bound iodine (PBI) determinations were performed on all patients. Normal values range from 3.5 to 8 μ g. per 100 ml.

The presence of thyroglobulin antibodies was determined by the tanned red-cell hemagglutination test (TRC) based on the method of Boyden¹⁰ as modified by Stavitsky.¹¹ When tanned formalinized thyroglobulin sensitized cells were used as indicators, the test was performed by the method of Fulthorpe and associates.¹² The serum antibodies to a thyroid cytoplasmic (microsomal) component were measured by a complement-fixation (CF) technic based on the method developed by Roitt and Doniach,¹³ utilizing a slow-spun extract of normal thyroid homogenate as the antigen.

Pathologic specimens were obtained in 2 of the 15 patients, one by needle biopsy, and one by surgical biopsy. In two other patients attempts to obtain needle biopsy specimens were unsuccessful because of the small size of the goiters.

Only one patient (case 3) had been receiving thyroid hormone; this had been taken for only two weeks before studies were performed. No patient had had I^{131} therapy or surgical treatment before the antibody or pathologic studies were performed.

* *Armour Pharmaceutical Company.*

† *Cytomel, Smith Kline & French Laboratories.*

RESULTS

The results of the clinical and laboratory studies of the 15 patients are summarized in *Table 1*. Pathologic study confirmed the diagnosis of Hashimoto's thyroiditis in two of the patients (patients 1 and 2). In each of five of the other patients (patients 3, 4, 5, 6, and 7) the diagnosis was adequately substantiated by the presence of high thyroglobulin antibody (TRC) titers, and in patients 3, 4, and 5 other characteristic laboratory findings. We believe that patients 8, 9, 10, and 11 also had some degree of Hashimoto's thyroiditis, perhaps of a focal type as evidenced by low TRC titers, and in patient 10 the demonstration of antibodies to thyroid cytoplasmic component (CF titer). The four other patients (patients 12, 13, 14, and 15) had no measurable antibodies either by TRC agglutination or the CF technic.

Results of the thyroid suppression tests were abnormal in four of the six patients tested. The results of TSH tests were abnormal in the four patients who were tested. The 24-hr. I^{131} uptake values were normal in 13 of the 14 patients tested. Paper electrophoretic protein patterns obtained on the sera of 3 of the 15 patients were normal.

Eight of the fifteen patients had goiters. All of the patients had unequivocal, active, ocular signs of Graves' disease. The ocular signs were bilateral in all but one patient. Also, in all but one patient, the presence of the euthyroid state was evidenced by the absence of clinical symptoms and signs of hyperthyroidism, and the presence of normal PBI values. Patient 6 was hypothyroid when first examined. The clinical and laboratory findings of the two patients with histologic proof of Hashimoto's thyroiditis are described in detail in the following report of cases.

REPORT OF CASES

Case 1. A 32-year-old woman was examined on May 10, 1955, because of a goiter of three months' duration. The goiter was firm, diffuse, and of an estimated weight of 60 gm. Exophthalmos was present, edema of the eyelids (*Fig. 1*), and lid retraction without lid lag. There was no chemosis or paresis of the extraocular muscles. Exophthalmometer readings were 23 mm. for each eye. The pulse rate was 68. There were no symptoms or signs of hyperthyroidism. Laboratory work included three determinations of basal metabolic rate (BMR), ranging from -8 percent to -15 percent; a serum cholesterol value of 286 mg. per 100 ml.; and a 24-hr. I^{131} uptake of 20 percent, which remained at 20 percent after the patient received 5 units of TSH. A needle biopsy specimen of the goiter (*Fig. 2*) showed the lobular architecture to be disrupted by interfollicular hyperplasia. The follicles were small and were lined by hyperplastic epithelial cells that were oxyphilic throughout the sections. Histiocytes and macrophages were present in many of the follicular lumens. The interstitium was infiltrated with large numbers of lymphocytes and plasma cells. The patient was given 2 gr. of U.S.P. desiccated thyroid. Nine months later, the patient was still taking this medication and the goiter had disappeared. However, after institution of treatment with thyroid, her eyes initially worsened with more periorbital swelling and exophthalmos. Three years later the exophthalmos and periorbital swelling had largely disappeared.

Table 1.—*Clinical and laboratory results in 15 patients with Graves' disease with exophthalmos and without hyperthyroidism*

Pa- tient no.	Sex, Age, yr.	Goiter consistency and estimated weight	I ¹³¹ I test			TRC titer	CF titer	Biopsy per- formed
			24-hr. up- take, %	After I-triiodothyronine	After TSH			
1	F, 32	Firm, diffuse, 60 gm.	18	—	No stimulation	1:8	—	Yes
2	F, 41	Firm, diffuse, discrete nodule in the right lobe, 50 gm.	29	Suppressed	No stimulation	—	—	Yes
3	F, 50	Firm, diffuse, 50 gm.	{38 40 44	Not suppressed	—	{1:250,000 1:25,000	{Negative Negative	No
4	F, 49	Not present	12	—	No stimulation	{1:25,000 1:2,500,000	—	No
5	F, 51	Not present	40	Not suppressed	—	7.6 {5.3 6.1	1:4,000	No
6	F, 70	Not present	—	—	—	1.3	1:250,000	No
7	F, 51	Firm, diffuse, 50 gm.	50	—	—	6.1	{1:2,500 1:25,000	No
8	F, 54	Firm, diffuse, 40-45 gm.	{22 19 17	—	No stimulation	3.2	{1:256 1:024	No
9	M, 63	Not present	9	Not suppressed	—	{5.1 4.4	{Negative Negative	No
10	F, 43	Firm, diffuse, 30-35 gm.	38	Not suppressed	—	6.0 {7.9 5.2	{1:20 1:20	No
11	F, 41	Firm, diffuse, 50 gm.	16	—	—	{5.5 4.8	{Negative 1:250	No
12	F, 41	Firm, diffuse, 35 gm.	34	Suppressed	—	7.1	Negative	No
13	F, 63	Not present	7	—	—	5.6	Negative	No
14	M, 37	Not present	15	—	—	7.0	Negative	No
15	F, 35	Not present	36	—	—	7.3	Negative	No



Fig. 1. Case 1. Photo showing exophthalmos and right lid retraction.

Case 2. A 41-year-old woman during a routine physical examination on June 28, 1954, was discovered to have firm enlargement of both lobes of the thyroid that was estimated to weigh 60 gm. A small discrete nodule was believed to be present also in the right lobe. There were no signs or symptoms of hypothyroidism or hyperthyroidism. There was no evidence of ocular involvement; the PBI value was 5.0 $\mu\text{g.}$ per 100 ml.; a 24-hr. I^{131} uptake was 29 percent. After suppression with 75 $\mu\text{g.}$ of l-triiodothyronine daily for three days the 24-hr. uptake was decreased to 14 percent. The 6-hr. I^{131} uptake was 19 percent before and 24 percent after 5 units of TSH. Six months later, because of the discrete nodule and the possibility of carcinoma, a bilateral subtotal thyroidectomy was performed. On section (*Fig. 3*) the epithelial elements of the gland were arranged in nodular fashion separated by dense interlobular bands of hyaline connective tissue. In one region, there was a cystic focus of old hemorrhage, partly calcified, about which there were reactive fibrosis and some chronic inflammation. The nodules were composed of moderate-sized follicles lined by cuboidal epithelium in a single layer, largely oxyphilic. The follicles contained moderate amounts of colloid, and in several there were collections of histiocytes and macrophages. The interstitium contained many discrete and confluent collections of lymphocytes and plasma cells. The patient was advised to take 2 gr. of desiccated thyroid daily as permanent therapy. Approximately six months later exophthalmos of the right eye developed, with lacrimation. There were no chemosis and no paresis of the extraocular muscles. The exophthalmometer readings were 21 mm. for the right eye and 16 mm. for the left eye. Roentgenograms showed the optic foramina to be normal. A PBI value and the BMR were normal and clinically she was euthyroid. It was believed that this patient demonstrated unilateral ocular signs and symptoms of Graves' disease.

When last examined six years later, she was euthyroid while still taking thyroid medication. The lacrimation had ceased but she still had unilateral exophthalmos with almost no change in the degree of proptosis.

Cases 3 to 15 inclusive. These patients were examined between March 22, 1961, and

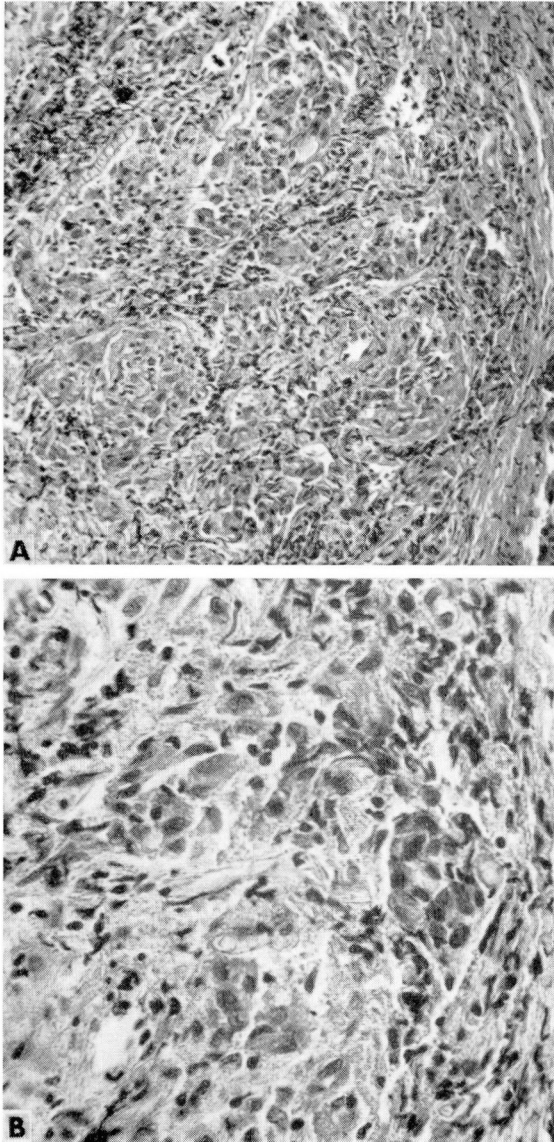


Fig. 2. Case 1. Photomicrographs of a section of a needle biopsy specimen of the goiter. Hematoxylin-cosin stain; A, magnification $\times 180$; B, magnification $\times 400$.

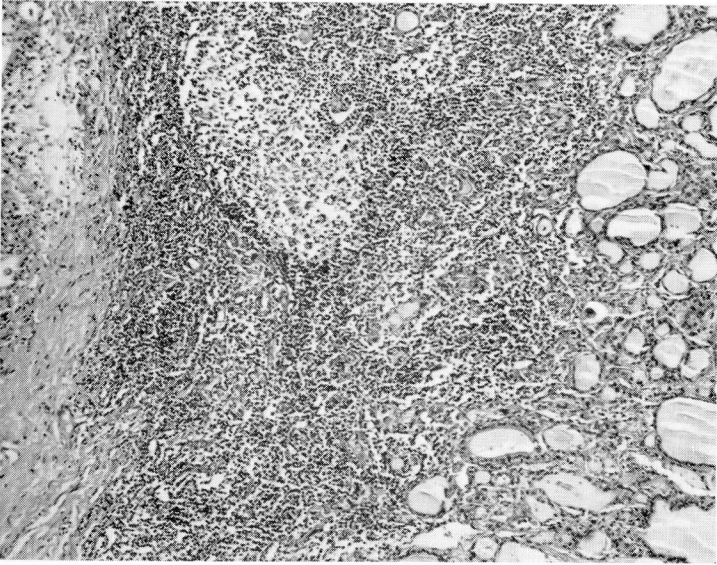


Fig. 3. Case 2. Photomicrograph of a section of the thyroid gland, showing hyaline connective tissue and confluent collections of lymphocytes and plasma cells in the interstitium. Hematoxylin-eosin stain; magnification $\times 100$.

September 22, 1965. All had bilateral exophthalmos, clinically and according to exophthalmometer readings. All were euthyroid by clinical observation and laboratory tests.

DISCUSSION

The euthyroid or hypothyroid state of at least some of the 15 patients with Graves' disease with exophthalmos, whose cases are reported here, is probably due to various degrees of thyroid-cell failure. The histopathologic findings from the tissue specimens of two patients were essentially the same as those reported to occur in patients with Hashimoto's thyroiditis alone,¹⁴⁻¹⁶ and in patients with Graves' disease with hyperthyroidism associated with Hashimoto's thyroiditis.⁴⁻⁹ Also, high values of TRC titers were previously reported associated with Hashimoto's thyroiditis^{13, 17} with and without goiter formation.¹³ Since these two conditions (Hashimoto's thyroiditis and primary hypothyroidism without goiter) are probably clinical variants of the same disease process,¹⁸⁻²⁰ and since high TRC titers are always indicative of the presence of lymphocytic thyroiditis,^{13, 17} we believe we are justified in using the term *Hashimoto's thyroiditis* to describe the probable pathologic changes that occurred in the glands of our patients without goiter as well as those with goiter. However, this conclusion is presumptive and is based on prior studies rather than on histologic confirmation in most of the cases presented here.

The presence of progressive bilateral ocular signs so characteristic of patients with Graves' disease and hyperthyroidism is sufficient to substantiate the diagnosis of Graves' disease in 14 of the 15 patients. The absence of any other cause of the unilateral exophthalmos in patient 2, after eight years of observation, also favors the diagnosis of Graves' disease.

The lack of suppression of I^{131} uptake in four patients (3, 5, 9, and 10) indicates that the Hashimoto's thyroiditis involved thyroid cells that were previously hyperplastic due to Graves' disease. Werner² pointed out that in his series of 10 euthyroid patients with Graves' disease and exophthalmos the failure of suppression of thyroidal I^{131} uptake (after thyroxin and l-triiodothyronine) was characteristic of involvement of the cells by the pathologic mechanism of Graves' disease. In contrast, Buchanan and associates²¹ described the occurrence of suppression of I^{131} uptake by thyroxin in three euthyroid patients with bilateral exophthalmos. Because of this thyroidal suppression, the conclusion of these investigators²¹ was that these patients did not have Graves' disease. This conclusion may not be valid, because of the suppression of I^{131} uptake by l-triiodothyronine in euthyroid patients with Graves' disease reported by Pinchera, Pinchera, and Stanbury,²² and which we have confirmed.

In addition to that in patient 6, we previously observed the occurrence of spontaneous clinical hypothyroidism in two other patients (not reported in this series) who had unequivocal bilateral exophthalmos without goiter. Since the euthyroid patient with Graves' disease and Hashimoto's thyroiditis is more likely to become clinically hypothyroid than hyperthyroid as the years go by, as evidenced by our observations, we believe it is important to prescribe permanent therapy with thyroid hormone for all such patients.

High TRC titers have been observed previously to be indicative of the presence of Hashimoto's thyroiditis.^{13, 17, 18} Roitt and Doniach,¹³ Buchanan and associates,²¹ and Hales and associates²³ reported the occurrence of TRC antibodies in a significant percentage of patients with hyperthyroidism due to Graves' disease. They stated that examination of the thyroid glands of these patients demonstrated the characteristic pathologic findings of associated Hashimoto's thyroiditis. According to Hales and associates,²³ in Graves' disease TRC antibodies were most likely to be present with exophthalmos.

The CF antibody to microsomal antigen present in the cytoplasm of thyroid cells was reported by Belyavin and Trotter,²⁴ and Anderson, Goudie, and Gray²⁵ to be an aid in the diagnosis of Hashimoto's thyroiditis. Positive antibody titers were reported present in more than 50 percent of several series of patients with Graves' disease and hyperthyroidism.^{13, 24, 25} The highest titers were in association with extensive Hashimoto's thyroiditis.^{13, 24, 25}

The TRC test has seemed to be more useful than the CF antibody test in reflecting the extent and the severity of the inflammatory process. In our laboratory, as determined by histologic correlation on patients with Hashimoto's thyroiditis proved by biopsy study, we have established that a TRC titer of 1:2500 or higher is almost always associated with the severely destructive inflammatory lesions in the gland.¹⁸ A positive titer of less than 1:2500 is rarely associated with extensive destruction of the glandular architecture. Titers determined by the CF technic do not correlate so well with the histopathologic findings, and extensive destruction and fibrosis may be present in the absence of CF antibody in the serum.¹⁸

Our preliminary studies suggest that the occurrence of high TRC titers may be especially useful in establishing the diagnosis of Hashimoto's thyroiditis in some patients with Graves' disease with no hyperthyroidism. (In addition, others²² have reported positive thyroid antibody titers in patients with exophthalmic ophthalmoplegia without thyrotoxicosis.) These tests should be especially useful in those euthyroid or hypothyroid patients with Graves' disease with a small goiter or with no goiter when a needle biopsy cannot be performed. Negative antibody tests do not necessarily exclude the presence of Hashimoto's thyroiditis, since a significant 25 percent of patients with Hashimoto's thyroiditis alone may have negative TRC titers and/or negative CF titers.^{13, 17} Also, euthyroid patients with Graves' disease and exophthalmos, particularly those with negative antibody titers, are euthyroid not necessarily because of the presence of Hashimoto's thyroiditis. This mechanism may serve, however, as an explanation for a number of these interesting cases.

SUMMARY

The association of Hashimoto's thyroiditis with Graves' disease with exophthalmos without hyperthyroidism in 15 patients is discussed. In two patients the diagnosis of Hashimoto's thyroiditis was proved by histologic examination. Five of the other 12 patients had sufficiently high thyroglobulin antibody titers to substantiate the diagnosis. Four other patients had suggestive evidence of lymphocytic thyroiditis, perhaps of a focal type, as evidenced by low thyroglobulin antibody titers. Four patients, with Graves' disease with exophthalmos without hyperthyroidism, were seen during this period of time in whom thyroid antibodies were not demonstrated. It is believed that the euthyroid or hypothyroid state of at least some of these patients with Graves' disease was due to the presence of Hashimoto's thyroiditis.

REFERENCES

1. Means, J. H.; DeGroot, L. J., and Stanbury, J. B.: *The Thyroid and Its Diseases*, 3d ed. New York: McGraw-Hill Book Company, Inc., 1963, 618 p.; p. 159.

2. Werner, S. C.: Euthyroid patients with early eye signs of Graves' disease; their responses to l-triiodothyronine and thyrotropin. *Am. J. Med.* **18**: 608-612, 1955.
3. Liddle, G. W.; Heyssel, R. M., and McKenzie, J. M.: Graves' disease without hyperthyroidism. *Am J. Med.* **39**: 845-848, 1965.
4. Polowe, D.: Struma lymphomatosa (Hashimoto) associated with hyperthyroidism; report of a case with clinical and histopathologic study. *Arch. Surg.* **29**: 768-777, 1934.
5. Eden, K. C., and Trotter, W. R.: A case of lymphadenoid goitre associated with the full clinical picture of Graves' disease. *Brit. J. Surg.* **29**: 320-322, 1942.
6. Whitesell, F. B., Jr., and Black, B. M.: A statistical study of the clinical significance of lymphocytic and fibrocytic replacements in the hyperplastic thyroid gland. *J. Clin. Endocrinol.* **9**: 1202-1215, 1949.
7. Greene, R.: Significance of lymphadenoid changes in thyroid gland. *J. Endocrinol.* **7**: 1-6, 1950.
8. Levitt, T.: Evolution of the toxic thyroid gland; a clinical and pathological study based on 2114 thyroidectomies. *Lancet* **2**: 957-965, 1951.
9. Mason, R. E., and Walsh, F. B.: Exophthalmos in hyperthyroidism due to Hashimoto's thyroiditis. *Bull. Johns Hopkins Hosp.* **112**: 323-329, 1963.
10. Boyden, S. V.: The adsorption of proteins on erythrocytes treated with tannic acid and subsequent hemagglutination by antiprotein sera. *J. Exper. Med.* **93**: 107-120, 1951.
11. Stavitsky, A. B.: Micromethods for study of proteins and antibodies; procedure and general applications of hemagglutination and hemagglutination-inhibition reactions with tannic acid and protein-treated red blood cells. *J. Immunol.* **72**: 360-367, 1954.
12. Fulthorpe, A. J.; Roitt, I. M.; Doniach, D., and Couchman, K.: A stable sheep cell preparation for detecting thyroglobulin auto-antibodies and its clinical applications. *J. Clin. Path.* **14**: 654-660, 1961.
13. Roitt, I. M., and Doniach, D.: Thyroid auto-immunity. *Brit. M. Bull.* **16**: 152-158, 1960.
14. Hashimoto, H.: Zur Kenntniss der lymphomötösen Veränderung der Schilddrüse (Struma lymphomatosa). *Arch. f. klin. Chir.* **97**: 219-248, 1912.
15. Hazard, J. B.: Thyroiditis: a review; part II. *Am. J. Clin. Path.* **25**: 399-426, 1955.
16. Lindsay, S.; Dailey, M. E.; Friedlander, J.; Yee, G., and Soley, M. H.: Chronic thyroiditis: a clinical and pathologic study of 354 patients. *J. Clin. Endocrinol.* **12**: 1578-1600, 1952.
17. Senhauser, D. A.; Hazard, J. B.; Williams, F. C., and Crile, G., Jr.: The incidence of circulating thyroid antibodies, as measured by means of two agglutination technics; a survey of one hundred eighty-nine cases of thyroid disease with histopathologic diagnosis. *Am. J. Clin. Path.* **38**: 482-486, 1962.
18. Senhauser, D. A.: Immunopathologic Correlations in Thyroid Diseases, Chap. 10, p. 167-182 in Hazard, J. B., and Smith, D. E. (editors): *The Thyroid*. International Academy of Pathology Monograph. Baltimore: The Williams & Wilkins Co., 1964, 288 p.
19. Doniach, D., and Roitt, I. M.: Auto-immunity in Hashimoto's disease and its implications. *J. Clin. Endocrinol.* **17**: 1293-1304, 1957.
20. Skillern, P. G.; Crile, G., Jr.; McCullagh, E. P.; Hazard, J. B.; Lewis, L. A., and Brown, H.: Struma lymphomatosa: primary thyroid failure with compensatory thyroid enlargement. *J. Clin. Endocrinol.* **16**: 35-54, 1956.
21. Buchanan W. W.; Alexander, W. D.; Crooks, J.; Koutras, D. A.; Wayne, E. J.; Ander-

HASHIMOTO'S THYROIDITIS AND GRAVES' DISEASE

- son, J. R., and Goudie, R. B.: Association of thyrotoxicosis and auto-immune thyroiditis. *Brit. M. J.* **1**: 843-847, 1961.
22. Pinchera, A.; Pinchera, M. G., and Stanbury, J. B.: Thyrotropin and long-acting thyroid stimulator assays in thyroid disease. *J. Clin. Endocrinol.* **25**: 189-208, 1965.
23. Hales, I. B.; Myhill, J.; Rundle, F. F.; Mackay, I. R., and Perry, B.: Relation of eye signs in Graves' disease to circulating antibodies to thyroglobulin. *Lancet* **1**: 468-469, 1961.
24. Belyavin, G., and Trotter, W. R.: Investigations of thyroid antigens reacting with Hashimoto's sera, evidence for an antigen other than thyroglobulin. *Lancet* **1**: 648-652, 1959.
25. Anderson, J. R.; Goudie, R. B., and Gray, K. G.: The thyrotoxic complement-fixation reaction. *Scottish M. J.* **4**: 64-74, 1959.