

Bilateral internal mammary artery implants

OPERATIVE TECHNIC—A PRELIMINARY REPORT

RENE G. FAVALORO, M.D.

*Department of Thoracic and
Cardiovascular Surgery*

INTERNAL mammary artery implantation is the most reliable method of increasing myocardial circulation. More than 500 patients have undergone left internal mammary artery implantation at the Cleveland Clinic Hospital, and postoperative studies have shown that 90 percent of the arteries stay open with various degrees of collateral circulation. However, one internal mammary artery alone cannot bring about revascularization of the entire left ventricle. At the most, the left internal mammary artery can perfuse the anterolateral wall of the left ventricle. A significant number of patients had severe diffuse disease with involvement of the right coronary artery and the anterior ascending and circumflex branches of the left coronary artery. In those patients, revascularization of the diaphragmatic wall of the left ventricle is mandatory. Since July of 1966, a new operative technic has been developed, which allows bilateral internal mammary artery implantation in the left ventricle.

TECHNIC

With the patient in the supine position, a median sternotomy is performed (*Fig. 1*). The incision is extended halfway between the end of the sternum and the umbilicus to obtain the necessary length. With a new retractor (*Fig. 2*) first the left side of the sternum is lifted, giving good exposure of the left internal mammary artery (*Fig. 3*) that is dissected as Sewell and Davalos¹ have previously described. This dissection is believed to be less traumatic and gives more protection to the artery than does the original Vineberg² operation. The mammary artery is completely detached from the sternum, cephalad up to the entrance of the artery in the apex of the chest and down to the rectal sheath where the artery connects to the inferior epigastric artery.

After the pedicle is dissected it is wrapped in gauze impregnated with papaverine solution, and is left behind the sternum. The retractor is then moved to the other side of the operating table and the right internal mammary artery is prepared in the same fashion. When both mammary arteries are dissected, the Finochetto spreader is applied. The prepericardial fat is separated from the underlying pericardium, starting in the middle

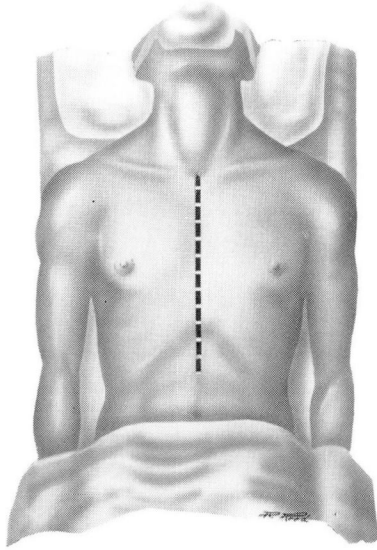


Fig. 1. Sketch of median sternotomy; notice that the incision is longer than usual.

and proceeding cephalad and over the left side. The pericardium is then opened vertically (*Fig. 4*). Two transverse incisions are made close to the diaphragm. Another incision is carried up over the left side, as shown in the diagram. This is an important step to prevent distortion of the left pedicle after implantation. After the pericardium is open, the heart is lifted slowly and is moved slightly over to the right side. A sponge is placed on the left side under it. This maneuver is performed with extreme gentleness, while strictly observing the continuous monitoring of the blood pressure by a Rochester needle previously inserted in the femoral artery.

The left internal mammary artery is implanted first (*Fig. 5*). The apex of the heart is retracted and a tunnel is made in the diaphragmatic wall of the left ventricle. The distal end of the tunnel is close to the posterior descending branch of the right coronary artery (in three patients the tunnel was started in the wall of the right ventricle), and the proximal end emerges between the posterolateral branches of the circumflex artery. Before the implantation, the size of the pedicle is reduced, taking most of the muscle and veins up to the level that will be inside the tunnel. The right mammary artery is implanted parallel to the anterior descending branch of the left coronary artery (*Fig. 6*), the tunnel having been made on the anterolateral wall of the left ventricle by means of the same technic.

At the completion of the procedure, both mammary implantations are in the wall of the left ventricle—one in the anterolateral aspect (right internal mammary artery), the other (left internal mammary artery) in the

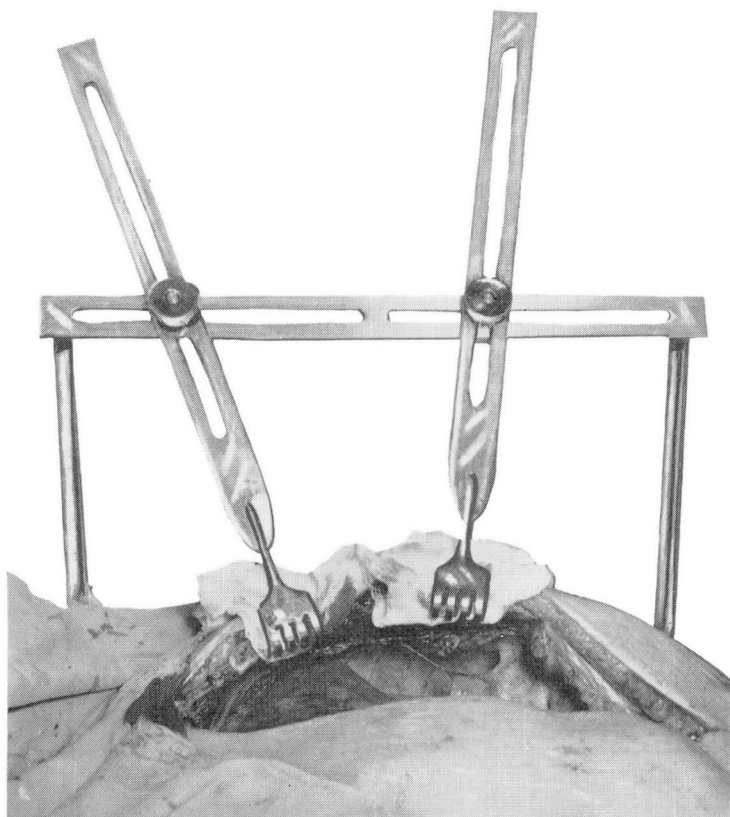


Fig. 2. This special retractor is designed to lift the sternum and to expose the mammary artery. The operation can be performed with only one assistant.

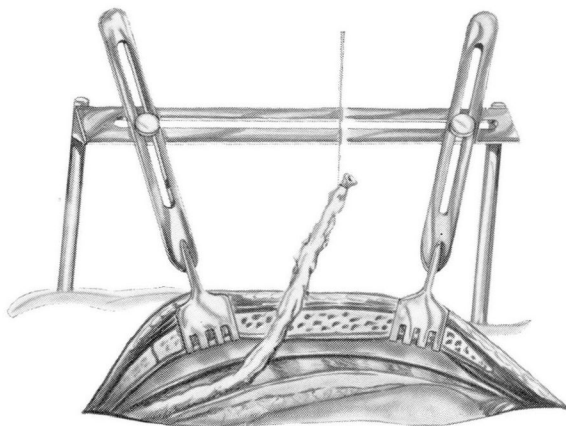


Fig. 3. Sketch of dissection of the left internal mammary artery (Sewell technic) from the connection with the inferior epigastric artery up to the origin in the apex of the chest.

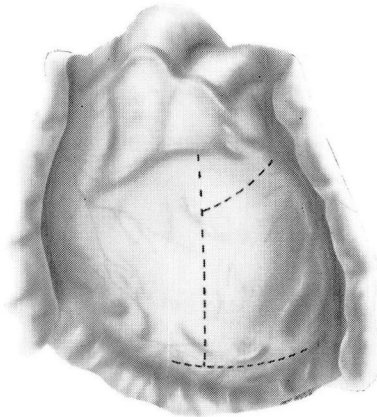


Fig. 4. Sketch showing incision in the pericardium after the prepericardial fat has been dissected.

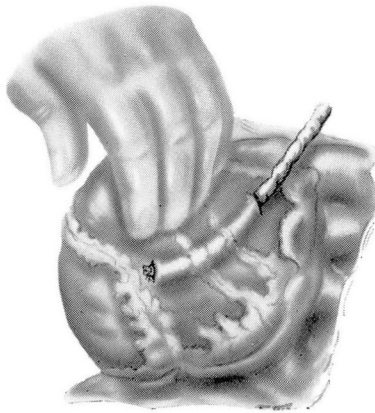


Fig. 5. Sketch showing left internal mammary artery implant in the diaphragmatic and posterolateral wall of the left ventricle.

diaphragmatic and posterolateral wall (*Fig. 7*). Both implants are covered and protected with the prepericardial fat previously dissected. The pericardium is left unclosed to prevent tension over the implants. Three tubes are left in for drainage: one in the left side of the chest, one in the right side of the chest, and one in the middle. The median sternotomy is closed in the usual fashion, utilizing heavy wire in the sternum and double no. 1 chromic catgut in the abdominal portion.

COMMENT

This bilateral internal mammary artery implant operation has been performed on 34 patients; there was no hospital mortality. The youngest pa-

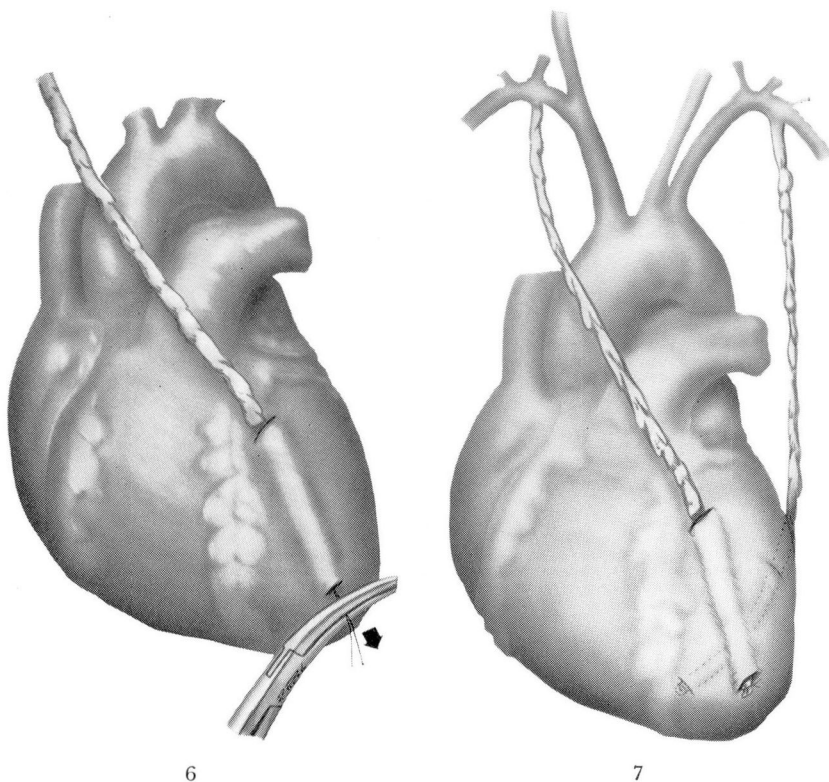


Fig. 6. Sketch showing right internal mammary artery implant parallel to the anterior descending branch of the left coronary artery in the wall of the left ventricle.

Fig. 7. Sketch showing the end of the procedure, both mammary arteries being in the wall of the left ventricle.

tient was 32 years of age, and the oldest, 70 years of age. All of these patients had many symptoms of severe diffuse coronary artery disease. Each of them had been previously studied by means of the Sones's technic of selective coronary angiography, including left ventriculograms, to evaluate the condition of the heart muscle.

The bilateral internal mammary artery implantation has several advantages: (1) The median sternotomy incision provides the most comfortable of all thoracotomies for the patient, and results in fewer pulmonary complications in the immediately postoperative period. (2) The patient is in a supine position during the entire procedure, allowing good ventilation of both lungs and excellent oxygenation, important conditions in patients with coronary artery disease. (3) Both internal mammary artery implants are in the wall of the left ventricle.

SUMMARY

A new technic for myocardial revascularization is described; the operation is performed through a midline incision. Both internal mammary arteries are dissected and implanted in the wall of the left ventricle, the right mammary artery in the anterolateral wall and the left mammary artery in the diaphragmatic wall. Thirty-four patients with severe diffuse coronary artery disease have undergone this operation; there was no hospital mortality. Preoperatively each patient was evaluated by means of selective coronary cineangiography (Sones's technic). The results so far have been entirely satisfactory.

REFERENCES

1. Sewell, W. H., and Davalos, P. A.: Factors influencing collateral arterial formation from pedicles on the surface of the hearts of dogs. *Angiology* 13: 231-240, 1962.
2. Vineberg, A. M.: Development of an anastomosis between the coronary vessels and a transplanted internal mammary artery. *Canad. M. A. J.* 55: 117-119, 1946.