

Successful pulmonary embolectomy

REPORT OF A CASE

RENE G. FAVALORO, M.D.,

DONALD B. EFFLER, M.D.,

Department of Thoracic and Cardiovascular Surgery

WILLIAM C. SHELDON, M.D.

*Department of Cardiovascular Disease and Cardiac
Laboratory*

TRENDELENBURG¹ in 1908 proposed the use of pulmonary embolectomy and operated upon three patients who had embolisms in the lungs, but they did not survive. The first report of a successful embolectomy was that of Kirschner² in Germany in 1924; embolectomy was accomplished in the United States in 1958.³ Until 1961, only 23 cases of embolectomy with satisfactory outcome had been reported.⁴ Since the introduction of cardiopulmonary bypass, for pulmonary embolectomy, by Sharp,⁵ and by Cooley, Beall, and Alexander⁶ in 1961, an additional 24 operations have been recorded.⁷

REPORT OF A CASE

A 58-year-old man was first examined at the Cleveland Clinic Hospital on December 1, 1965, because of acute pain in the chest. He had been well until mid October 1965 when he began to experience pain in the right leg. He was hospitalized for four weeks, during which time venous ligations were performed as part of the treatment of thrombophlebitis. On November 27, 1965, shortness of breath developed and pain in the lower right side of the chest, accentuated by respiration. The patient was hospitalized and treated for a pulmonary infarct, with heparin, penicillin, chloromycetin, and propoxyphene hydrochloride with aspirin.* On December 1, 1965, he had another episode of severe pain in the chest. Blood pressure was 80/26 mm Hg, respiration rate was 28, and pulse rate was 116. He was transferred to the Cleveland Clinic Hospital.

Another episode of chest pain occurred in the emergency room, and the patient was cyanotic and acutely ill. The blood pressure, with metaraminal infusion was 70/0 mm Hg. There was gross distension of the jugular veins in the supine position. Cardiac examination revealed no clinical enlargement or thrills; the rhythm was regular at 110 beats per minute; no murmur was audible, but there was a protodiastolic gallop at the apex. There were moist rales at the base of the right lung, with apparently good ventilation in other regions. The abdomen was normal; there was no peripheral edema. All peripheral pulses were feeble. Results of gross neurologic examination were essentially normal. An electrocardiogram showed only an incomplete right bundle-branch block. Roentgenograms of the chest revealed elevation of the right leaf of the diaphragm, with an infiltrate over the right lower lung field consistent with pulmonary infarction.

An emergency catheterization of the right side of the heart was immediately performed.

* *Darvon, Eli Lilly and Company.*

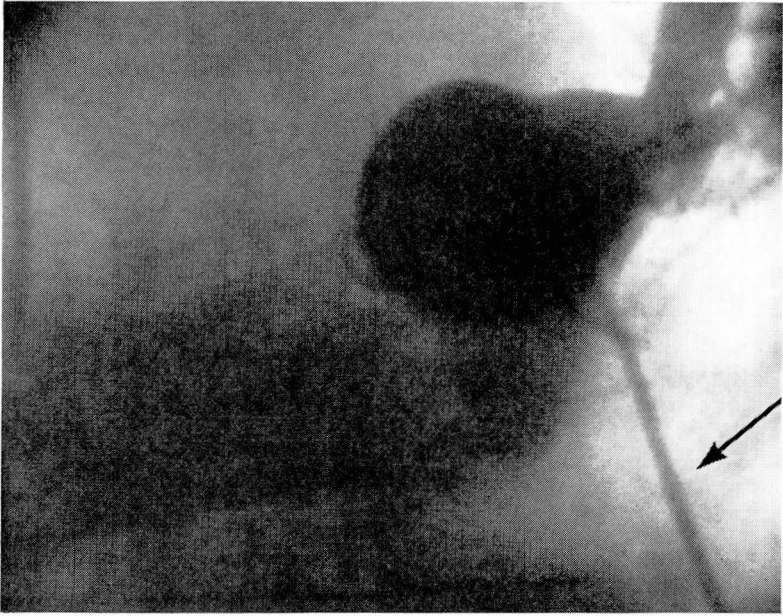

Fig. 1. Pulmonary arteriogram, frontal projection. The catheter was placed in the main pulmonary artery, its shaft is lying in the right ventricular outflow tract (arrow). The left lower pulmonary artery has been completely obstructed (right lower corner).

Blood pressures were quickly measured in the main pulmonary artery, the right ventricle, and the right atrium. The main pulmonary artery was selectively opacified with 40 ml of contrast medium (90% Hypaque sodium) injected under pressure, and was photographed in the frontal projection. After this injection the patient became intensely cyanotic; dyspnea was severe, accompanied by coughing; levarterenol bitartrate was administered and his condition improved. Television fluoroscopic monitoring of the pulmonary arteriogram suggested multiple bilateral pulmonary emboli and, pending review of the film, the patient was transferred to the operating room.

On the film there was evidence that the pulmonary arteries to the right upper and left lower pleural lobes had been totally obstructed at their origins (*Fig. 1 and 2*). The pulmonary artery to a segment of the left upper lobe and also, probably to the lingula, was severely narrowed at its origin. There was a striking delay in the passage and clearance of contrast medium through this vessel (*Fig. 3*). There was also an abnormal delay in the passage of contrast material from the pulmonary arteries of the right middle and lower lobes, suggesting significant peripheral vascular obstruction in these vessels as well (*Fig. 4*). Partial proximal obstructions in the artery to the right lower lobe were suspected.

Local anesthesia was administered and a Rochester needle was placed in the right radial artery, and the mean blood pressure was recorded between 40 and 45 mm Hg while levarterenol bitartrate was being administered intravenously. With the patient supine, the administration of the anesthetic was started, and during intubation the blood pressure became unobtainable; external cardiac massage was administered for about five minutes. A median sternotomy was performed and at the same time the left common femoral artery was exposed for arterial cannulation. The patient was heparinized and a large plastic cannula was inserted in the femoral artery. The pericardium was opened widely. A purse-string suture was placed in the right atrium and a single venous cannula was inserted. Partial circulatory bypass

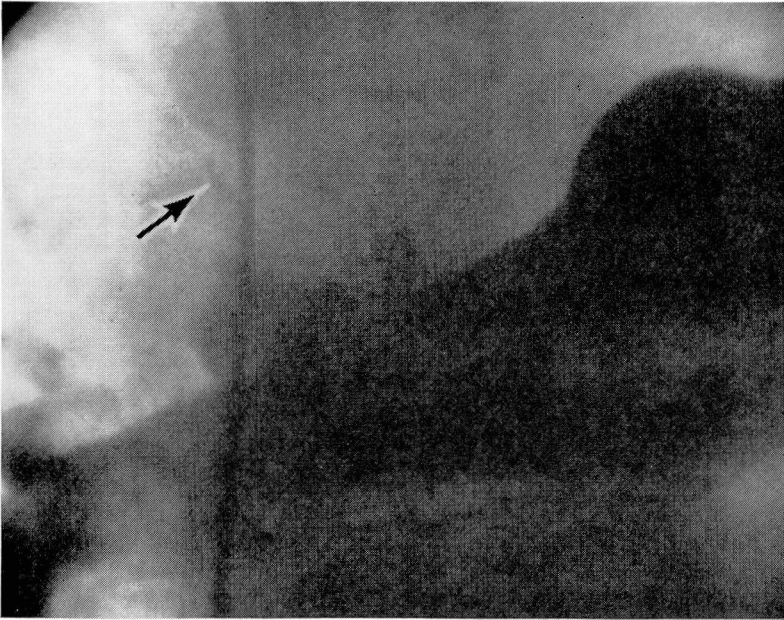

Fig. 2. Pulmonary arteriogram, frontal projection, showing the right main pulmonary artery and its primary bifurcation. The artery to the right upper lobe of the lung is completely obstructed (arrow).

was started, and the mean blood pressure was kept at about 50 mm Hg. Approximately nine minutes passed, from skin incision to partial bypass. Another venous line was then inserted in the inferior vena cava through the right atrium, and an excellent venous return was obtained. Umbilical tape was placed around the pulmonary artery, and a clamp was applied to the proximal main pulmonary artery. A transverse incision gave excellent exposure. A ring forceps was used to remove a large thrombus from the left upper lobe—one branch went down to the lingula, and another completely occluded the right upper lobe; the right lower lobe was free of thrombus. With a long rubber catheter and increased suction, we were once more able to explore the major division of the pulmonary artery, and small pieces of clot were removed (*Fig. 5*). The heart was beating during the entire procedure and the clamp on the pulmonary artery was released intermittently to prevent heart dilatation.

The pulmonary artery was closed with a running 4-0 silk suture. The mean blood pressure at the end of the procedure was between 50 and 60 mm Hg. Extracorporeal circulation was slowly withdrawn and small doses of levarterenol bitartrate were injected to maintain a good blood pressure. Decannulation was performed in the routine fashion, and the sternotomy was closed with heavy wires. A lumbar incision was made and the inferior vena cava was ligated retroperitoneally with an umbilical tape. Tracheostomy was performed. For the first 24 hours postoperatively the patient required vasopressor drugs. On the third postoperative day a fast atrial fibrillation occurred, which responded to digitalization.

The patient was discharged from the hospital on December 18, 1965, in good postoperative condition, with only mild edema of the right leg. He was readmitted to the hospital on January 1, 1966, because of another episode of pain in the chest which lasted about 12 hours. He had phlebitis of the left arm, and a course of anticoagulant therapy was started. He was discharged from the hospital on January 29, 1966, totally recuperated.

On February 2, 1966, he was readmitted to the hospital, for appendectomy. Because of

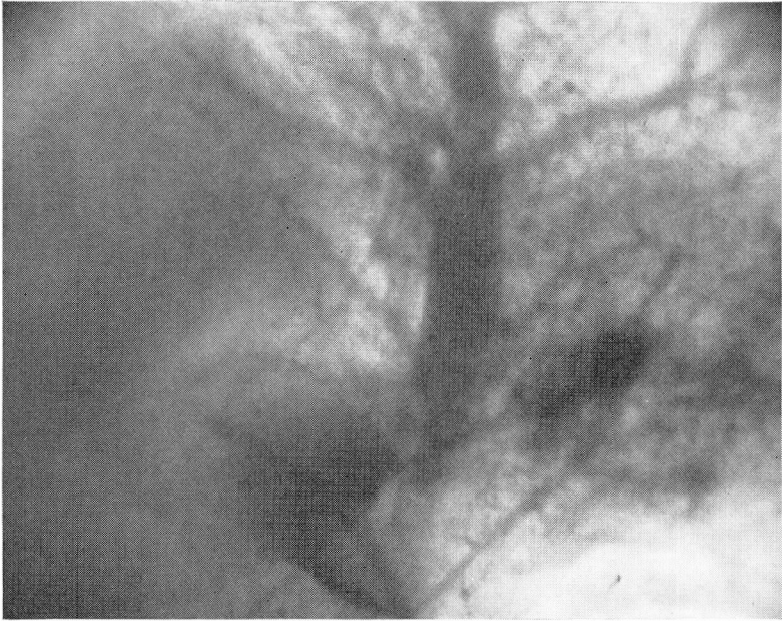


Fig. 3. Pulmonary arteriogram, showing the pulmonary arterial circulation to the left upper lobe. There was notably prolonged opacification of these vessels, persisting long after contrast material cleared elsewhere, indicating severe vascular obstruction.

acute, perforated, gangrenous appendicitis with localized peritonitis, general anesthesia was used. The patient was discharged from the hospital on February 28, 1966, doing well. At present he is again totally recuperated, with only mild edema of the right leg.

DISCUSSION

The yearly death rate in the United States from acute pulmonary embolization is about 47,000 persons.⁸ A study of 100 cases⁹ in which the patients died from massive pulmonary embolization, revealed that 29 percent survived two hours, and 10 percent for at least 10 hours; the time intervals are sufficient in which to attempt surgical treatment. In many instances the clinical picture is typical and the diagnosis can be made without difficulty. If the symptoms are not clear, radioisotope scanning, utilizing macro-aggregate human serum albumin labeled with radioiodine (I^{131}) or chromium⁵¹ (Cr^{51})^{10, 11} can be done. Most of the albumin particles become blocked in arterioles and capillaries and immediate scintiscanning can be performed. We believe that catheterization of the right side of the heart and pulmonary cineangiography is the most reliable method of diagnosing pulmonary embolism.

Hemodynamically, patients with massive pulmonary embolization have a block in the right side of the heart with concomitant systolic hypoten-

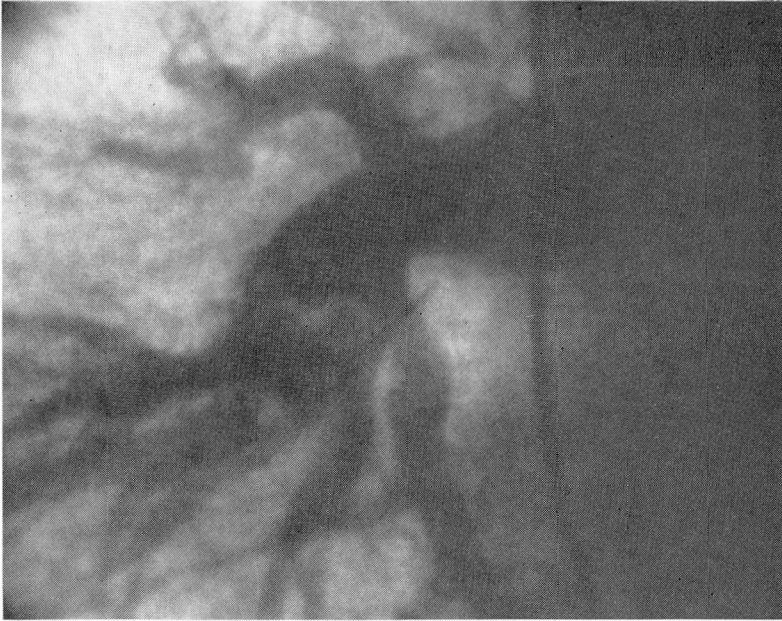


Fig. 4. Pulmonary arteriogram showing the pulmonary arteries to the right lower lobe. The blood flow through these vessels during motion study was quite slow, indicating intravascular obstruction.

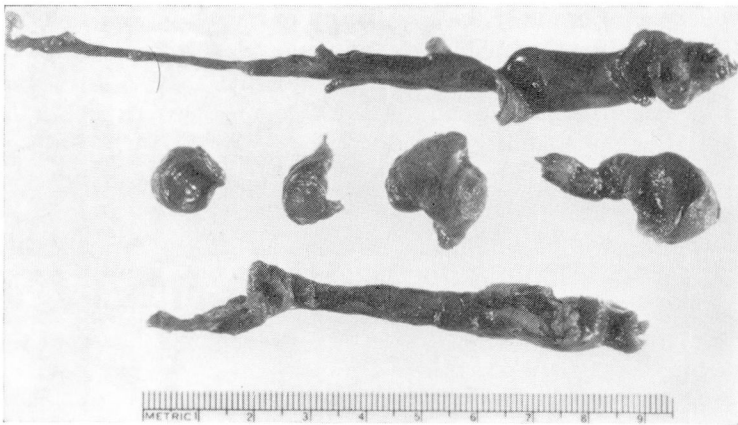

Fig. 5. Photograph of pulmonary embolus fragments removed at operation.

sion. There is disagreement among clinicians concerning the mechanical versus the reflex factors in the underlying basis for the pathophysiology. Sabiston and Wagner,¹¹ and Gorham^{12, 13} favor the mechanical concept as the primary factor. The available data suggest that arterial supply of at

least half of one lung or more is required for the production of severe signs and symptoms. Eighty-five percent of the patients who die of pulmonary embolization have had occlusion of more than one pulmonary artery. The possibility of reflex mechanism is still under discussion.¹⁴ Recently, Parmley, North, and Pickens¹⁵ have shown that the systemic hypotensive response to pulmonary embolization was reduced in severity in the animals on whom vagus transection was performed, indicating that reflexes radiated through the vagus are probably of significant importance in the genesis of this hemodynamic alteration. Experimental work with oxygen at 3 atmospheres did not ameliorate the electrocardiographic and blood pressure changes.^{16, 17} On the contrary, it increased the incidence of ventricular fibrillation. The result of this study supports the theory that prolonged arterial hypotension is the central factor in massive pulmonary embolism.

Indications for pulmonary embolectomy are hypotension, unilateral complete occlusion; bilateral incomplete occlusion; elevated blood pressure in the right side of the heart, and arterial oxygen desaturation that does not improve with the inhalation of 100 percent oxygen.¹⁸

The development of extracorporeal circulation with a disposable plastic bubble oxygenator (Travenol bag), primed with 5 percent dextrose in water or electrolyte solution, has made extracorporeal circulation immediately available for emergency embolectomy. Experimental work has shown^{19, 20} that partial cardiopulmonary bypass from the femoral vein to the femoral artery is an effective procedure with which to sustain systemic blood pressure and to increase tissue oxygenation. This method can be applied in patients with massive pulmonary embolization under local anesthesia in a few minutes, allowing enough time to perform a thoracotomy and to place the patient in total extracorporeal bypass circulation under improved hemodynamic conditions. If the venous return is not enough with a single catheter in the femoral vein, another catheter can be introduced into the superior vena cava through the jugular vein.²¹ Recent development of a portable pump oxygenator⁷ allows prompt institution of partial cardiopulmonary bypass in the patient in his room or in any part of the hospital.

SUMMARY

A case of successful pulmonary embolectomy in a 58-year-old man is reported. Pulmonary embolectomy can be successfully performed with the utilization of a disposable bubble oxygenator. Cardiopulmonary bypass can be established in a matter of minutes, and the operation can be performed under improved hemodynamic conditions, thus reducing operative mortality. Even in the gravely ill patient, peripheral partial cardiopulmonary bypass can be accomplished under local anesthesia, improving blood pres-

sure and tissue oxygenation while preparations are underway to place the patient in total extracorporeal bypass through a thoracotomy. It is important to remember that approximately 29 percent of the patients with massive pulmonary embolization survive at least two hours, a period that gives adequate time for surgical intervention. When the diagnosis is not clear, pulmonary angiography is mandatory and conclusive. A combined effort between medical and surgical teams can be lifesaving for the majority of patients.

REFERENCES

1. Trendelenburg, F: Ueber die operative Behandlung der Embolie der Lungenarterie. Arch. f. klin. Chir. **86**: 686-700, 1908; also: Deutsche med. Wchnschr. **34**: 1172-1174, 1908.
2. Kirschner, M.: Ein durch die Trendelenburgsche Operation geheilter Fall von Embolie der Art. Pulmonalis. Arch. f. klin. Chir. **133**: 312-359, 1924.
3. Steenburg, R. W., and others: A new look at pulmonary embolectomy. Surg. Gynec. & Obst. **107**: 214-220, 1958.
4. Cooley, D. A., and Beall, A. C., Jr.: A technic of pulmonary embolectomy using temporary cardio-pulmonary bypass. Clinical and experimental considerations. J. Cardiovas. Surg. **2**: 469-476, 1961.
5. Sharp, E. H.: Pulmonary embolectomy: successful removal of a massive pulmonary embolus with the support of cardiopulmonary bypass. Case report. Ann. Surg. **156**: 1-4, 1962.
6. Cooley, D. A.; Beall, A. C., Jr., and Alexander, J. K.: Acute massive pulmonary embolism: successful surgical treatment using temporary cardiopulmonary bypass. J.A.M.A. **177**: 283-286, 1961.
7. Beall, A. C., Jr., and Cooley, D. A.: Current status of embolectomy for acute massive pulmonary embolism. Am. J. Cardiol. **16**: 828-833, 1965.
8. Coon, W. W., and Willis, P. W., III: Deep venous thrombosis and pulmonary embolism; prediction, prevention and treatment. Am. J. Cardiol. **4**: 611-621, 1959.
9. Rosenberg, D. M.; Pearce, C., and McNulty, J.: Surgical treatment of pulmonary embolism. J. Thoracic & Cardiovas. Surg. **47**: 1-16, 1964.
10. Sabiston, D. C., Jr., and Wagner, H. N., Jr.: The diagnosis of pulmonary embolism by radioisotope scanning. Ann. Surg. **160**: 575-588, 1964.
11. Sabiston, D. C., Jr., and Wagner, H. N., Jr.: The pathophysiology of pulmonary embolism: relationships to accurate diagnosis and choice of therapy. J. Thoracic & Cardiovas. Surg. **50**: 339-356, 1965.
12. Gorham, L. W.: A study of pulmonary embolism. I. A clinicopathological investigation of 100 cases of massive embolism of the pulmonary artery; diagnosis by physical signs and differentiation from acute myocardial infarction. Arch. Int. Med. **108**: 8-22, 1961.
13. Gorham, L. W.: A study of pulmonary embolism. II. The mechanism of death; based on a clinicopathological investigation of 100 cases of massive and 285 cases of minor embolism of the pulmonary artery. Arch. Int. Med. **108**: 189-207, 1961.
14. Just-Viera, J. O., and Yeager, G. H.: Massive pulmonary embolism: II. Predictable mortality and cardiopulmonary changes in dogs breathing room air. Ann. Surg. **159**: 636-644, 1964.

15. Parmley, L. F., Jr.; North, R. L., and Pickens, G. E.: Pulmonary embolism as a cause of systemic hypotension and shock. *Am. J. Cardiol.* **15**: 333-344, 1965.
16. Just-Viera, J. O., and Yeager, G. H.: Massive pulmonary embolism. IV. The value of hyperbaric oxygen as therapy. *J. Thoracic & Cardiovas. Surg.* **48**: 185-199, 1964.
17. Attar, S., and others: Hyperbaric oxygenation (OHP) in massive pulmonary embolism. *Dis. Chest* **46**: 537-544, 1964.
18. Winterscheid, L. C., and others: The spectrum of patients with pulmonary embolism. *Am. J. Surg.* **110**: 247-256, 1965.
19. Beall, A. C., Jr.; Cooley, D. A., and DeBakey, M. E.: Surgical management of pulmonary embolism: experimental and clinical considerations. *Dis. Chest* **47**: 382-391, 1965.
20. Beall, A. C., Jr., and others: Resuscitation after acute massive pulmonary embolism. *J. Thoracic & Cardiovas. Surg.* **49**: 419-429, 1965.
21. Levy, J. F., and Keltner, R. M., Jr.: Improved technic of cardiopulmonary bypass for emergency pulmonary embolectomy. *Am. J. Surg.* **109**: 148-149, 1965.