

Cleveland Clinic Quarterly

Volume 34

April 1967

No. 2

The gastrocamera as an aid in diagnosis

B. H. SULLIVAN, JR., M.D.,
HENRY B. FRIEDMAN, M.D.,*
FRANCIS J. OWENS, M.D.

Department of Gastroenterology

CAREFUL and thorough trial should be given any promising new diagnostic development in regard to diseases of the stomach. Of the special examinations available, the radiographic technics are the most widely employed and generally the most useful. There are many occasions, though, when questions still remain after the radiographic examination of the stomach has been completed. A direct view of the interior of the stomach by gastroscopic examination would solve some of these problems. Just as the radiologist makes a permanent record of his fluoroscopic examinations by exposing films, the gastroscopist has thought it desirable to make photographs, but satisfactory apparatus has not been available until recently.

In 1898, Lange and Meltzing¹ published a description of an intragastric camera that they had constructed and used (*Fig. 1*). The photographic emulsions and light sources available to them were not satisfactory, and it was not until 1948 that Segal and Watson² reported that they were able to make satisfactory color photographs through the flexible gastroscope. The attachment of an electronic flash lamp on the intragastric end of the gastroscope by Debray and Housset³ made routine gastroscopic color photography practical for the average endoscopist, but the usual blind areas of the lens type of semiflexible gastroscope were a disadvantage. Fiberoptic gastroscopes with increased flexibility have reduced the size and location of blind areas and have permitted the use of an external light source of

*Fellow, Department of Gastroenterology.

This study was supported in part by a contribution from the Randall Fund.

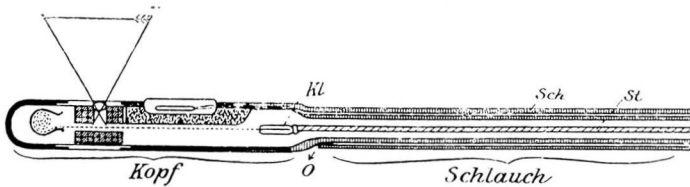


Fig. 1. Diagram by Lange and Meltzing¹ (1898) of intragastric camera. Photographic film is indicated by dotted line from film cassette on left to metal film-advancing wire (Kl). Angle of view is indicated by lines passing through the lens to the focal plane of the camera. The control tube is on the right; the external control unit is not shown. (Reproduced from Lange and Meltzing.¹)

great intensity. These changes have made possible routine still and motion picture gastric color photography with rather simple apparatus.

In 1950, Uji and Hayashida at the University of Tokyo developed the first satisfactory intragastric camera. After several modifications, the gastrocamera was approved by the Japanese Health Authorities for use in gastric cancer survey work. At the present time, 10,000 such instruments are in use, and more than 15,000 examination have been made at the University of Tokyo.⁴ According to Japanese physicians, many gastric carcinomas in early stages have been discovered by the use of these instruments.⁴

In 1962, the gastrocamera was introduced in the United States by Morrissey at the University of Wisconsin Medical School.⁵ Working with several Japanese physicians, he has used the instrument in 1500 patients.⁵ He has also trained a small number of American physicians in its use.

The Olympus GT-5 gastrocamera can be employed to photograph almost all of the interior of the stomach on a series of 32 frames of color film, each 5 mm in diameter. The instrument has a diameter of 11.5 mm and is 35 mm long (Fig. 2 and 3). Control wires pass through a connecting tube 8.5 mm in diameter to an external control box. Five different positions of the camera relative to the control tube are possible, moving the camera through an arc of 35 degrees up or down from the axis of the control tube (Fig. 4). The camera lens has a focal length of 3.6 mm, an aperture of F-17, and an 80-degree angle of view (Hirschowitz fibroscope, 36-degree angle of view; Eder-Palmer gastroscope, 54-degree angle). There is no shutter. Exposure is made by the discharge of a capacitor through a tungsten filament lamp at 40 v. Lesions 2 cm or farther from the lens are in sharp focus and the illumination is sufficient to photograph lesions that are from 10 to 12 cm from the lens.

The gastrocamera GT-5 has been in use at the Cleveland Clinic for one year. During this time, 91 gastrocamera examinations have been made, followed immediately by gastroscopy, except in three instances. Roentgenographic examination of the stomach preceded each study. This report is a review of the results in the small number of patients; we realize that a

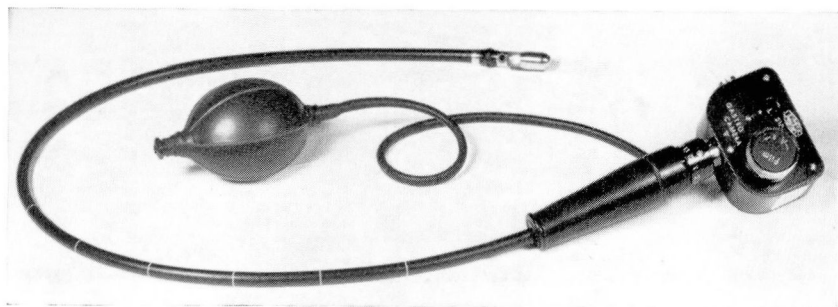


Fig. 2. Olympus GT5 gastrocamera.




Fig. 3. Olympus GT5 gastrocamera with film chamber removed. Loaded cassette and film are attached to metal film-advancing wire.

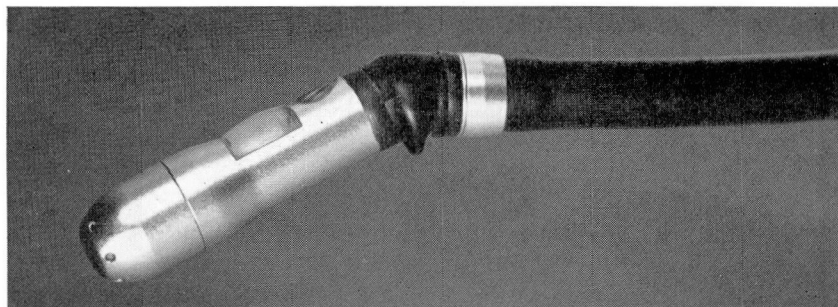


Fig. 4. Gastrocamera in "Down 2" position.

much greater experience will be required before we become sufficiently skillful to make full use of this new diagnostic instrument.

PROCEDURE

Examinations were made in the fasting patient. In a number of instances, gastric washing for exfoliative cytologic study preceded the gastrocamera examination. Premedication consisted of 75 or 100 mg of meperi-

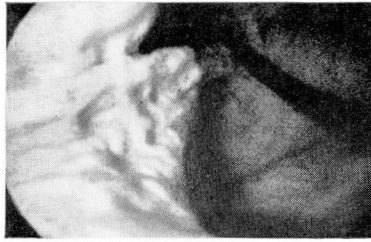


Fig. 5 Retrograde view of the gastric cardia. The control tube has entered the stomach at the cardia (top, center) and passed along the lesser curvature (right).

dine hydrochloride intravenously injected for sedation. In a few instances atropine, 0.6 mg, was given intramuscularly 30 minutes before the photographic procedure. The gastrocamera was introduced by means of the standard technic for gastroscopy: with the patient on his back, air was pumped into the stomach until a good air space was obtained. This was determined by repeatedly flashing the lamp and observing the light pattern transmitted through the anterior abdominal wall. A series of photographs was then made, the camera being rotated, and the depth and deflexion of the camera varied in accordance with a pattern developed by Morrissey and Tanaka.⁶ In a number of instances the camera was turned within the stomach to photograph retrograde views of the cardia (*Fig. 5*). After the completion of the gastrocamera photography, gastroscopy was carried out with the Hirschowitz fiberscope.

RESULTS

None of the patients experienced harmful effects as a result of this examination. Six of the film strips were totally unsatisfactory for various reasons: insufficient inflation of the stomach in five patients, film lost in the mail in one case. In a number of other instances mucus, retained secretions, or fluid used for gastric lavage complicated the interpretation of the pictures. The photographs made recently are much superior to those of our early efforts, and they depict a larger area of gastric mucosa and are less apt to contain distracting mucus or secretions. We were successful in turning the gastrocamera to obtain photographs of the cardia, in seven of eight patients by using fluoroscopic control, and in seven of eight patients without using the fluoroscope.

The frequency with which the gastrocamera pictures confirmed the final diagnosis in these cases is shown in *Table I*. This tabulation does not represent a final estimate of the accuracy of each of the methods for several reasons. Most of these patients were examined because the results of roentgenographic examinations suggested the possibility of lesions or were not conclusively normal.

Table 1.—*Diagnoses of gastric disease by gastrocamera, gastroscopy, and roentgenographic examinations of 91 patients*

Final diagnosis		Patients, number			
		Total	Diagnosis confirmed by		
			Gastrocamera	Gastroscope	Roentgenograms
Normal		18	17	14	9
Ulcer		40			
Gastric	36		15	23	26
Marginal	4		3	4	2
Neoplasm*		17	13	15	15
Gastritis		12			
Postoperative	2		2	2	—
Hypertrophic	3		2	1	—
Atrophic	7		7	5	—
Polyp		4	3	2	3
		—	—	—	—
Total		91	62	66	55

* All carcinoma except 3: 1 leiomyoma, 1 reticulum cell sarcoma, 1 lymphoma.

The gastrocamera demonstrated only 15 of the 36 gastric ulcers in the series. Nine of the ulcers that were missed were in the prepyloric region; three of the ulcers were in the antrum, and the stomach was not inflated sufficiently to obtain good photographs. One ulcer on the greater curvature was missed, as well as one on the posterior wall of the stomach. One ulcer, well demonstrated on roentgenograms to be high in the stomach near the fundus, was sought by gastrocamera examination and gastroscopy by turning the instrument to demonstrate the cardia and fundus. Although these maneuvers were successfully accomplished, the ulcer was not photographed or demonstrated, but its presence was confirmed at laparotomy.

Marginal ulcer was demonstrated in three of four patients by gastrocamera photographs. A special technic and a certain amount of luck is required to demonstrate ulcers either by gastrocamera or by gastroscopy, but gastrophotography has proved a worthwhile method in our experience.

The demonstration of gastritis is not in the province of the radiologist. Inflammatory mucosal change both in the stomach and in the jejunum was noted postoperatively in two patients; hypertrophic gastritis was found in two of three patients and atrophic gastritis in seven of seven patients. The use of the gastrocamera with its excellent demonstration of the upper portion of the stomach has led to a change in our concept of "atrophic gastritis." In each of 30 of the patients examined, large patches of pale

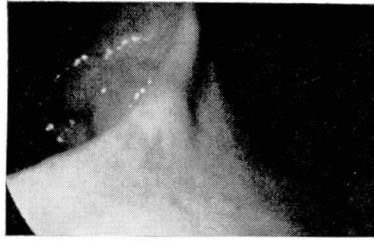


Fig. 6. Nodular adenocarcinoma infiltrating the angulus (center) and the antrum (left).

mucosa were seen in the upper portion of the stomach. Arteries, veins, and capillaries showed clearly through the mucous membrane. A normally thin membrane, stretched by the gastric inflation necessary for photography, probably explains this effect. We now regularly confirm this observation at gastroscopy, and consider it normal as long as the changes are confined to the upper third of the stomach.

Four patients with gastric polyps were seen and the polyp photographed in three. All of the lesions were thought to be benign; none were removed.

Seventeen of the patients each had a neoplasm: adenocarcinoma, reticulum cell sarcoma, lymphoma, or leiomyoma. The gastrocamera photographs demonstrated the lesions in 13 of the patients (*Fig. 6*). The stomach wall often is not readily distensible, and then photography may be difficult to accomplish; this was the reason for the failure to demonstrate two of the neoplasms.

DISCUSSION

In our first efforts the gastrocamera as a diagnostic tool has been a little less accurate than the gastroscope. The difference between the technics lies largely in the failure of the gastrocamera to demonstrate ulcers in the prepyloric region of the stomach. Spasm that is proximal to the ulcer has prevented successful photography, and less often, gastroscopic demonstration. We believe that our technic is improving and will continue to do so. The gastroscopist has the advantage in that he may continue his efforts until he sees the ulcer. The gastrocamera operator cannot be sure of his results until the film has been processed and returned to him. This difficulty can be avoided by the use of the Olympus GTF fiberoptic gastroscope with incorporated gastrocamera. Inspection of the stomach is continued until the lesion is identified and photographed. The advantages of a fixed-focus lens of short focal length and of great depth of field are retained. The camera photographs a much larger region than is seen through the gastroscope, and some lesions will be demonstrated on the film which were not seen during gastroscopy. An even newer instrument has a direct-

able tip that will permit the fiberoptic gastroscope-gastrocamera combination to be turned within the stomach so as to make retrograde views of the cardia.

The gastrocamera has proved useful in the series of 91 patients for several reasons. (1) The principal advantage to the patient is that the gastrocamera can be made to photograph regions that are not seen by means of the gastroscope and which are sometimes difficult for the radiologist to examine satisfactorily. The cardia and the fornix of the stomach are examples of such regions. We now feel confident of our ability to turn the gastrocamera in the stomach and to make good photographs of the region of the cardia. We are not yet confident that we can photograph the entire fornix of the stomach and be absolutely certain that no area remains unexplored. (2) The gastrocamera provides a permanent record that can be studied and reviewed at a date later than that of the examination and may also be reviewed by persons who were not present at the examination. Many of our photographs have been reviewed by Dr. John F. Morrissey at the University of Wisconsin, who has given us helpful advice in regard both to interpretation and to technic. His suggestions have been an important factor in the improvement in our results. (3) Even this small series of films constitutes a 'teaching' file for the instruction of students of gastroscopic examination. The color rendition of the gastric mucosa is excellent; the definition is sharp; and the technical qualities of the photographs are superior. A good film strip covering the interior of the stomach exposed in an orderly fashion is a great help in orientation, a difficult aspect of gastroscopy.

Our experience has been with the day-to-day case load of symptomatic patients, often with positive or equivocal roentgenograms. Many patients had well-established or advanced disease. If the gastrocamera is an accurate diagnostic instrument, it might be well to use it in patients who have normal structures according to the roentgenograms. The Japanese have developed the gastrocamera in the hope that they will be able to detect carcinoma of the stomach while it is still confined to the mucosa and where a high surgical cure rate is possible. They use the gastrocamera as a survey instrument in patients undergoing routine physical examination or who for any reason become suspect as harboring carcinoma of the stomach.

SUMMARY

Ninety-one gastrocamera examinations were made at the Cleveland Clinic in the last year. The results of these examinations are compared with those of roentgenographic and gastroscopic examinations on the same patients. The diagnostic accuracy of the gastrocamera was not so great as that of gastroscopy, largely because of failure to demonstrate prepyloric and antral gastric ulcers. The failure was largely due to the operators' inexperience

in the application of the technic. The gastrocamera offers the best method to date of examining the cardia and fornix of the stomach. No significant lesions were demonstrated in this location in our series of patients. We find sufficient merit in this method of examination to warrant continued use of the gastrocamera as a clinical diagnostic instrument.

ACKNOWLEDGMENTS

The authors herewith express their thanks to John F. Morrissey, M.D., Department of Medicine, University of Wisconsin Medical School, Madison, Wisconsin, for his encouragement, instruction, and cooperation in this study; and to Mrs. Irene Spada, R.N., who gave valuable technical assistance throughout the study.

REFERENCES

1. Lange, F., and Meltzing: Die Photographie des Mageninnern. München. med. Wchnschr. **45**: 1585-1588, 1898; also Internat. phot. Monatschr. f. Med., München, **51**: 31, 1899.
2. Segal, H. L., and Watson, J. S., Jr.: Color photography through the flexible gastroscope. Gastroenterology **10**: 575-585, 1948.
3. Debray, Ch., et Housset, P.: La gastrophotographie au flash électronique et la gastrocinématographie à l'aide du gastroscope flexible. Premiers documents en couleurs. Ann. oto-laryng. **74**: 209-212, 1957.
4. Tasaka, T.: Personal communication to one of the authors (B. H. S.), September 20, 1966.
5. Perna, G; Honda, T., and Morrissey, J. F.: Gastrocamera photography. Arch. Int. Med. **116**: 434-441, 1965.
6. Morrissey, J. F., and Tanaka, Y.: Personal communication to the authors, November 1965.