

Cleveland Clinic Quarterly

Volume 35

January 1968

No. 1

The diagnosis of carpal tunnel syndrome

GEORGE S. PHALEN, M.D.

Department of Orthopedic Surgery

COMPRESSION of the median nerve in the carpal tunnel is the most common cause of pain, numbness, and tingling in the thumb, and index, middle, and ring fingers. Despite the frequency of this syndrome, many patients each year are referred to me because of median nerve compression at the wrist which has not been diagnosed correctly. Some of these patients have had long courses of physical therapy treatments on their necks, and some have in vain undergone scalenotomy or cervical laminectomy in an effort to obtain relief from the burning pain and numbness in their fingers. Other patients have been referred to a psychiatrist because the examining physician made the diagnosis of a purely functional disorder.

The diagnosis of carpal tunnel syndrome is not difficult to make if one remembers to include this condition in the differential diagnosis of pain and numbness in the hand. When a physician has seen a patient with carpal tunnel syndrome and has treated this patient successfully, the physician will not miss the diagnosis in subsequent patients. There are no more grateful patients than those who endured, for many years the pain and numbness in their fingers and who have been relieved by surgical decompression of the median nerve in the carpal tunnel.

Any condition that alters the contour or increases the contents of the carpal tunnel may press the median nerve against the transverse carpal ligament. This pressure on the median nerve produces a compression neuropathy that is manifested by motor and sensory changes in the median distribution in the hand.^{1, 2} The sensory distribution of the median nerve includes the lateral half of the palm, the lateral half of the ring finger, and the volar aspect of the entire middle finger, the index finger, and the thumb. Although the median nerve may anastomose to a variable extent

with the ulnar nerve in the hand, the intrinsic muscles usually innervated by the median nerve include the opponens, the short flexor, and the short abductor muscles of the thumb. Of these three muscles, the opponens pollicis is the one that usually receives its entire motor supply through the median nerve.

Within the carpal tunnel, and beneath the median nerve, lie nine flexor tendons passing to the digits of the hand. These tendons are covered by a thin synovialis. It is a thickening of this flexor synovialis which in most cases causes the carpal tunnel syndrome.^{3, 4} The thickening is usually a simple fibrosis of nonspecific origin, but it may be associated with trauma or with rheumatoid arthritis.

The carpal tunnel syndrome is more common in women than in men. In a series of 439 patients with this syndrome seen at the Cleveland Clinic before August 1, 1964, 67 percent were women.⁴ Of the patients in this same series, 75 percent were between the ages of 40 and 70 years. This syndrome is considered to be one that largely affects the postmenopausal woman.

ONSET AND COURSE

The patient with carpal tunnel syndrome usually gives a history of progressive clumsiness and weakness in using the hands, together with numbness and tingling in the median distribution distal to the wrist joint. Occasionally there may be some aching or pain radiating up the forearm or even to the shoulder, but there never are sensory changes proximal to the wrist.

Rarely is there a history of injury.^{3, 4} Of 439 patients there were 70 (16 percent) who gave a history of trauma preceding the onset of symptoms. Of these 70 patients, 21 had recently used their hands excessively in their work. From these figures one may readily see that local trauma to the wrist is seldom an etiologic factor in the production of the carpal tunnel syndrome. However, usually the patient's symptoms will be more severe in the dominant hand—the hand that is used the most with daily activities.

Pain at night is a frequent complaint, and this pain is often severe enough to prevent sleep. Placing the hand in cold water or simply shaking the hand vigorously may alleviate the discomfort to some extent. This symptom is described as a "waking numbness" and is highly characteristic of carpal tunnel syndrome. I believe that this waking numbness is caused by swelling of the flexor synovialis produced by the peripheral vasodilatation that always occurs during sleep.

Only occasionally will a patient give a history indicative of progressive atrophy of the thenar muscles in the hand. Usually this atrophy is slight, and will have to be brought to the attention of the patient by the examining physician.

At least two thirds of the patients with carpal tunnel syndrome have had symptoms of more than six months' duration, and many will have had from 10 to 20 years of suffering.

PHYSICAL EXAMINATION

Hypesthesia in the median distribution of the hand is the most constant of all clinical findings in carpal tunnel syndrome. Some degree of hypesthesia in the isolated supply of the median nerve—the tip of the middle finger—is almost always present. Occasionally there will be no numbness in the hand at the time of the examination, but when the patient is asked to outline on her hand the area that becomes numb and painful, it will always be the area supplied by the median nerve. The patient may say, "The whole hand goes to sleep"; but closer questioning will reveal that the little finger is really not affected. The little finger receives its entire nerve supply through the ulnar nerve and is never involved in carpal tunnel syndrome. There are never any objective sensory findings proximal to the wrist joint.

In patients with carpal tunnel syndrome, tapping *gently* over the median nerve at the wrist will produce pain radiating into the fingers supplied by the median nerve. This is Tinel's sign and is indicative of some irritation of the median nerve. The examining physician must remember that vigorous or prolonged tapping over a normal median nerve will produce the same symptoms and this must not be interpreted as the presence of Tinel's sign.

Atrophy of the three thenar muscles supplied by the median nerve will be present in almost half of the patients who have carpal tunnel syndrome. This atrophy will be present in various degrees and is usually preceded by hypesthesia in the median distribution for many months or many years. The patient herself may not have noticed the atrophy, even though it is far advanced. On looking down on the palm of the hand, one may often fail to observe the thenar atrophy that is readily apparent when the profiles of the two thumbs are compared (*Fig. 1 A and B*).

A highly helpful diagnostic sign is the *wrist-flexion test*. The patient is asked to flex both wrists completely and to keep them flexed for approximately 60 sec. In this position, the median nerve is pressed upon by the proximal edge of the transverse carpal ligament. Even in the normal wrist, prolonged complete flexion of the wrist will eventually cause numbness in the median distribution in the hand. In cases of carpal tunnel syndrome there usually is a prompt exacerbation of numbness and tingling in the median distribution in the hand. Within 30 sec, the patient often will say, "The pain is coming in my fingers now; this is the pain that wakes me up at night."

In the interpretation of the wrist-flexion test, the clinician must re-

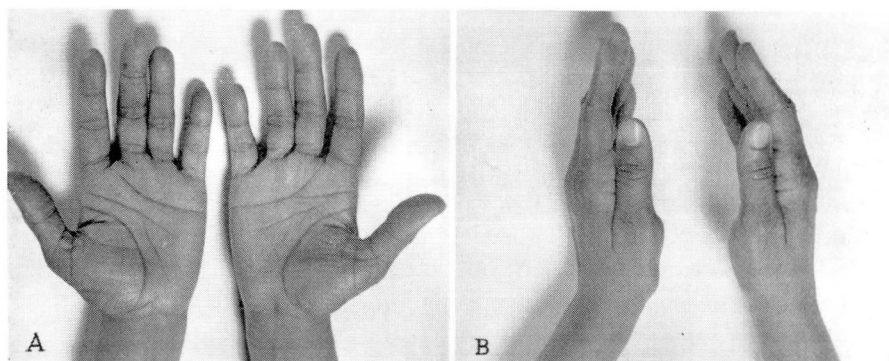


Fig. 1. A, Photograph of hands of a woman, aged 46 years, with bilateral carpal tunnel syndrome. She had not observed the atrophy present in the proximal portion of the left thenar eminence. B, Comparison of the thenar eminences in profile emphasizes the presence of thenar atrophy. (Courtesy of Phalen, G. S., and Kendrick, J. I.: Compression neuropathy of the median nerve in the carpal tunnel. *J. Amer. Med. Assn.* **164**: 524-530, 1957; and *The Journal of The American Medical Association*.)

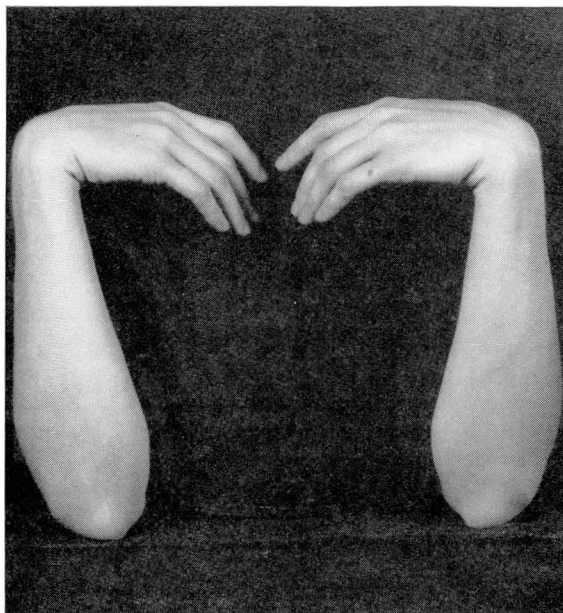


Fig. 2. Photograph showing the wrist flexion test. The test is positive when the patient mentions the increased numbness or tingling in the median nerve distribution in the hand when the wrists are held completely flexed for from 30 to 60 sec.

member that the test will be invalid when there is an advanced degree of sensory loss in the hand or when there is great restriction of motion in the wrist joint from some previous injury or disease.

If there is sufficient thickening of the flexor synovialis, there may be an obvious swelling on the volar aspect of the forearm proximal to the wrist. This is often seen in patients with carpal tunnel syndrome who also have rheumatoid arthritis.

Roentgenograms of the wrist are seldom helpful in making a diagnosis of carpal tunnel syndrome. In cases of trauma, roentgenograms of the wrist may show an alteration in the contour of the carpal tunnel.

Electrodiagnostic studies may be of great help in establishing the diagnosis of compression neuropathy of the median nerve in the carpal tunnel, especially in patients who have only subjective signs. The median nerve is stimulated with a bipolar electrode at the proximal flexion crease of the wrist and a recording is made of the time required for the appearance of the muscle action potential of the opponens pollicis. This conduction delay, or latency period, should normally be 5 msec or less. A longer latency period is indicative of some involvement of the median nerve in the carpal tunnel.

The injection of a small amount of a long-acting corticosteroid into the carpal tunnel may serve as a good diagnostic test as well as excellent treatment for the carpal tunnel syndrome. When the condition has been present for only a short period, a single injection may reduce the swelling of the flexor synovialis so that the patient has no further symptoms. The patient will usually notice some improvement within from 24 to 48 hours after the injection. An injection of from 0.5 to 1.0 ml of triamcinolone acetonide or methylprednisolone acetate is given through a 25-gauge needle inserted just medial to the insertion of the palmaris longus tendon at the wrist. The needle is moved about slightly as the solution is injected so that the material will not be placed within a single tendon. Care must be taken also to avoid injecting the fluid into the median nerve. The injection should be almost painless, even without a preliminary wheal of procaine hydrochloride.

If the injections give prompt and lasting relief and if there is no evidence of atrophy of the thenar muscles, surgical treatment may be delayed. I tell the patients, however, that I shall not give them more than three injections at from 7 to 10 day intervals before recommending that the median nerve compression be cured by sectioning of the transverse carpal ligament.

SUMMARY

The diagnosis of carpal tunnel syndrome is made on the basis of a positive wrist flexion test, the presence of Tinel's sign over the median nerve at the wrist, and the restricting of all objective sensory findings to the median distribution in the hand. These are the three most reliable

PHALEN

clinical findings, and usually two of these findings are present in every patient who has carpal tunnel syndrome. In addition, some degree of atrophy of the thenar muscles will be present in half of the patients.

The injection of a corticosteroid preparation into the carpal tunnel is good treatment as well as a good diagnostic test for compression of the median nerve in the carpal tunnel. In the occasional patient in whom the diagnosis is still in doubt, electrodiagnostic studies may be helpful.

REFERENCES

1. Phalen, G. S.; Gardner, W. J., and LaLonde, A. A.: Neuropathy of the median nerve due to compression beneath the transverse carpal ligament. *J. Bone Joint Surg.* **32-A**: 109-112, 1950.
2. Phalen, G. S.: Spontaneous compression of the median nerve at the wrist. *J. Amer. Med. Assn.* **145**: 1128-1132, 1951.
3. Phalen, G. S., and Kendrick, J. I.: Compression neuropathy of the median nerve in the carpal tunnel. *J. Amer. Med. Assn.* **164**: 524-530, 1957.
4. Phalen, G. S.: The carpal-tunnel syndrome. Seventeen years' experience in diagnosis and treatment of six hundred fifty-four hands. *J. Bone Joint Surg.* **48-A**: 211-228, 1966.