

Clinicopathologic assessment of twenty-six cases of rhabdomyosarcoma

EYAD CHATTY, M.D.*

WILLIAM A. HAWK, M.D.

Division of Pathology

IN 1854, according to Stout,¹ Weber reported a case of rhabdomyosarcoma in the tongue of a young man. In 1946, Stout¹ reviewed 107 previously reported cases, added 17 new ones, and clarified the characteristics of the neoplasm for the first time. In 1950, Stobbe and Dargeon² reported 15 cases, classifying the neoplasms as embryonal rhabdomyosarcomas. In 1956, Riopelle and Theriault³ reported six cases of a peculiar, but distinctive, form that they called alveolar rhabdomyosarcoma. In 1958, Horn and Enterline⁴ reported 39 cases, and classified these tumors into four categories: embryonal, alveolar, pleomorphic, and botryoid.

Rhabdomyosarcoma was believed to be a rarity, but in the last decade it has been reported to occur in almost every part of the body: extremities,^{1, 4-9} trunk,^{1, 4, 5, 7, 8} abdomen,^{1, 4, 5, 7, 8} lung,¹⁰ soft tissues of the head and neck,^{1, 4, 5, 7, 8, 11, 12} orbit,¹³⁻¹⁵ major salivary glands,¹⁶ soft palate,¹⁷ middle ear and mastoid,¹⁸ bladder,¹⁹⁻²¹ testis,²² ovary,²³ and the common bile duct.⁴ It was also reported to occur in every age group from birth⁴ to the age of 90 years.¹⁹ Prognosis and methods of treatment were discussed recently by Burgert and Mills²⁴ and by Martin, Butler, and Albores-Saavedra.²⁵

We have studied 26 cases at the Cleveland Clinic, and the series is the basis of this report. Cases of sarcoma botryoides of the female genital tract and of other sites have not been included, because we believe that those tumors should be called mixed mesodermal tumors.

METHODS AND MATERIAL

During the years 1945 through 1967, 26 cases of rhabdomyosarcoma were diagnosed at the Cleveland Clinic. The ages of the patients ranged from eight months to 81 years. The majority of the resected specimens were fixed in Zenker's solution; a few were fixed in formalin. All slides were stained with hematoxylin and eosin and phosphotungstic acid and hematoxylin. The majority of the slides were also stained with Masson's trichrome stain. Periodic acid—Schiff preparations, both digested and undi-

* *Fellow, Division of Pathology.*

gested with diastase, and those treated with reticulum stain, pyronine, toluidine blue, Verhoeff's stain, Sudan IV, and Prussian blue were also used.

MACROSCOPIC FEATURES

Sarcomas arising from skeletal muscle were pleomorphic in their gross appearance. Most of the rhabdomyosarcomas were grayish-pink, soft, and rather fleshy. Sizes ranged from several millimeters to 15.0 cm in diameter; the large lesions were located in the buttock. Some neoplasms were nodular or lobulated, and a few were each well circumscribed and partially surrounded by a pseudocapsule of compressed adjacent fibrous tissue. Necrosis and hemorrhage were extensive in some neoplasms, particularly the large tumors. A portion of the embryonal tumors were myxomatous, while most of the alveolar tumors were somewhat solid.

MICROSCOPIC FEATURES

Rhabdomyosarcoma is composed of primitive striated muscle cells that are quite similar to the skeletal muscle cells of the human fetus and embryo ranging in age from 6 to 10 weeks. This resemblance had been previously reported by Patton and Horn.²⁶ These cells may assume one of two main types: undifferentiated mesenchymal cells, and rhabdomyoblasts.

The mesenchymal cells appear in five subtypes: small round, large round, spindle, oval, and syncytial. The small round cells have a central hyperchromatic nucleus surrounded by a small amount of cytoplasm that stains lightly basophilic with hematoxylin and eosin stain. A distinct cytoplasmic border is seen in the majority of cells. The large round cells each contain a central nucleus, usually rather vesicular with scattered chromatin, often with a prominent nucleolus. The cytoplasm is moderate in quantity and of a pink tint. The borders range between definite and vague. The oval cells are like the large round cells, usually with ill-defined borders. Spindle cells are elongate and fusiform each with a central nucleus that usually expands the cell in the center, but in some instances is present at one pole of the cell, imparting a racquet shape. The nucleus is vesicular with scattered chromatin and a nucleolus, but it may be hyperchromatic. There is a moderate amount of cytoplasm and it is basophilic with a pink tint. The syncytial cells have multiple, usually hyperchromatic nuclei, and abundant basophilic cytoplasm with well-defined borders.

Rhabdomyoblasts also appear in five subtypes: round, straplike, racquet-shaped, giant, and spider cells. All of these have an eosinophilic cytoplasm because of the presence of myoglobin. They may all have cross and longitudinal striations, and the borders are usually well defined. The most common type of rhabdomyoblasts are round cells, usually large, and with central or eccentric hyperchromatic nuclei with a moderate to strikingly

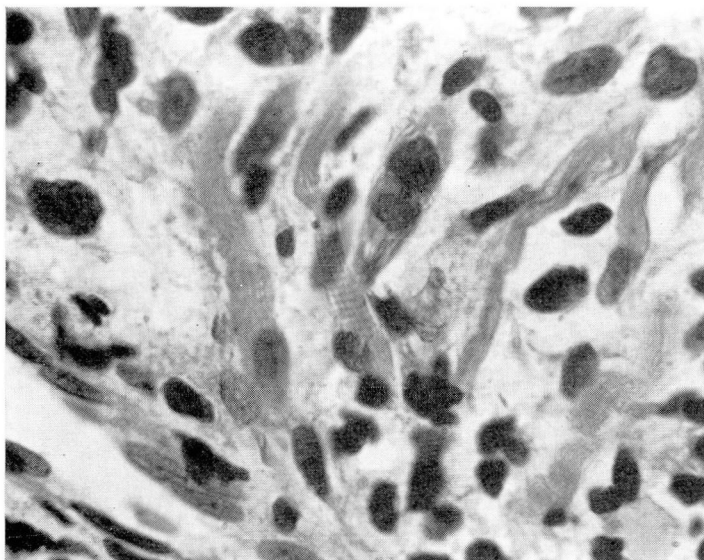


Fig. 1. Case 7 (Table 1). Multinucleated strap-shaped cells with cross striations in a specimen of pleomorphic rhabdomyosarcoma. Hematoxylin and eosin stain; magnification $\times 750$.

abundant amount of cytoplasm. The most characteristic rhabdomyoblasts are straplike cells, elongated, often with multiple nuclei arranged in tandem, with cross striations more often than any other rhabdomyoblast (Fig. 1). The racquet-shaped cells each have a hyperchromatic nucleus at one end, with a tapering cytoplasmic body extending outward. The giant cells are composed of a large mass of eosinophilic cytoplasm with multiple nuclei scattered throughout. The spider cells are large, each with a central, hyperchromatic nucleus with cytoplasmic stripes extending from it to the outer cellular border. These stripes are separated by large cytoplasmic vacuoles. The spider cells are also characteristic of rhabdomyosarcoma, but are only occasionally present (Fig. 2).

HISTOLOGIC TYPES

Three microscopic types of rhabdomyosarcoma are well known: embryonal, alveolar, and pleomorphic. A fourth type may be added, which is a combination of the first two, and is listed as embryonal-alveolar in this report. The diagnosis of each of these four types is based upon the predominant type of mesenchymal and rhabdomyoblastic cells present, as well as on the arrangement of the cells. Any type of mesenchymal cells and rhabdomyoblasts may be present in a specific rhabdomyosarcoma, but there is always one type of undifferentiated cell as well as one type of rhabdomyoblast which predominates. In cases of great pleomorphism, and

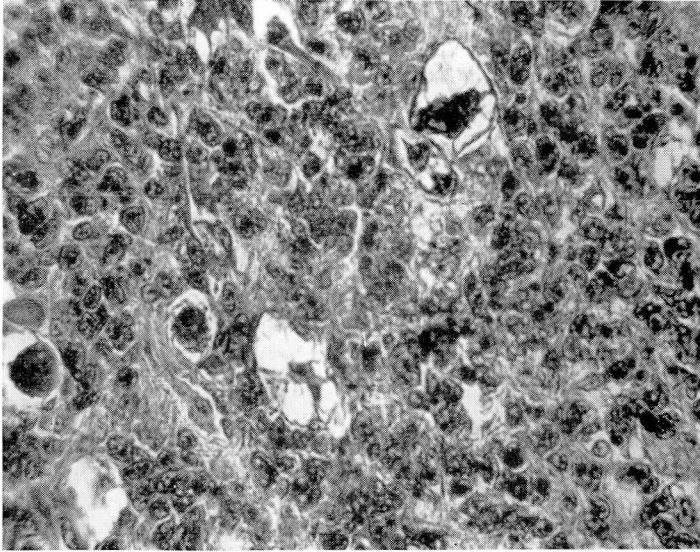


Fig. 2. Case 17 (*Table 1*). Spider cells in a specimen of embryonal rhabdomyosarcoma. Hematoxylin and eosin stain, magnification $\times 400$.

in the absence of a predominant cell, the diagnosis of the pleomorphic type is appropriate.

Longitudinal and cross striations frequently are rare in a tumor. Striations were present in 13 of 26 tumors. In 11 of these tumors the cross striations were found on hematoxylin and eosin preparations, while phosphotungstic acid—hematoxylin was the only stain helpful in regard to two tumors. The Masson trichrome stain demonstrates the alveolar type. A few periodic acid—Schiff positive granules were found in some unevenly distributed cells, mainly in the embryonal type of tumor. These granules were diastase sensitive, which suggests that they contained glycogen. The fluorescent antibody technic²⁶ demonstrated that these cells also contain myosin.

Embryonal rhabdomyosarcoma. This tumor was composed mainly of spindle-shaped to oval cells with round rhabdomyoblasts, a few racquet-shaped blasts, and rarely giant cells and spider cells. The background was myxomatous, but solid sheets of cells were also present (*Fig. 3*). The cells were arranged in parallel or interlacing bundles. The cambium layer of Nicholson was present in some of these tumors. Cross striations were present in 7 of the 14 embryonal tumors.

Alveolar rhabdomyosarcoma. In this neoplasm the predominant cells were round, occasionally oval, while the blasts were a mixture of the large round cells and giant cells, racquet-shaped cells, and a few straplike cells

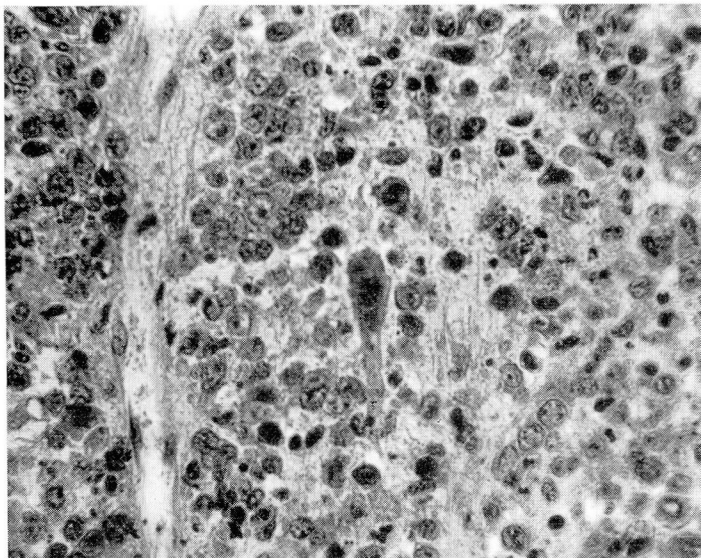


Fig. 3. Case 23 (*Table 1*). Embryonal rhabdomyosarcoma. Phosphotungstic acid and hematoxylin stain; magnification $\times 400$.

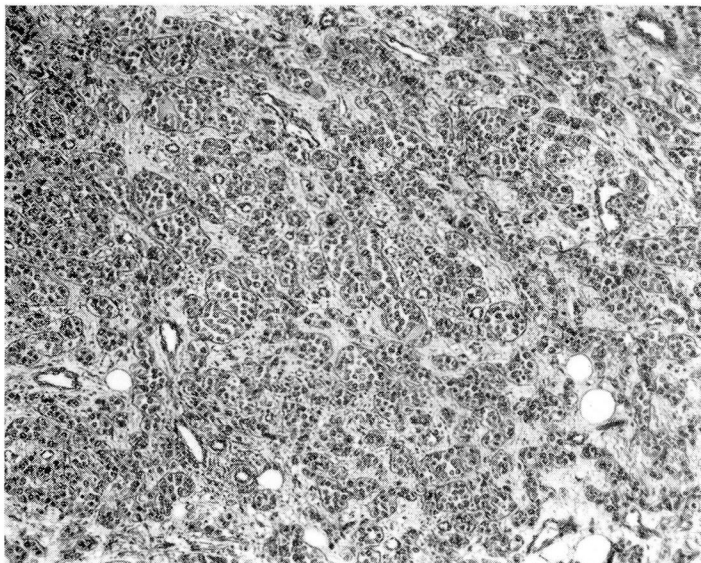


Fig. 4. Case 16 (*Table 1*). Alveolar rhabdomyosarcoma. Masson trichrome stain; magnification $\times 100$.

with multiple nuclei. The most characteristic feature was the arrangement of the small round cells in one or two rows on the inside aspect of the connective tissue septa that formed the template for the alveolar pattern (Fig. 4). It has been suggested that these septa possibly are composed of immature muscle fibers, and that the round cells are nuclei that are budding from these fibers.⁴ Our observations show that the septa stained green with the Masson trichrome stain, a characteristic of connective tissue, and not light brown in the manner of muscle fibers. Cross striations were found in one of these four neoplasms.

Pleomorphic rhabdomyosarcoma. Typically, this tumor consisted predominantly of spindle-shaped cells. All other types of mesenchymal cells were present, but in various proportions. Rhabdomyoblasts were present, the predominant types being the straplike cells and spider cells (Fig. 5). Cross striations were demonstrated in five of the six tumors.

Embryonal-alveolar rhabdomyosarcoma. This neoplasm was a mixture of the first two types, with predominance of the embryonal pattern (Fig. 6). No cross striations were seen in the two examples of this type in the series.

CLINICOPATHOLOGIC CORRELATION

Embryonal rhabdomyosarcoma. Fourteen patients, seven males and seven females, had embryonal rhabdomyosarcoma. The youngest patient was eight months of age and the oldest 69 years old. The average age at the onset of symptoms was 22 years, while the average length of survival after diagnosis was 21 months. The longest period before diagnosis was 20 months.

The site of the primary neoplasm was the genitourinary tract in three patients. The lower extremities, the maxillary and mandibular regions, the orbit, and the right upper abdominal cavity were the sites of two tumors each. One patient each had a tumor in the back, the soft tissues of the head and neck, and the prostate.

The best method of treatment of these patients was a combination of wide surgical excision followed by radiation and chemotherapy. This method resulted in a five-year survival of a 69-year-old woman (case 11, Table 1) with a lesion in the urethra. A combination of wide surgical excision and radiation resulted in a four-year survival of a four-year-old boy (case 20, Table 1) with a lesion in the nose.

Cross striations were demonstrated in seven of these 14 tumors.

Alveolar rhabdomyosarcoma. Four patients, three males and one female, had alveolar rhabdomyosarcoma. Their ages ranged from 8 to 68 years. The interval between onset of symptoms and diagnosis was between one month and two months. In one patient the prostate was affected, whereas in the other three patients, the tumors were in the head and neck: one in the soft tissue of the neck, one in the paranasal region, and one in the mandib-

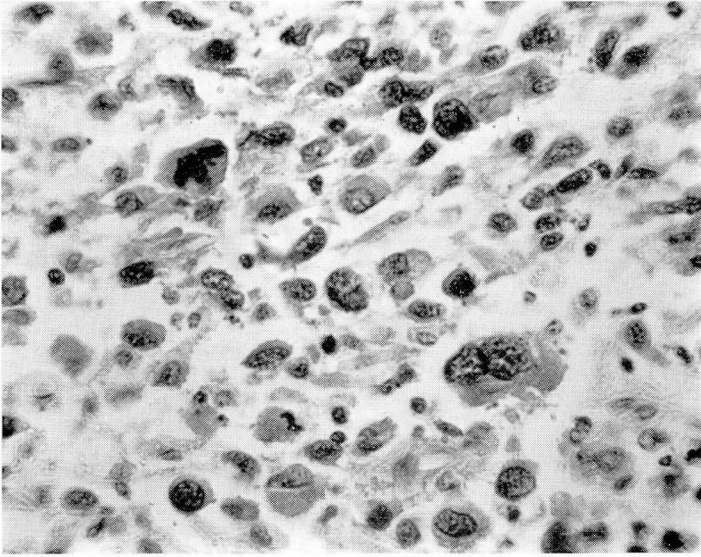


Fig. 5. Case 21 (*Table 1*). Pleomorphic rhabdomyosarcoma. Hematoxylin and eosin stain; magnification $\times 400$.

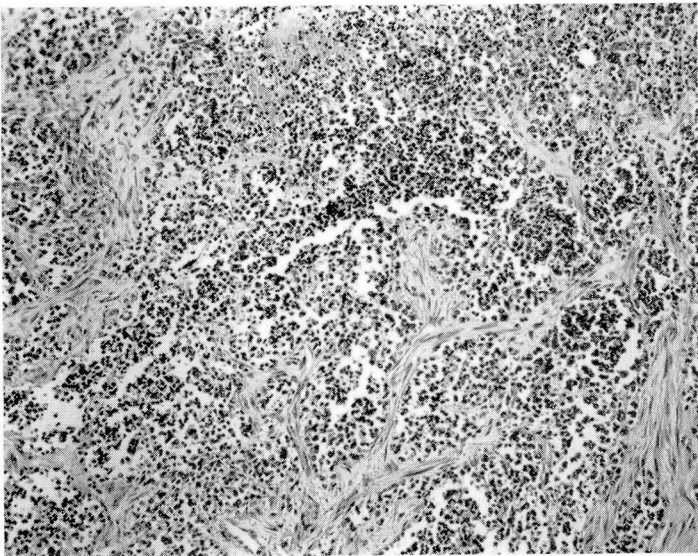


Fig. 6. Case 14 (*Table 1*). An alveolar pattern is in both upper right and upper left corners of the photomicrograph, while a diffuse embryonal pattern is in the lower half. Masson trichrome stain; magnification $\times 100$.

Table 1.—Clinical and pathologic features of 26 cases of rhabdomyosarcoma

Case no.	Age, years	Sex	Duration before diagnosis, months	Site	Rhabdomyosarcoma				Treatment	Survival after diagnosis
					Type	Cross striae, present	Recurrence	Metastasis		
1	18 months	F	2	Vagina	Embryonal	Yes	No	Yes	Irradiation	17 months
2	3	M	1	Hip	Embryonal	No	No	No	—	Not known
3	64	F	1	Thigh	Pleomorphic	Yes	Yes	No	Local excision	Not known
4	57	F	2	Back	Pleomorphic	Yes	Yes	Yes	Wide excision and chemotherapy	8 years
5	58	F	4	Gluteal region	Embryonal	No	Yes	No	Local excision	19 months
6	20 months	M	½	Bladder neck	Embryonal	Yes	Yes	Yes	Irradiation, surgery later	12 months
7	57	M	6	Thigh	Pleomorphic	Yes	Yes	Yes	Local excision	18 months
8	19	M	½	Maxillary sinus	Embryonal	Yes	No	Yes	Irradiation	17 months
9	11	M	½	Orbit	Embryonal	Yes	No	No	Irradiation	Not known
10	48	F	20	Right upper quadrant	Embryonal	No	No	Yes	Irradiation and chemotherapy	9 months
11	69	F	1	Urethra	Embryonal	No	No	Yes	Wide excision, irradiation and chemotherapy	5 years
12	58	M	2	Thigh	Pleomorphic	Yes	Yes	No	Local, wide excision later	19 months
13	8 months	F	¼	Iliac crest	Embryonal	Yes	No	Yes	Irradiation and chemotherapy	5 months
14	2	M	5	Temple	Embryonal-alveolar	No	Yes	Yes	Local excision, irradiation and chemotherapy	20 months

CLINICOPATHOLOGIC STUDY OF RHABDOMYOSARCOMA

15	68	M	2	Prostate	Alveolar	Yes	No	Yes	Irradiation and chemotherapy	8 months
16	8	M	1	Mandibular area	Alveolar	No	Yes	Yes	Local excision, irradiation and chemotherapy	14 months
17	8	M	1	Maxilla	Embryonal	No	Yes	No	Local excision, irradiation and chemotherapy	2 months
18	81	F	1	Thigh	Pleomorphic	No	No	No	Biopsy	Postoperative death
19	43	M	6	Prostate	Embryonal	Yes	No	Yes	Irradiation and chemotherapy	Living, 5 months
20	4	M	2	Nose	Embryonal	No	Yes	Yes	Wide excision and irradiation	4 years
21	43	F	Not known	Lymph node	Pleomorphic	Yes	No	No	Biopsy	Not known
22	42	F	3	Back	Embryonal	No	No	Yes	Irradiation	Not known
23	3	F	4	Orbit	Embryonal	Yes	Yes	No	Wide excision, irradiation and chemotherapy	Living, 18 months
24	12	F	2	Neck	Alveolar	No	Yes	Yes	Wide excision and irradiation	6 years
25	12	M	Not known	Paranasal region	Alveolar	No	No	No	Biopsy	Not known
26	14	F	4	Periadrenal region	Embryonal-alveolar	No	No	Yes	Irradiation and chemotherapy	11 months

ular region. These patients survived between eight months and six years. Wide surgical excision and radiation resulted in the six-year survival of a 12-year-old girl (case 24, *Table 1*) with a lesion in the neck. Cross striations were found in only one tumor.

Pleomorphic rhabdomyosarcoma. Six patients, four women and two men, had pleomorphic rhabdomyosarcoma. Their ages at the time of diagnosis ranged from 43 to 81 years.

Four of the tumors affected a lower extremity, and one tumor each the back and the abdominal cavity. The onset of the disease ranged from one month to six months before diagnosis. The patients survived from 18 months to 8 years. The best method of treatment was also a combination of wide surgical excision and chemotherapy. Cross striations were demonstrated in five of the six tumors.

Embryonal-alveolar rhabdomyosarcoma. Two tumors met the criteria for the diagnosis of embryonal-alveolar rhabdomyosarcoma. One patient, a two-year-old boy (case 14, *Table 1*) with a lesion in the temple, of five months' duration, was treated with local excision, and radiation with chemotherapy. He died 20 months later, after having had three recurrences and, terminally, widespread dissemination of the tumor.

The other patient was a 14-year-old girl (case 26, *Table 1*) with a perirenal lesion of four months' duration. She was treated with radiation and chemotherapy. Surgical excision was impossible because of widespread metastasis in the abdomen found at the time of laparotomy performed for diagnosis. She died 11 months postoperatively.

No cross striations were found in either of the two tumors.

EXPERIMENTAL AND CLINICAL TISSUE CULTURES OF RHABDOMYOSARCOMA

Specimens for tissue cultures were obtained from experimentally induced rhabdomyosarcoma in rats, and from surgical material removed from human beings.

Rat tissues. Investigations on metal carcinogenesis have revealed that, in rats, single intramuscular injections of sulfides and oxides of nickel and cobalt will produce a high incidence of fast-growing tumors at the sites of injection. The majority of such tumors exhibited the histologic features of rhabdomyosarcoma. The neoplastic cells were maintained in continuous cultures and subcultures, on Connaught's H596 medium supplemented with 20 percent inactivated calf serum, 0.08 percent sodium bicarbonate, and 100 international units per milliliter of potassium penicillin G.

Primary cultures were supplied with fresh medium 24 hours after being seeded, and again whenever the pH of the medium decreased to less than

7.1. Subcultures were made by the trypsin-digestion method. Primary cultures and early subcultures of rhabdomyosarcomas produced medium-sized cells that were round to oval, and each contained one elongate hyperchromic nucleus. At this stage, rhabdomyoblasts might or might not be seen. In later subcultures, the majority of cells became spindling, and rhabdomyoblasts, mainly multinucleate and straplike, appeared with definite cross striations, thus confirming the diagnosis of rhabdomyosarcoma. Chromosomal studies on those cells showed counts ranging from 42 to 206. The majority of cells were diploid, but heteroploid and polyploid cells were also present.

Human tissues. Tissue culture was carried out on a nasal embryonal rhabdomyosarcoma excised from a four-year-old boy (case 20, *Table 1*). A segment of nasal neoplasm approximately 1.0 by 0.5 by 0.5 cm, was obtained under sterile conditions, and was cultured in roller tubes by means of standard tissue culture technics. The medium was composed of 60 ml of Hank's balanced salt solution, 30 ml of human serum, and 10 ml of chick embryo extract (1:50), 2.5 ml of penicillin-streptomycin solution [5,000 units each per milliliter, and 2 ml of glutamine (200 mm³)].

Within three days there was growth around most of the explants. The medium was changed every other day, and on the twenty-seventh day the growth was moderately heavy, and second-generation transplants were made. The cultures were harvested by firm scraping of the tube with a rubber policeman; the cells were then trypsinized in a solution of trypsin (1 to 5000) for five minutes. The cells were then washed in Hank's solution, and resuspended in medium that was then inoculated into roller tubes. Growth of the second-generation transplants was generally of excellent quality; transplanting of subsequent generations was continued, so that, by the seventy-fifth day of the culture, five generations of the cultured neoplastic cells had been obtained.

At the time of preparation of the second generation of tubes, photographs of the explants magnified 125 and 400 times were made (*Fig. 7 and 8*, respectively). In these photographs it is possible to identify some faint cross striations in the cytoplasm of the cells at the periphery of the explant. Preparations stained with toluidine blue in horse serum demonstrated striations in the cytoplasm of the fusiform cellular elements (*Fig. 9*).

COMMENT

The 26 patients with rhabdomyosarcoma were equally divided between the sexes, with a predominance of males in the first two decades of life and of females in the older age groups (*Table 2*). Nine patients were in the first decade, and 14 were in the first two decades of life. The 26 tumors

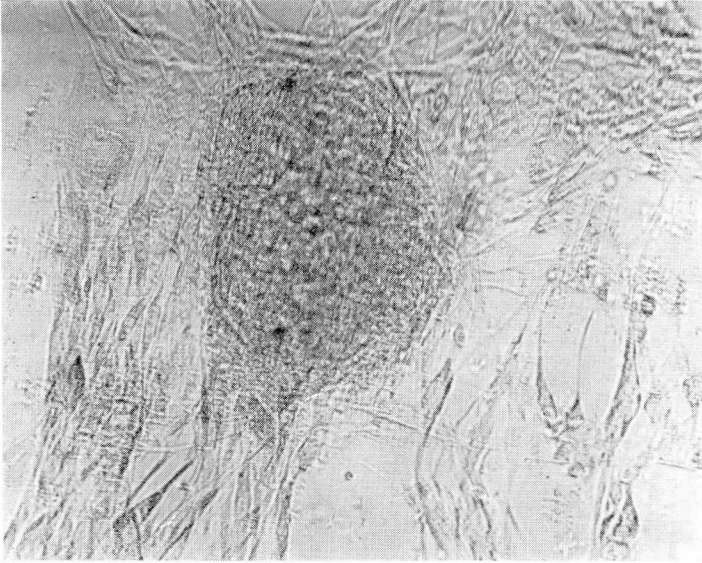


Fig. 7. Case 21 (*Table 1*). Tissue culture obtained from a nasal embryonal rhabdomyosarcoma, a second generation of the culture. Not stained; magnification $\times 125$.

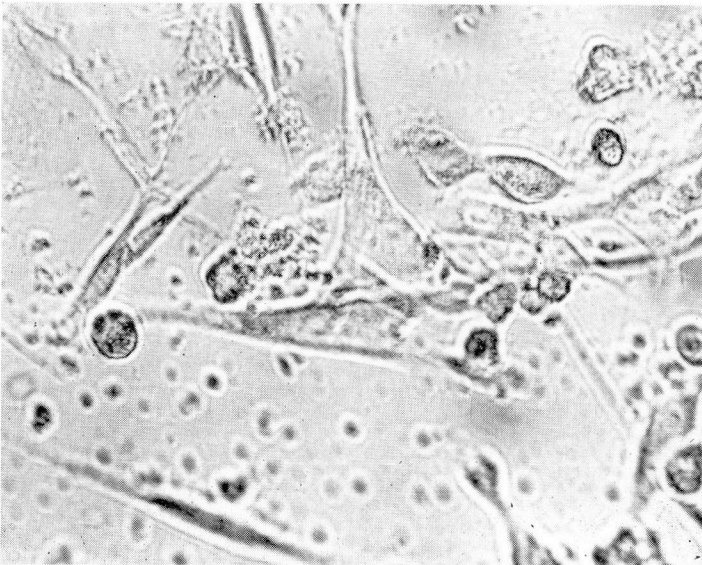

Fig. 8. Case 21 (*Table 1*). Tissue culture shows faint cross striations in two cells at the left side of the photomicrograph. Not stained; magnification $\times 400$.

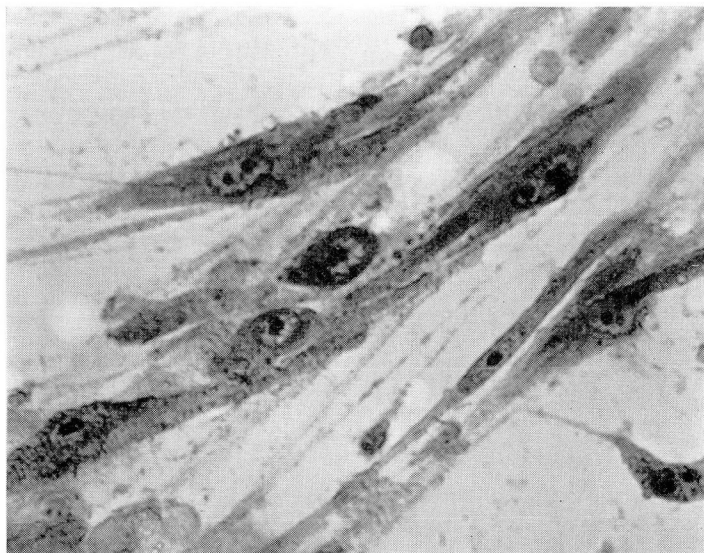

Fig. 9. Case 21 (Table 1). Preparations from tissue culture stained with toluidine blue in horse serum demonstrate the presence of striations in the fusiform cellular elements. Magnification $\times 900$.

Table 2.—Age at diagnosis and sex distribution of 26 patients with rhabdomyosarcoma; correlated with survival times after diagnosis

Patients				Rhabdomyosarcoma, type				Survival, months (average)
Age range, years	Number	Female	Male	Embryonal	Alveolar	Pleomorphic	Embryonal-alveolar	
0-10	9	3	6	7	1	0	1	17
11-20	5	2	3	2	2	0	1	33
21-40	0	0	0	0	0	0	0	—
41-50	4	3	1	3	0	1	0	9
51-60	4	2	2	1	0	3	0	38
61-70	3	2	1	1	1	1	0	34
71-80	0	0	0	0	0	0	0	—
81-90	1	1	0	0	0	1	0	Not known
Total	26	13	13	14	4	6	2	

were classified in our groups according to their histologic appearance, a distinction that is of great clinical and practical importance.

The average age of onset was 30 years, 23 years for the males (the median was 11 years), and 38 years for the females (the median was 43 years). The

average length of survival after diagnosis was 26 months: 18 months for males and 35 months for females.

The average survival time after diagnosis correlated well with the average age of patients at the onset of disease. The pleomorphic neoplasms had the most favorable prognosis, the average survival time of the patients being 44 months. The average age of the patients at the onset of pleomorphic neoplasms was 60 years, the greatest number of years among the four groups. The alveolar rhabdomyosarcoma had the second best prognosis, the patients surviving an average of 31 months. The average age of the patients at onset was 25 years. The most common tumor was the embryonal variety. The average length of survival of patients was 21 months, while the average age of onset was 22 years. There were only two embryonal-alveolar neoplasms. One patient was a two-year-old boy who lived 20 months after diagnosis, the other was a 14-year-old girl who died 11 months after the diagnosis was established.

The survival data for the 26 patients indicate that the best prognosis is that for the pleomorphic tumor, followed by the alveolar, the embryonal, and the alveolar-embryonal tumors. This order also correlates well with the average ages of patients at the onset of the various types of tumor. The average length of survival of those patients in the older age group was much longer than that for those in their first decade.

The average lengths of survival and average ages of patients at onset of disease were almost similar for patients whose tumors had cross striations (33 years, and 24 months, respectively), and for patients whose tumors were without cross striae (27 years, and 28 months, respectively).

Methods of treatment were planned according to location, local spread, and metastasis of rhabdomyosarcoma. The least successful method of treatment was that combining radiation and chemotherapy, which gave an average survival of eight months. Local excision with radiation alone or combined with chemotherapy gave an average survival of 12 months. Radiation alone gave a 17-month survival. Local excision, which was the only method of treatment in four patients, resulted in a maximum survival of 19 months for the three patients whose progress was followed. The most successful method of treatment, when early diagnosis was achieved, was wide local excision of the neoplasm and postoperative chemotherapy or radiation, or both drugs and radiation. Five patients were treated by such a regimen. Four patients lived four, five, six, or eight years, while one is still living 18 months postoperatively, with no evidence of recurrence or metastasis of the tumor.

Patients in whom the neoplasms were located where wide local excision was technically possible, such as the back, and the soft tissues of the head and neck, had a high average of length of survival; whereas, patients in

whom the neoplasms were in deep hidden areas, such as the prostate, and maxillary and mandibular regions, where extensive surgical procedures could be mutilating, especially when the tumor was of a rather long duration, had a considerably lower average of length of survival (*Table 3*).

The diagnosis of rhabdomyosarcoma is not justified in regard to tumors in which only undifferentiated mesenchymal cells are present, and rhabdomyoblasts are absent, for such lesions are equally representative of highly undifferentiated fibrosarcoma or liposarcoma. However, the presence of rhabdomyoblasts should not alone be considered justification for the diagnosis of rhabdomyosarcoma, because rhabdomyoblasts associated with other types of mesenchymal tissues are diagnostic of a mixed mesodermal tumor. We agree with Ober and Edgcomb,²⁷ and Albores-Saavedra, Butler, and Martin⁷ that sarcoma botryoides of the female genital tract is a mixed mesodermal tumor and a neoplasm should only be called a rhabdomyosarcoma when no other mesodermal tissues are present.

SUMMARY

Twenty-six cases of rhabdomyosarcoma were studied and a clinicopathologic assessment is reported. On the basis of histopathologic characteristics, the tumors were grouped into four categories: embryonal, alveolar, pleomorphic, and embryonal-alveolar. The embryonal was the most common (14) followed by the pleomorphic (6), alveolar (4), and the embryonal-alveolar (2). The tumors occurred in equal numbers in both

Table 3.—Anatomic sites of rhabdomyosarcoma correlated with the average age and survival time of 26 patients

Site	Patients		Rhabdomyosarcoma, type				Survival after diagnosis, months
	Number	Age range, years	Embryonal	Alveolar	Pleomorphic	Embryonal-alveolar	
Lower extremities	6	3-81	2	0	4	0	19
Abdomen	4	2½-48	2	0	1	1	7
Head and neck soft tissues	3	4-12	1	2	0	0	60
Maxilla, mandible	3	8-19	2	1	0	0	11
Genitourinary tract	3	1½-69	3	0	0	0	33
Back	2	42-57	1	0	1	0	96
Orbit	2	3-11	2	0	0	0	>18
Prostate	2	43-68	1	1	0	0	8
Temple	1	2	0	0	0	1	Not known

sexes, with more males affected in the younger age groups, and more females of the older patients.

The survival times of the patients correlate well and correspond with the average ages of patients and the histologic types of tumor. The pleomorphic type developed in patients at an average age of 60 years; their survival time averaged 44 months. The alveolar type of tumor developed in patients at an average age of 25 years; they survived an average of 31 months. The embryonal type of tumor developed in patients at an average age of 22 years; they survived an average of 21 months. The embryonal-alveolar type of tumor developed in two patients only; they survived 20 months and 11 months. Females had a much better prognosis than males, with an average survival time after diagnosis of 35 months, as opposed to 18 months in males.

Five types of mesenchymal cells were present in rhabdomyosarcoma: spindle, small round, large round, oval, and syncytial. Five types of rhabdomyoblasts also were present: round cells, straplike cells, racquet-shaped cells, giant cells, and spider cells.

Early diagnosis of rhabdomyosarcoma, with rapid, wide surgical excision, and chemotherapy alone or combined with radiation, offer hope for improved results in the future.

REFERENCES

1. Stout, A. P.: Rhabdomyosarcoma of the skeletal muscles. *Ann. Surg.* **123**: 447-472, 1946.
2. Stobbe, G. D., and Dargeon, H. W.: Embryonal rhabdomyosarcoma of the head and neck in children and adolescents. *Cancer* **3**: 826-836, 1950.
3. Riopelle, J. L., and Thériault, J. P.: Sur une forme méconnue de sarcome des parties molles: le rhabdomyosarcome alvéolaire. *Ann. d'Anat. Path.* **1** (nouvelle série): 88-111, 1956.
4. Horn, R. C., Jr., and Enterline, H. T.: Rhabdomyosarcoma: a clinicopathological study and classification of 39 cases. *Cancer* **11**: 181-199, 1958.
5. Stout, A. P.: Tumors of Soft Tissue, p. 89-98, in *Atlas of Tumor Pathology, Sec. II, Fascicle 5*. Washington, D.C.: Armed Forces Institute of Pathology, 1953.
6. Linscheid, R. L.; Soule, E. H., and Henderson, E. D.: Pleomorphic rhabdomyosarcomata of the extremities and limb girdles; a clinicopathological study. *J. Bone Joint Surg.* **47-A**: 715-726, 1965.
7. Albores-Saavedra, J.; Butler, J. J., and Martin, R. G.: Rhabdomyosarcoma: Clinicopathologic Considerations and Report of 85 Cases, p. 349-366, in *Tumors of Bone and Soft Tissue; Eighth Annual Clinical Conference on Cancer, 1963*, at The University of Texas M. D. Anderson Hospital and Tumor Institute, Houston, Texas. Chicago: Year Book Medical Publishers, Inc., 1965, 448 p.
8. Albores-Saavedra, J.; Martin, R. G., and Smith, J. L., Jr.: Rhabdomyosarcoma: a study of 35 cases. *Ann. Surg.* **157**: 186-197, 1963.
9. Albores-Saavedra, J.: Rhabdomyosarcoma. *Progr. Clin. Cancer* **1**: 683-691, 1965.
10. Conquest, H. F., and others: Primary pulmonary rhabdomyosarcoma; report of three cases and literature review. *Ann. Surg.* **161**: 688-692, 1965.

CLINICOPATHOLOGIC STUDY OF RHABDOMYOSARCOMA

11. Hare, H. F., and Cerny, M. J., Jr.: Soft tissue sarcoma; a review of 200 cases. *Cancer* **16**: 1332-1337, 1963.
12. Masson, J. K., and Soule, E. H.: Embryonal rhabdomyosarcoma of the head and neck; report on eighty-eight cases. *Amer. J. Surg.* **110**: 585-591, 1965.
13. Jones, I. S.; Reese, A. B., and Kraut, J.: Orbital rhabdomyosarcoma; an analysis of 62 cases. *Amer. J. Ophthalm.* **61**: 721-736, 1966.
14. Porterfield, J. F., and Zimmerman, L. E.: Rhabdomyosarcoma of the orbit; a clinicopathologic study of 55 cases. *Virchow Arch. Path. Anat.* **335**: 329-344, 1962.
15. Zimmerman, L. E.: Chap. 16, New Concepts Regarding Certain Orbital and Lacrimal Gland Tumors, p. 395-428, in Boniuk, M. (editor): *Ocular and Adnexal Tumors, New and Controversial Aspects*; Symposium sponsored by Department of Ophthalmology, Baylor University College of Medicine. St. Louis: C. V. Mosby Co., 1964, 511 p.
16. Kauffman, S. L., and Stout, A. P.: Tumors of the major salivary glands in children. *Cancer* **16**: 1317-1331, 1963.
17. Martin, G. E., and Alexander, W. A.: A case of rhabdomyosarcoma of the soft palate. *J. Laryng.* **39**: 312-321, 1924.
18. Maconie, A. C.: Sarcoma of the middle ear and mastoid. *J. Laryng.* **59**: 32-35, 1944.
19. Jones, C. B., Jr., and Oberman, H. A.: Rhabdomyosarcoma of the bladder: occurrence in childhood and in advanced age. *J. Urol.* **91**: 533-537, 1964.
20. Legier, J. F.: Botryoid sarcoma and rhabdomyosarcoma of the bladder: review of the literature and report of 3 cases. *J. Urol.* **86**: 583-590, 1961.
21. Mostofi, F. K., and Morse, W. H.: Polypoid rhabdomyosarcoma (sarcoma botryoides) of bladder in children. *J. Urol.* **67**: 681-687, 1952.
22. Holtz, F., and Abell, M. R.: Testicular neoplasms in infants and children. II. Tumors of non-germ cell origin. *Cancer* **16**: 982-992, 1963.
23. Payan, H.: Rhabdomyosarcoma of the ovary; report of a case. *Obstet. Gynec.* **26**: 393-395, 1965.
24. Burgert, E. O., Jr., and Mills, S. D.: Chemotherapy of malignant lesions unique in children. *Mayo Clin. Proc.* **41**: 361-367, 1966.
25. Martin, R. G.; Butler, J. J., and Albores-Saavedra, J.: Soft Tissue Tumors: Surgical Treatment and Results, p. 333-348, in *Tumors of Bone and Soft Tissue; Eighth Annual Clinical Conference on Cancer, 1963, at The University of Texas M. D. Anderson Hospital and Tumor Institute, Houston, Texas.* Chicago: Year Book Medical Publishers, Inc., 1965, 448 p.
26. Patton, R. B., and Horn, R. C., Jr.: Rhabdomyosarcoma: clinical and pathological features and comparison with human fetal and embryonal skeletal muscle. *Surgery* **52**: 572-584, 1962.
27. Ober, W. B., and Edgcomb, J. H.: Sarcoma botryoides in the female urogenital tract. *Cancer* **7**: 75-91, 1954.