

Ceroid deposition in the muscularis of the small intestine, associated with regional enteritis

REPORT OF A CASE

JOHN P. PAPP, M.D.*

RICHARD G. FARMER, M.D.

Department of Gastroenterology

WILLIAM A. HAWK, M.D.

Division of Pathology

CEROID pigment deposited in the smooth muscle of the small intestine in humans is an unusual finding. Characteristically the pigment is only deposited after prolonged vitamin E deficiency.¹ Of 141 published cases,¹⁻¹² in 127 cases there was microscopic evidence and in 14 cases gross evidence,¹⁻⁸ but only rarely has clinical correlation been possible.

A variety of diseases, such as cystic fibrosis, chronic pancreatitis,^{4, 12} non-tropical sprue,^{3, 7} Whipple's disease,^{6, 8} celiac disease,¹⁰ biliary atresia,¹⁰ Laennec's cirrhosis,^{10, 12} portal cirrhosis,¹⁰ biliary cirrhosis associated with chronic pancreatitis,¹² profound nutritional imbalance,^{1-3, 12} idiopathic hypoproteinemia,⁵ idiopathic steatorrhea,⁷ jejunal diverticulosis,⁷ and terminal ileitis associated with jejunal diverticulosis⁹ have been reported in which ceroid pigment has been found in the muscularis propria of the small intestine.

Although Paulley⁹ reported a case of terminal ileitis and jejunal diverticulosis in which golden-brown pigment granules and the smooth-muscle cells of the small bowel were found on microscopic examination, he did not associate the granules with ceroid. We wish to report what we believe to be the second case of ceroidosis associated with regional enteritis, and the fifteenth case in which the ceroid pigment was evident on gross examination of the small bowel.

Report of a case

A 51-year-old woman was first examined at the Cleveland Clinic in 1957 because of 8 to 10 loose (not bloody) bowel movements per day for more than 15 years. Her medical history revealed that between 1942 and 1944 she had undergone three abdominal operations for small-bowel obstruction and abscess formation. Several feet of small bowel were said to have been resected. A fistula in ano was also surgically treated during that period. She had lost 42 pounds and reached a low weight of 84 pounds. Despite medical treatment (paregoric, kaopectate, and phenobarbital), she continued to have several loose bowel movements daily, associated with intermittent cramping abdominal pain.

Physical examination of the patient revealed a thin, chronically ill, Caucasian woman who weighed 88 pounds. The abdomen showed no clinical sign of intestinal obstruction,

* Formerly Intern, Cleveland Clinic Hospital; current address: 1245 Ravenwood Avenue, Ann Arbor, Michigan 48103.

but several small surgical scars were present in the right lower quadrant. The liver was palpable 5 cm below the right costal margin. Proctoscopic examination disclosed grayish-pink edematous friable mucosa and an anal stricture. No mucosal ulceration could be observed, but a large amount of pus was seen coming from above the proctoscopic field. Roentgen studies of the small intestine after barium taken orally demonstrated segmental dilatation of several loops of ileum and prominent plicae circulares. Roentgenograms of the colon after barium enema were interpreted as showing normal tissues, but the terminal ileum could not be visualized.

Results of laboratory tests were: blood hemoglobin 9.2 g per 100 ml, total serum protein 5.7 g per 100 ml, serum albumin 3.4 g per 100 ml, serum globulin 2.3 g per 100 ml, serum calcium 9.1 mg per 100 ml, and 4+ fecal fat. These findings were considered to be compatible with the diagnosis of regional enteritis, and surgical treatment was not recommended. A course of salicylazosulfapyridine therapy was initiated and the patient was returned to the care of her local physician.

In January 1963, the patient was examined at the Cleveland Clinic because of continuing (not bloody) loose bowel movements. Between 1957 and 1963 she had undergone three more operations for fistulas in ano. Results of the physical examination were similar to those in 1957. Roentgenographic studies after barium taken orally revealed narrowing of a segment of ileum near an ileocolic anastomosis, consistent with regional enteritis. The blood hemoglobin was 11.1 mg per 100 ml; serum carotene was 10 μ g per 100 ml; and serum calcium was 9.5 mg per 100 ml. In an attempt to control the ileitis, a course of uracil mustard, totally 3 mg, was given as well as prednisone and diphenoxylate hydrochloride and atropine sulfate. After 22 days of treatment, having achieved a satisfactory symptomatic response, she was discharged from the hospital. The following month, leukopenia developed and she was given three units of whole blood at another hospital. No further dose of uracil mustard was administered.

After leukopenia regressed, the patient again did fairly well symptomatically, although she did not gain weight and continued to have diarrhea. She was maintained on low doses of prednisone and was ambulatory.

On January 4, 1965, she was readmitted to the Cleveland Clinic Hospital for evaluation and treatment. She had been having from six to eight loose yellowish bowel movements per day, had failed to gain weight, and had continued to have abdominal pain. Her general appearance was unchanged from the time of the previous examination and she now weighed 80 pounds. The abdomen was hyperresonant to percussion and not tender. The liver was palpable 6 cm below the right costal margin. The blood hemoglobin was 11.4 g per 100 ml; a leukocyte count was 8200 per cubic millimeter with a normal differential blood cell count. Serum calcium was 6.5 mg per 100 ml, total protein 4.3 g per 100 ml, and serum carotene less than 10 μ g per 100 ml. The serum alkaline phosphatase was 20.7 King-Armstrong units (normal, from 4 to 14 units). Examination of feces showed no evidence of enteric pathogens or parasites. A course of adrenocorticotrophic hormone and paromomycin sulfate was initiated and resulted in a decrease in bowel movements to two or three per day. On January 13, 1965, she was discharged from the hospital with the advice to have intramuscular injections of adrenocorticotrophic hormone gel.

On February 22, 1965, the patient was again admitted to the Cleveland Clinic Hospital because of severe, intermittent, cramping, abdominal pain of four days' duration, and occasional vomiting. There had been no change in bowel habits. She weighed 82 pounds, was afebrile and her general appearance was little changed. The abdomen was not distended but was hyperresonant to percussion. Hypoactive bowel sounds were present but no tenderness to palpation. Because of the probability of intestinal obstruction, abdominal operation was advised and was performed on February 26, 1965. At operation the entire small bowel was orange brown, and tinea of the colon were of similar coloration (*Fig. 1*). The previous ileocolic anastomosis was found to be severely stenotic. There was thickening of the small intestinal component of the anastomosis, and serositis was present. Enlarged lymph nodes were in the mesentery adjoining the anastomosis. Surgical resection and reconstruction of a new ileocolic anastomosis was performed. The patient made an uneventful recovery and was discharged from the hospital on March 8, 1965. A serum tocopherol value was determined postoperatively and it was 136 μ g per 100 ml (normal value from 200 to 900 μ g).

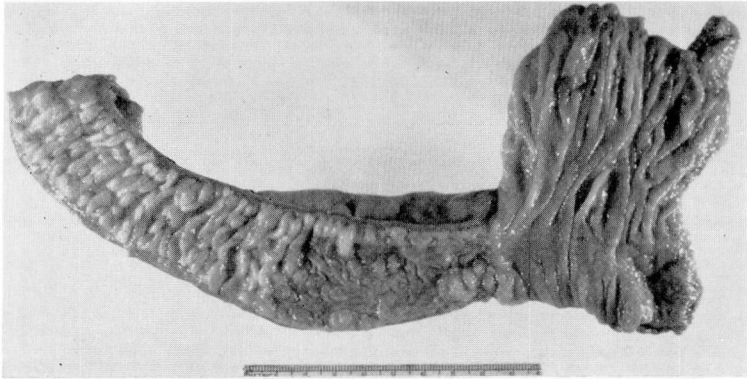


Fig. 1. Photograph of the resected ileocolic anastomosis showing the stenotic narrowing and the ulceration and cobblestoning characteristic of regional enteritis.

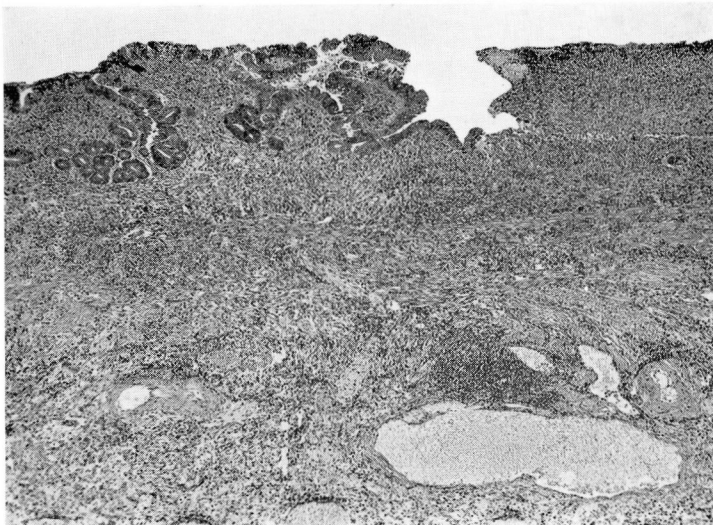


Fig. 2. Photomicrograph of a section of the ileum just proximal to the anastomosis, illustrating the extensive ulceration and dense nonspecific inflammatory infiltration affecting the mucosa and submucosa. An intense chronic serositis, not shown, was also present. Hematoxylin-eosin-methylene blue stain; magnification $\times 40$.

The resected ileocolic anastomosis demonstrated severe stenotic narrowing of the anastomosis with thickening of the ileal wall. Mucosal ulceration was present immediately proximal to the ileocolic stoma. Histologic examination of the stained sections of ileum revealed undermining mucosal ulceration with rather an intense inflammatory infiltrate that affected the entire thickness of the ileum. Small fissures extended from the bases of the mucosal ulcers to the subserosa. The most striking histocytologic feature was the presence of golden-brown pigment granules within the cytoplasm of the smooth muscle cells of the muscularis mucosae. The granules had a principally paranuclear distribution; they were intensely acid-fast when stained with a modified Ziehl-Nielsen stain and were autofluorescent (*Fig. 2 and 3*).

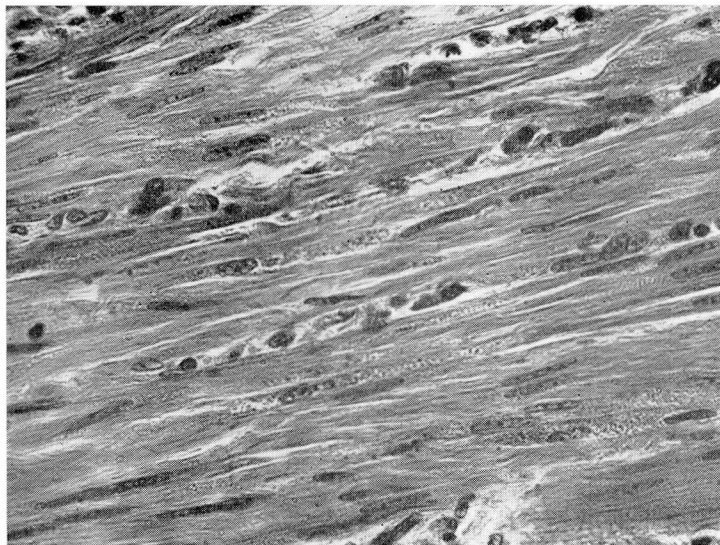

Fig. 3. Photomicrograph of a section of the muscularis propria of the ileum, depicting the presence of granules in the smooth muscle cells. Note the paranuclear location of the ceroid granules. Hematoxylin-eosin-methylene blue stain; magnification $\times 380$.

Discussion

In 1917 Whipple and Hooper¹³ noted that dogs with experimentally produced biliary fistulas had a hemofuscin-like pigmentation of the muscularis propria of the small bowel. This pigment was later tentatively identified as ceroid by Pappenheimer and Victor,² who reported the finding of ceroid pigment in the muscularis propria of the small intestine in humans.

The term ceroid is derived from a Greek word which means "wax appearance." It was used in 1942 by Lillie and co-workers¹⁴ to describe oval, yellow globules found in the livers and the Kupfer cells of rats that had been fed a low-protein, low-fat, and vitamin E deficient diet. In sections stained with hematoxylin and eosin these granules were a golden brown. At times, the granules have been so abundant that the unstained small intestine appeared grossly brown. It was this striking finding noted during abdominal surgery which caused Ansell and Lane³ to use the term "brown bowel syndrome." The ceroid globules are found in the cytoplasm both of circular and of longitudinal smooth-muscle cells of the small bowel, particularly in the paranuclear areas. Under ultraviolet light, ceroid globules are autofluorescent.

Ceroid belongs to a class of chromolipids called lipofuscins. On the basis of chemical and histochemical studies, ceroid pigment is thought to represent an intermediate stage in the autooxidation of fatty acid residues.¹⁰ In the presence of vitamin E, which acts as a cellular antioxidant, ceroid is usually not found.⁴ Binder and associates¹ point out that tocopherol is found in mitochondria of cells and that its absence might produce abnormal cellular respira-

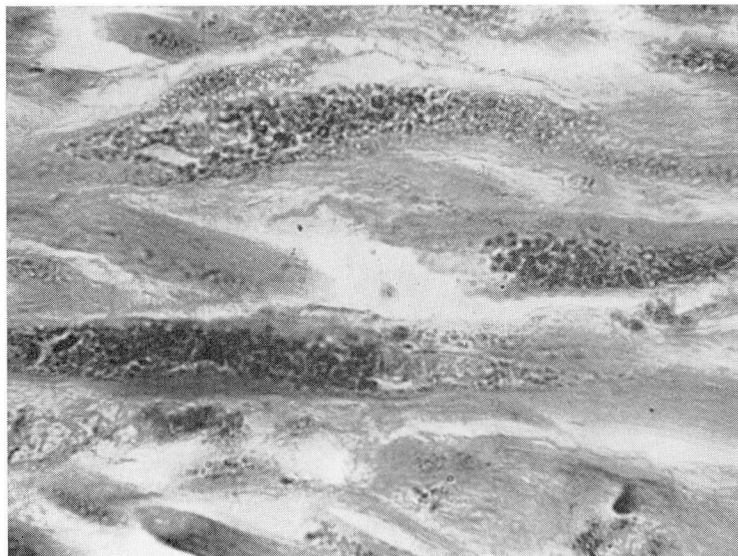

Fig. 4. Photomicrograph of a section of the muscularis propria shown in *Figure 3*. Hematoxylin-eosin-methylene blue stain; magnification $\times 900$.

tion and a defect in lipid formation leading to an accumulation of various lipid products. Some support to this view is obtained from the electron microscopic studies of affected smooth muscle (from a patient other than the one's whose case we report). The intracellular cytoplasmic granules, from 1000 Å to from 1 to 2 μ in cross diameter, distorted small Golgi complexes, mitochondria, and bundles of myofilaments. The granules were osmiophilic, varied in size, and some possessed a single-unit limiting membrane (*Fig. 4*).*

The patient whose case we report had regional enteritis known for 23 years, with proved malabsorption of the small intestine for two years. The serum tocopherol value was low, and grossly visible small-bowel ceroidosis was present at operation. Although it has not been proved that vitamin E deficiency is the cause of ceroidosis, there is strong support in published studies, both experimental and clinical, so that it is tempting to speculate that malabsorption of vitamin E played a major role in this case.

Summary

Ceroidosis of the small bowel is an unusual entity. It may be evident microscopically and grossly and has been associated with malabsorptive states. Vitamin E deficiency has been postulated as the cause of ceroidosis. Our report concerns a case (which we believe is the second case to be recorded) of ceroidosis associated with regional enteritis in a patient with long-standing regional enteritis and clinical evidence of diffuse malabsorption. We have speculated

**Electron microscopic studies were performed by our colleague, Abel L. Robertson, Jr., M.D., Division of Research.*

that malabsorption of vitamin E was the primary etiologic factor in the production of ceroidosis.

References

1. Binder, H. J., and others: Tocopherol deficiency in man. *New Eng. J. Med.* **273**: 1289-1297, 1965.
2. Pappenheimer, A. M., and Victor, J.: "Ceroid" pigment in human tissues. *Amer. J. Path.* **22**: 395-413, 1946.
3. Ansanelli, V., Jr., and Lane, N.: Lipochrome ("ceroid") pigmentation of the small intestine. *Ann. Surg.* **146**: 117-123, 1957.
4. Toffler, A. H.; Hukill, P. B., and Spiro, H. M.: Brown bowel syndrome. *Ann. Intern. Med.* **58**: 872-877, 1963.
5. Schwartz, M., and Jarnum, S.: Gastrointestinal protein loss in idiopathic (hypercatabolic) hypoproteinaemia. *Lancet* **1**: 327-330, 1959.
6. Richards, W. C. D.: Letters to the editor. Pigmentation of gastrointestinal muscle. *Lancet* **1**: 683, 1959.
7. Adlersberg, D., and Schein, J.: Clinical and pathologic studies in sprue. *J.A.M.A.* **134**: 1459-1467, 1947.
8. Gresham, G. A.; Cruickshank, J. G., and Valentine, J. C.: Pigmentation of intestinal muscle in steatorrhoea. *Nature* **181**: 538-539, 1958.
9. Paulley, J. W.: Observations on the aetiology of idiopathic steatorrhoea; jejunal and lymph-node biopsies. *Brit. Med. J.* **2**: 1318-1321, 1954.
10. Blanc, W. A.; Reid, J. D., and Andersen, D. H.: Avitaminosis E in cystic fibrosis of pancreas; a morphologic study of gastrointestinal and striated muscle. *Pediatrics* **22**: 494-505, 1958.
11. Kerner, I., and Goldbloom, R. B.: Investigations of tocopherol deficiency in infancy and childhood; studies of ceroid pigment deposition. *Amer. J. Dis. Child.* **99**: 597-603, 1960.
12. Braunstein, H.: Tocopherol deficiency in adults with chronic pancreatitis. *Gastroenterology* **40**: 224-231, 1961.
13. Whipple, G. H., and Hooper, C. W.: Bile pigment metabolism. VII. Bile pigment output influenced by hemoglobin injections, anemia and blood regeneration. *Amer. J. Physiol.* **43**: 258-274, 1917.
14. Lillie, R. D., and others: Histogenesis and repair of the hepatic cirrhosis in rats produced on low protein diets and preventable with choline. *Pub. Health Rep.* **57**: 502-508, 1942.