

# Ossiculum terminale—an anomaly of the odontoid process

## *Report of a case of atlantoaxial dislocation with cord compression*

CHARLES M. EVARTS, M.D.  
Department of Orthopaedic Surgery

DERRICK LONSDALE, M.B., B.S.  
Department of Pediatrics

IT has long been recognized that atlantoaxial dislocations may result from incompetence of the odontoid process. The most common anomaly of the odontoid process is the ossiculum terminale.<sup>1</sup> It is characterized by failure of fusion of the apical segment of the dens to its base, which is joined to the body of the second cervical vertebra. The size of the base may be quite small, or it may appear almost normal; the apical segment may also vary in size. The term ossiculum terminale has been erroneously used to describe many varieties of anomalies of the odontoid process, but it should be used only to describe a failure of fusion of the apical segment and the base with the body of the axis, a condition that is extremely rare.<sup>2</sup>

Bizarre clinical syndromes are caused by atlantoaxial dislocations secondary to incompetence of the odontoid process.<sup>3-5</sup> Upper cervical cord compression may result in neurologic changes that are often progressive. Associated symptoms are pain and stiffness in the neck, headache, transitory quadriplegia, and progressive hemiparesis. Our report is concerned with an anomaly of the odontoid process together with atlantoaxial dislocation and cervical cord compression.

### Report of a case

On April 17, 1967, a 10-year-old boy was examined at the Cleveland Clinic because of the chief symptom of a "catch" in the neck. In June 1965, his parents noted the onset of frequent episodes of his slumping to the ground in great pain after throwing a ball. He was examined by a chiropractor, and subsequently roentgenograms were interpreted as "something misplaced at an early age." Treatment consisted of manipulation of the neck by a chiropractor. In July 1965, the patient was jumped upon while in a swimming pool and he became quadriplegic. For approximately three hours he could not move his left arm or leg, and he had severe pain in the neck. After a roentgenographic examination, he underwent remanipulation by a chiropractor. In August 1965, the patient was admitted to a hospital and physical therapy was begun. After neurosurgical consultation the patient was placed in a cervical collar. His left side continued to be weak, and he was unable to button his shirt. His left foot dragged. In October 1966, he ran into another child, fell

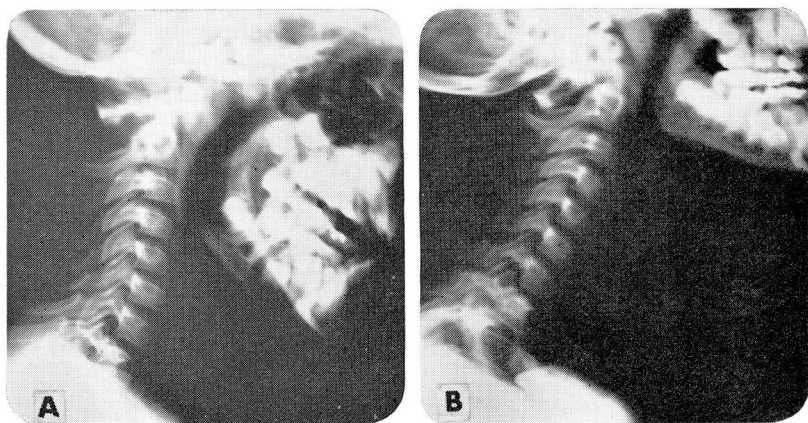


Fig. 1. Roentgenograms of lateral cervical spine. A, shows forward displacement of the first cervical vertebra in flexion. B, shows posterior displacement of the first cervical vertebra in extension.

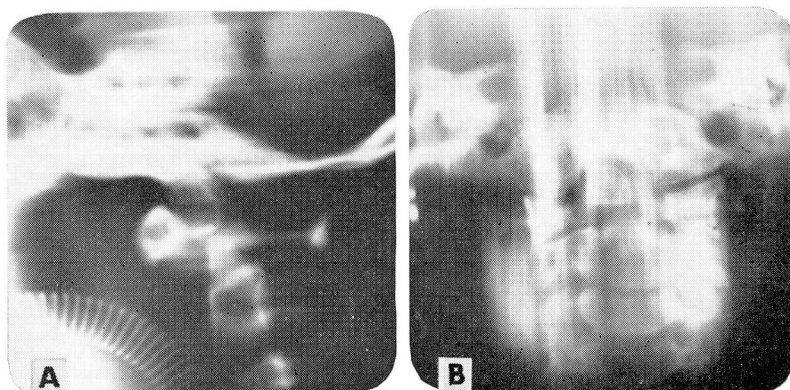


Fig. 2. A, Roentgenogram of lateral cervical spine, showing forward displacement of os terminale. B, Roentgenogram of anterior cervical spine, showing os terminale.

backwards, and was unable to walk or to stand. He was readmitted to the hospital but a diagnosis was not established. Later he experienced two episodes of "catching in the neck" accompanied by severe pain in the neck, headache, a choking sensation, and weakness of the left arm and leg.

Physical examination revealed hyperactive deep tendon reflexes of the left leg. Babinski's reflex and muscular spasticity were present, and the anterior leg musculature was weak, with a motor power rating of three. Unsustained clonus of the left ankle was present. The right pupil was larger than the left.

Roentgenograms revealed an os terminale with subluxation of the first cervical vertebra forward on the second cervical vertebra (Fig. 1 and 2). An electroencephalogram and a myelogram were normal. Cineradiography of the cervical spine revealed abnormal motion of the first cervical vertebra forward on the second cervical vertebra. The patient was admitted to the Cleveland Clinic Hospital on April 17, 1967.

On May 2, 1967, after application of skull tongs, a posterior cervical spinal fusion was performed from the first to the third cervical vertebrae with autogenous iliac bone grafts and wire fixation. The first cervical vertebra was noted to be grossly unstable, and the inter-

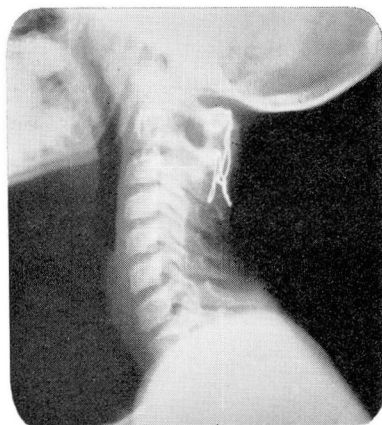

Fig. 3. Roentgenogram of lateral cervical spine showing solid spinal fusion extending from the first to the third cervical vertebrae with posterior bone graft and wire fixation.

spinous process space between the first and second cervical vertebrae was increased. The dura between the first and second cervical vertebrae was transparently thin.

Skull traction was maintained until June 7, 1967, and then a cervical brace was applied. The patient was discharged from the Cleveland Clinic Hospital on June 10, 1967.

The cervical brace was removed in February 1968, and cineradiography of the cervical spine revealed a solid fusion from the first cervical vertebra to third cervical vertebra (Fig. 3). By that time, the patient's activities included playing baseball, bowling, horseback riding, and swimming. Progressive resistance exercises were performed on the left quadriceps, extensor digitorum longus, extensor hallucis longus, peroneus longus, and brevis. In those muscle groups the motor power rating increased to four. When last examined in June 1969, a left Babinski's reflex and slight weakness of the left arm were present. There was minimal incoordination of the left hand and arm, and tightness of the left hip flexors and heel cord. The patient's gait was more of a bounce than a normal heel-toe rhythm. There was no clonus or inequality of pupils.

## Discussion

There was an unusually long delay in the establishment of diagnosis and appropriate treatment of this patient. Upon admission to the Cleveland Clinic Hospital, symptoms and signs of upper cervical cord compression were present, and the diagnosis of dislocation was confirmed on roentgenograms. The atlantodontoid interval was 5 mm, indicating a forward slip. An ossiculum terminale was easily identified from laminagrams of the upper cervical spine. Cineradiography of the cervical spine provided further substantiation of the diagnosis. The patient's complaints of pain in the neck and limitation of motion corroborate the experiences of other clinicians in making the diagnosis of atlantoaxial dislocation. Trauma to the head and neck by direct impact may cause symptoms that lead to investigation of the upper cervical spine, with subsequent discovery of congenital anomalies. It is not likely that this patient sustained an odontoid fracture, as his neurologic symptoms preceded his injury in a swimming pool.

Chiropractic manipulation may have aggravated the high cervical myelopathy with primary left-sided involvement. Appropriate treatment consisted of a posterior cervical spinal fusion from the first cervical vertebra through the third cervical vertebra, with autogenous iliac bone graft and fixation with wire. After fusion, the patient improved both subjectively and objectively. He resumed full activity and regained a motor power rating of four in the affected left leg. The left-sided spasticity decreased and the sizes of the pupils became equal.

The majority of patients with atlantoaxial dislocation secondary to congenital odontoid anomalies respond favorably to posterior cervical spinal fusion.<sup>6, 7</sup> The inherent danger to a patient with such an abnormality must be recognized and promptly treated, as just minimal trauma might result in permanent cord damage or death. Ely<sup>8</sup> in 1911 quoted Roswell Park: "The symptoms of injury to first, second, and third cervical vertebrae are death."

### Summary

A case is reported of an ossiculum terminale with atlantoaxial dislocation and cervical spinal cord compression in a 10-year-old boy. The condition was successfully treated by posterior spinal fusion from the first to the third cervical vertebrae with autogenous iliac bone grafts and wire fixation.

### References

1. Hadley, L. A.: Atlanto-occipital fusion, ossiculum terminale and occipital vertebra as related to basilar impression with neurological symptoms. *Amer. J. Roentgen.* **59**: 511-524, 1948.
2. Greenberg, A. D.: Atlanto-axial dislocations. *Brain* **91**: 655-684, 1968.
3. McRae, D. L.: The significance of abnormalities of the cervical spine. *Amer. J. Roentgen.* **84**: 3-25, 1960.
4. List, C. F.: Neurologic syndromes accompanying developmental anomalies of occipital bone, atlas and axis. *Arch. Neurol. Psychiat.* **45**: 577-616, 1941.
5. Wollin, D. G.: The os odontoideum; separate odontoid process. *J. Bone Joint Surg.* **45-A**: 1459-1471, 1963.
6. Lipscomb, P. R.: Cervico-occipital fusion for congenital and posttraumatic anomalies of the atlas and axis. *J. Bone Joint Surg.* **39-A**: 1289-1301, 1957.
7. Alexander, E., Jr., and others: Dislocation of the atlas on the axis: the value of early fusion of C1, C2, and C3. *J. Neurosurg.* **15**: 353-371, 1958.
8. Ely, L. W.: Subluxation of the atlas; report of two cases. *Ann. Surg.* **54**: 20-29, 1911.