

# The role of biopsy in fiberoptic esophagogastroscope

## *With report of five illustrative cases*

RICHARD E. NENSEL, M.D.\*  
Department of Pathology

B. H. SULLIVAN, JR., M.D.  
Department of Gastroenterology

DESIGN and technical advances have recently provided the endoscopist with sophisticated instruments that permit safe and relatively complete inspection of the entire esophagus and stomach. Fiberoptic systems for illumination and image transmission allow the manufacture of an extremely flexible instrument, which can be tolerated by the patient long enough for an unhurried examination to be conducted. The directable tip makes it possible for the endoscopist to guide the instrument along tortuous channels, or to turn it retrograde in the stomach for views of the fornix and cardia. Provision has been made for aspiration, inflation with air, washing the objective lens, and photography. A small-diameter biopsy forceps can be passed down the aspiration channel of the instrument.

These useful features have evolved over a number of years, beginning with the development of the lens type of gastroscope by Rudolph Schindler in the late 1930s and followed by the Benedict operating gastroscope in 1948, the Wood biopsy tube in 1950, the Hirschowitz fiberoptic gastroscope in 1958, the Japanese gastrocamera in 1958, and culminating in the Japanese Olympus EF esophagoscope in 1968, and the American Cystoscope Makers, Inc., Model 89 esophagogastroscope in 1969. An instrument is now available which can be used for the examination of the esophagus and the stomach with relative completeness, visually, photographically, and by biopsy.

The advantage of histologic confirmation of lesions seen endoscopically has always been obvious, but the overwhelming difficulties in obtaining a specimen from a precisely selected point discouraged most endoscopists from making the effort. The new instruments permit precise selection and accurate removal of the specimen under visual control. The purpose of this paper is to report our experiences with this technic during the year 1969.


---

\* Fellow, Department of Pathology.

### Material and methods

All esophagoscopic and gastroscopic examinations (631) made in the Department of Gastroenterology of the Cleveland Clinic during the year 1969, were included in the analysis. Patients underwent the examination when clinical history, physical, or radiographic findings suggested the presence of a lesion in the esophagus or the stomach. Inpatients and outpatients were examined; no anesthetic, either general or local, was employed, but sedation was obtained by the intravenous injection of meperidine hydrochloride (50 to 100 mg), and diazepam (2 to 5 mg).

Either the Olympus EF fiberoptic esophagoscope or the ACMI Mark 89 fiberoptic esophagogastroscope (*Fig. 1*) was employed, depending upon the location of the suspected lesion. The ACMI instrument was preferred for lesions in the lower half of the stomach, a region not always reached by the Olympus instrument. The Olympus EF esophagoscope is somewhat easier to manipulate and was often employed when the suspected lesion was in the esophagus or at the cardia. Classification of all cases was based on whether biopsy techniques were incorporated with the endoscopic procedure or not, and, if not, as to the presence or absence of grossly visualized pathologic lesions that could be biopsied. Highly vascular lesions such as varices, hemangiomas, or other sources of active esophageal or gastric hemorrhage were not biopsied. These were included in the group of cases



**Fig. 1.** The distal ends of the ACMI Mark 89 esophagogastroscope (left) and the Olympus EF esophagoscope (right) are shown with the tips deflected approximately 90° and with biopsy forceps extended and open.

with no visualized disease process that could be biopsied. When possible several specimens were removed.

The biopsy specimens were 3 or 4 mm in diameter. They were teased from the forceps onto bibulous paper and fixed for from 60 to 90 minutes in Zenker's acetic acid solution. This is necessary to preserve accurate cellular detail so important for diagnosis in these small fragments of tissue. Washing in water was conducted for an equal period, then the standard Technicon processing, paraffin embedding, sectioning at 4- $\mu$  thickness, and slide preparation followed. No attempt was made to orient the specimens anatomically.

## Results

During the year 1969 a total of 631 endoscopic examinations of the upper gastrointestinal tract were made utilizing modern fiberoptic instruments capable of obtaining specimens for tissue diagnosis. Biopsy specimens were obtained during 121 of the examinations, and included 33 cases in which a biopsy diagnosis of malignant neoplasm was made. No biopsy specimen was taken at 218 examinations, although, in retrospect, histologic confirmation of the diagnoses would have been desirable. Lesions in this group included ulcerations greater than 5 mm in diameter, elevated plaques, "leukoplakia," gastric and esophageal mucosal polyps, areas of "mucosal thickening and impaired motility," as well as diffuse erosive gastritis or esophagitis. A third group of cases included 292 examinations without biopsy, in which the findings were normal or the lesion (varices, hemangiomas, active hemorrhage) was considered dangerous to biopsy.

Review of the biopsy material confirmed the accuracy of the original diagnosis, although in several cases the diagnosis proved to be misleading. In the 33 cases diagnosed as malignant, several varieties of neoplasia were found: adenocarcinoma (16 patients), signet-ring cell carcinoma (5 patients), squamous cell carcinoma (4 patients), reticulum cell sarcoma (4 patients), lymphocytic lymphoma (3 patients), leiomyosarcoma (1 patient). Within this group in one case the diagnosis made was malignant disease but subsequently was proved to be benign. Of the 88 cases diagnosed as benign disease, 10 patients were later demonstrated to have malignant neoplasm. The diagnoses of this latter group were believed to be misleading because representative samples of the lesions were not obtained. The single false-positive diagnosis resulted from the great difficulty in differentiating severe cellular atypia arising in severe inflammatory changes or pancreatic acinar cells removed from the bed of a giant perforating gastric ulcer. These changes can be associated with severe inflammation as well as with malignant neoplasia. This fact and the mechanical changes produced in the specimen by the crushing effect of the biopsy forceps make histopathologic diagnosis difficult in some instances.

Of the 88 patients whose biopsy specimens were diagnosed as non-

malignant, 20 patients were further treated surgically, and additional tissue was obtained for pathologic study. In 10 patients, as mentioned previously, malignant disease was present and in the other 10 patients benign lesions were again found. No diagnosis of lymphoma or reticulum cell sarcoma was noted in this group.

Of the 218 patients with gross lesions who did not have an endoscopic biopsy, the endoscopist made a visual diagnosis of malignancy or possible malignancy in regard to 32 patients. This diagnosis was proved by an added surgical exploration in 13 patients, including two who had reticulum cell sarcoma and one patient who had lymphocytic lymphoma.

### Discussion

Endoscopy was used as a diagnostic method for many different disease states both benign and malignant. Our biopsy efforts were concerned largely with confirming the presence or absence of malignant disease. In unusual instances malignancy was unexpectedly discovered and confirmed. More frequently, the biopsy made possible the unequivocal diagnosis of a malignant lesion the presence of which had been suspected on the basis of other data. It was sometimes possible to exclude the diagnosis of malignancy which had been strongly suggested by radiographic or other findings. Histologic classification of the neoplasm is an important consideration in selecting appropriate therapeutic measures: adenocarcinoma and squamous cell carcinoma of the esophagus present different problems for the surgeon; reticulum cell sarcoma and lymphoma may be treated by radiation or chemotherapy, but adenocarcinoma of the stomach must be excised if cure is to be attempted. With the histologic confirmation and classification established, the surgical attack on the tumor may be more direct, with a reduction in the chance of transplanting tumor cells, and a shortening of the anesthesia period. But the most important result of a positive biopsy is to speed the making of a decision and to facilitate the institution of appropriate therapy.

Definite gross variability does exist in the appearance of both benign and malignant disease processes, as seen through the endoscope as well as by roentgenographic evaluation; therefore biopsy mitigates against confusion.

No complications such as perforation or hemorrhage have occurred in our experience to date. The examination is prolonged significantly by the taking of biopsy specimens. Not all lesions viewed through the instrument can be reached by the forceps; the tip of the instrument must be relatively straight (not deflected) when the forceps is first advanced beyond the tip. If considerable manipulation is required to bring the lesion into view, this must be repeated for each specimen removed. Selection of the appropriate specimen is important: the bed of an ulcer will show only inflammatory tissue, but the margin should reveal the malignant cells when

they are present. Malignant changes also may not be present throughout the marginal circumference of an ulcerating neoplasm. Therefore, a single negative biopsy diagnosis may not exclude malignancy; multiple biopsies are recommended. Primary submucosal lesions such as lymphoma and leiomyosarcoma have been sampled with this instrument.

It is hoped that further experience and more frequent application of the biopsy technic will enable us to discover malignancy in its early curative stages. We also hope to gain a better understanding of the nature of various benign inflammatory lesions present in the esophagus and the stomach.

### Report of five illustrative cases

**Case 1.** A 55-year-old Caucasian man had a four-year history of burning epigastric pain coming on immediately after ingestion of certain foods. Diagnosis of gastric ulcer and gastritis had been previously proposed, but results of a current roentgenographic examination were normal except for evidence of a small hiatus hernia. Gastroscopic examination disclosed a small polyp approximately 1 cm wide and 1.5 cm high on the lesser curvature of the stomach. The polyp was quite firm and biopsy specimens were taken. Near this polyp was a patch of abnormal mucous membrane with several small irregular plaques that were elevated and yellowish. This tissue was soft when biopsied. Histologic examination showed adenocarcinoma in each specimen. Subtotal gastric resection was performed by our colleague, Dr. Stanley O. Hoerr, Department of General Surgery. No metastatic lesions were detected and it was thought that there was an excellent possibility of cure. Follow-up examination one year later, including roentgenographic and gastroscopic examination, demonstrated no evidence of recurrent tumor.

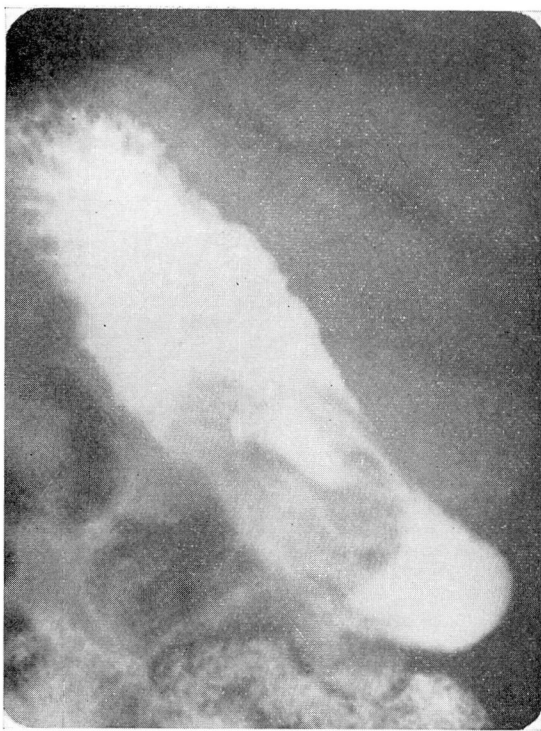
**Comment.** In this instance, endoscopic examination revealed a lesion not demonstrated roentgenographically. Biopsy permitted prompt surgical therapy that it is hoped will be curative.

**Case 2.** A 78-year-old Negro woman in August 1963 underwent a right simple mastectomy for cystosarcoma phylloides. In February 1969 she was hospitalized for heart disease, hypertension, and a cerebrovascular accident that left her unable to move her extremities or to speak. Anemia was detected, and upper gastrointestinal roentgenography demonstrated a large gastric ulcer on the greater curvature (*Fig. 2*). At gastroscopy a large polypoid tumor mass with central ulceration (*Fig. 3*) was detected. The gross appearance of this lesion was typical of a leiomyoma with ulceration. Biopsy from the surface of the tumor was not diagnostic, but a biopsy taken from deep in the ulcer crater showed a spindle cell neoplasm most compatible with leiomyosarcoma (*Fig. 4*). Fortunately no bleeding followed the biopsy. Gastrointestinal bleeding was not a complicating factor during the remainder of her life. She was discharged from the hospital in March 1969, and one year later died at home of heart disease.

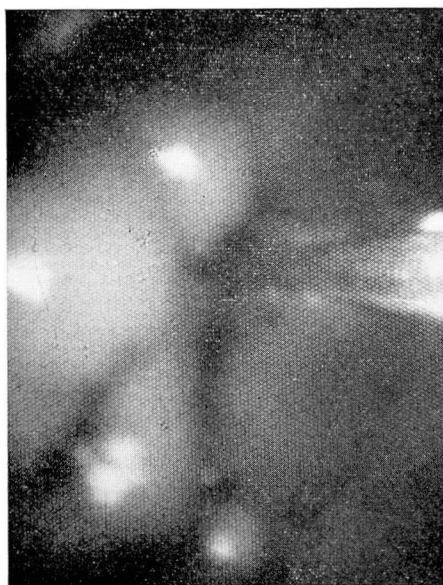**Comment:** In this instance, accurate diagnosis of the nature of the lesion permitted accurate prognostic and therapeutic advice. The gastric lesion was recognized as of secondary importance, and supportive measures only were employed.

**Case 3.** A 47-year-old Caucasian woman with a history of heavy use of alcohol, and peptic ulcer disease of seven years' duration had recently lost 20 pounds and had had severe constant epigastric pain for three months. At another hospital, hepatomegaly and malignant gastric ulcer (*Fig. 5*) were diagnosed. Gastric cytology was normal. Gastroscopic examination at the Cleveland Clinic was made to clarify the diagnosis and to obtain a biopsy. In the midportion of the stomach on the lesser curvature toward the anterior wall was a large ulcer 3 by 5 cm in diameter (*Fig. 6*). The margins were sharp, and normal-appearing gastric mucosa formed a rolled edge. In the center of the ulcer was smooth white tissue that seemed to protrude up from the ulcer base. On biopsy it was quite firm and bled only slightly. Histologic diagnosis was anaplastic carcinoma (*Fig. 7*). Laparotomy was per-

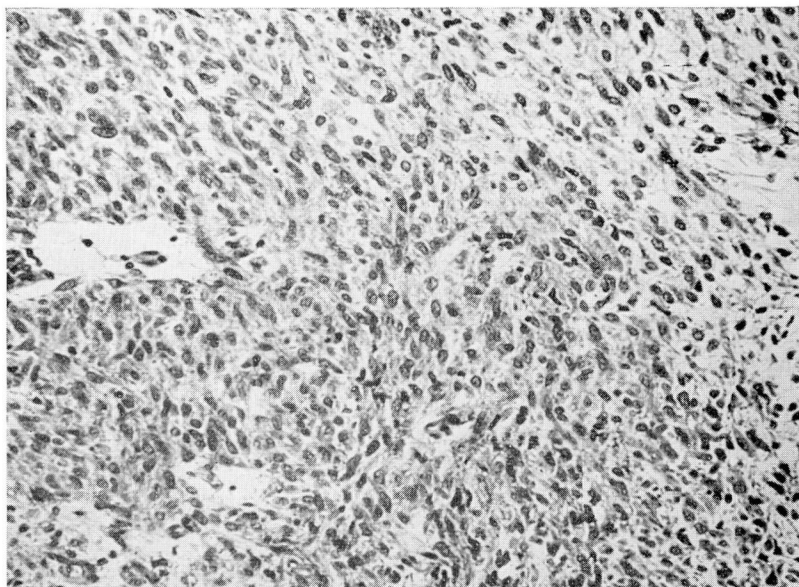




**Fig. 2.** Case 2. Roentgenogram demonstrates a large filling defect in the stomach. A large mass with central ulceration is present on the greater curvature aspect of the upper portion of the body of the stomach.



**Fig. 3.** Case 2. Endoscopic photograph of large lesion with central ulceration. The biopsy forceps can be seen on the right side of the photograph and are pointed into the ulcer crater.



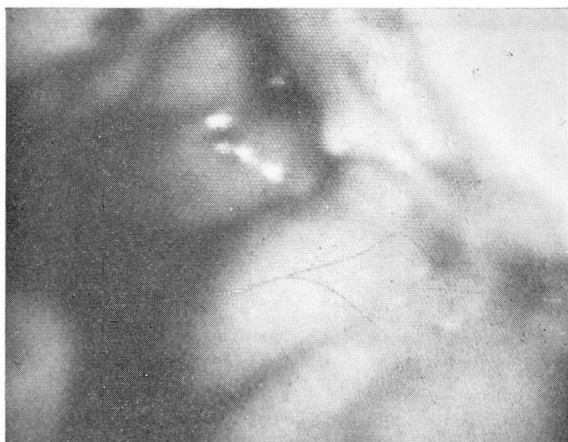**Fig. 4.** Case 2. Photomicrograph of leiomyosarcoma showing the uniform spindle cell pattern. Many mitotic forms were present. Hematoxylin and eosin stain; magnification  $\times 200$ .



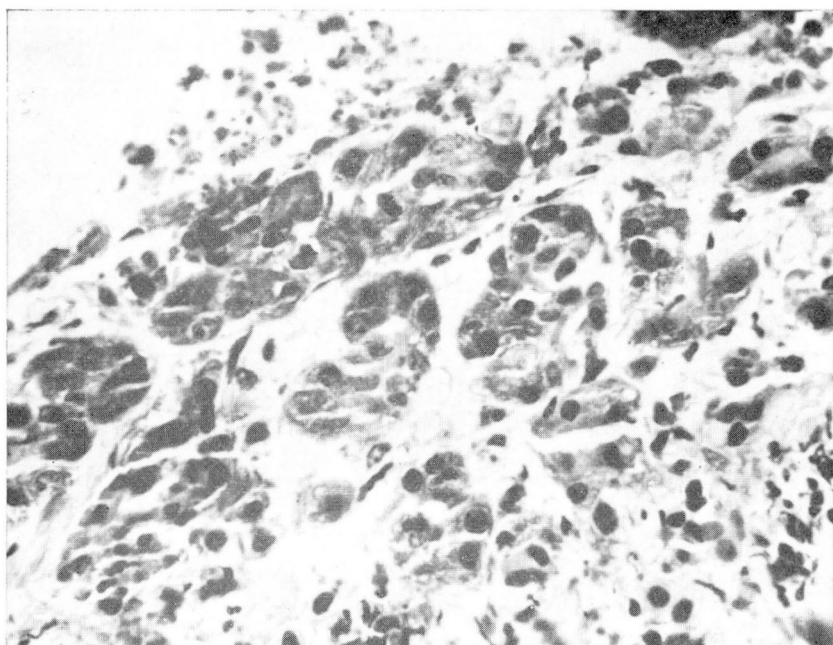
**Fig. 5.** Case 3. Roentgenogram demonstrates a large deep confined perforation extending from the greater curvature aspect of the upper portion of the stomach.



formed by Dr. Stanley O. Hoerr, who found a large gastric ulcer penetrating into the pancreas and another penetrating into the liver. Multiple histologic sections disclosed no neoplastic tissue (*Fig. 8 and 9*). The patient made an uneventful recovery from the extensive operation.



**Fig. 6.** Case 3. Endoscopic photograph showing the bed of the ulcer in the upper right-hand corner. This is, in fact, a scar tissue overlying the pancreas. The rolled margin of the ulcer passes from the upper left of the photograph diagonally down to the lower right.



**Fig. 7.** Case 3. Photomicrograph of biopsy material with atypical and distorted gland-like structures with atypical nuclei and back-to-back gland arrangement. Hematoxylin and eosin stain; magnification  $\times 500$ .



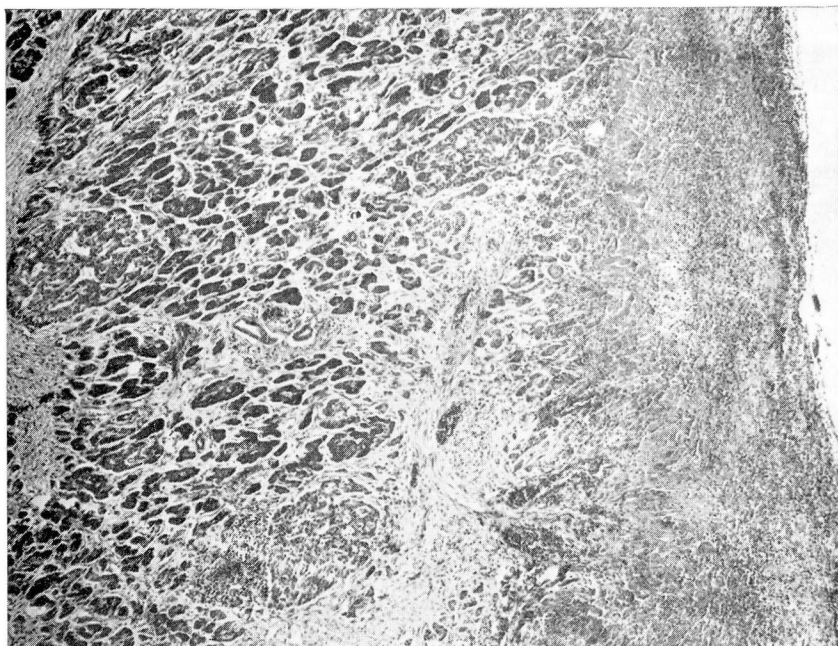


Fig. 8. Case 3. Photomicrograph of the deeply penetrating ulcer affecting the parenchyma of the pancreas. Acinar as well as islet cells are involved in the process. Hematoxylin and eosin stain; magnification  $\times 40$ .

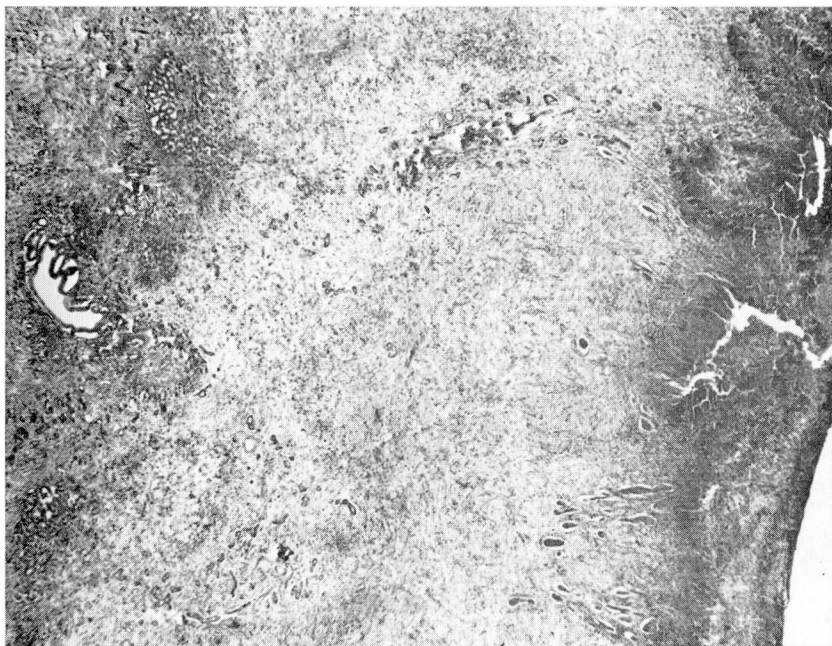
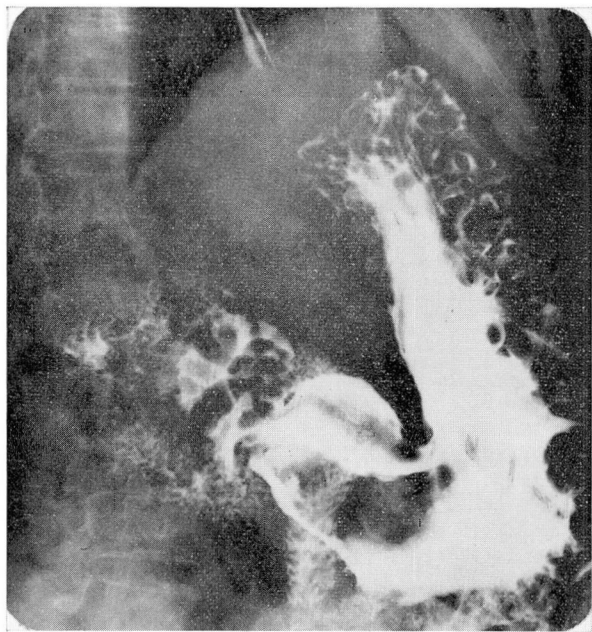
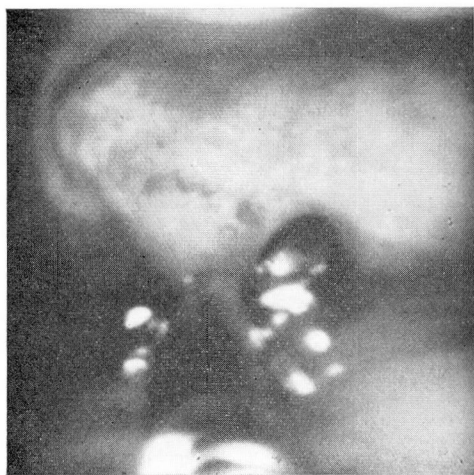


Fig. 9. Case 3. Deeply penetrating ulcer affecting the parenchyma of the liver. Remnants of bile ducts are preserved amongst the granulation tissue as well as portions of liver lobules on the left. Hematoxylin and eosin stain; magnification  $\times 20$ .

*Comment.* In this instance all members of the medical team—internist, surgeon, and pathologist—were predisposed to suspect carcinoma. It is believed that a few portions of distorted and inflamed pancreatic tissue imbedded in the base of the ulcer were misinterpreted as malignant neoplasm. This interpretation, however, did not adversely affect the clinical management of the condition.



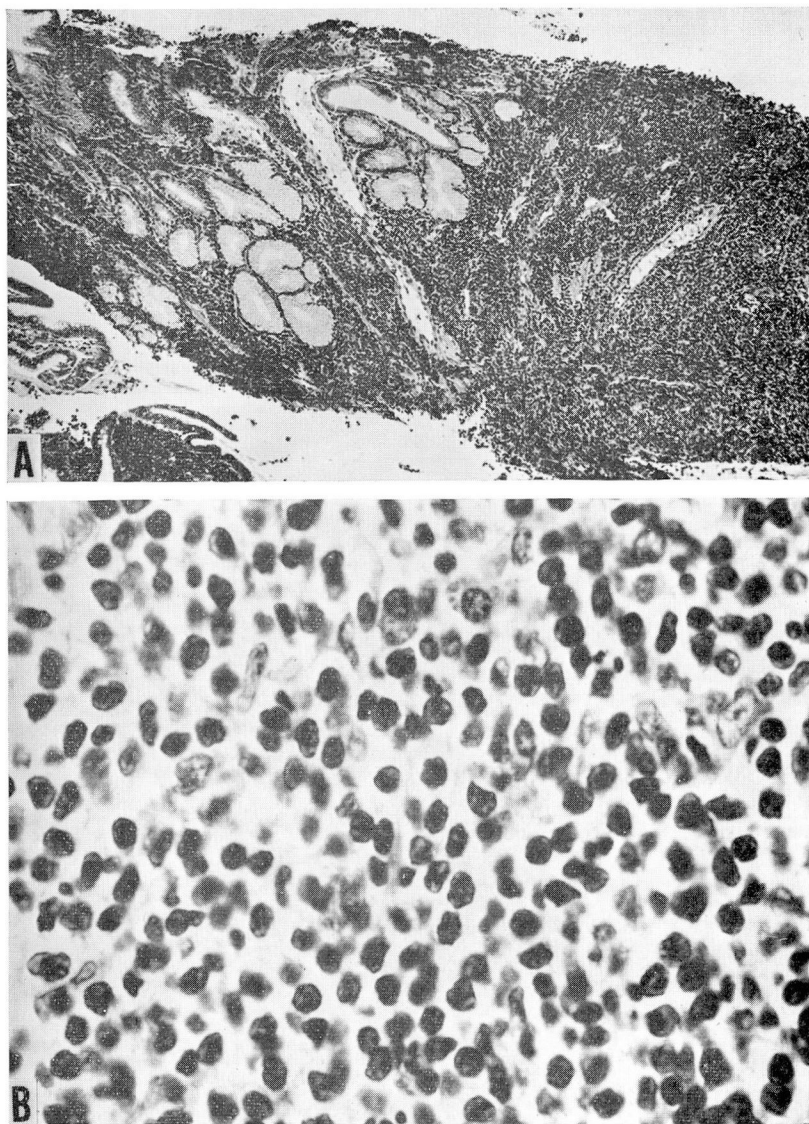
**Fig. 10.** Case 4. Roentgenogram demonstrates multiple areas of radiolucency representing large folds and tissue masses within the stomach.



**Fig. 11.** Case 4. Close-up view of one of the large tumor masses. The biopsy forceps are at the bottom of the photograph and the jaws of the forceps are open, preparatory to grasping a specimen.



**Case 4.** A 67-year-old Caucasian woman was first examined because she had lost 60 pounds in one year and had anorexia, tachycardia, and dizziness. Anemia was discovered, and an upper gastrointestinal roentgenographic examination showed evidence of a huge stomach filled with firm masses (*Fig. 10*). A tentative diagnosis of lymphoma of the stomach was made and the patient referred to our colleague, Dr. John D. Battle, Jr., Department of Hematology and Medical Oncology. Gastroscopy was performed to confirm or negate



**Fig. 12.** Case 4. A, Photomicrograph of biopsy material shows a dense infiltrate of small cells amongst gastric glands. Hematoxylin and eosin stain; magnification  $\times 64$ . B, Higher magnification reveals a uniform mature lymphocytic population of cells. Hematoxylin and eosin stain; magnification  $\times 800$ .

the roentgenographic findings, and to permit biopsy and histologic diagnosis. There was slight difficulty in passing the instrument through the cardia. Just inside the stomach large nodular masses were noted; these filled the stomach lumen. The masses were of various sizes and disposed longitudinally like large rugal folds; they seemed stiff, firm, and infiltrated. The mucosa covering the masses was paler than normal and somewhat granular (Fig. 11). Multiple biopsy specimens were taken. The pathology diagnosis was lymphocytic lymphoma, mature-cell type (Fig. 12). The patient was treated with radiation therapy and was reexamined four and one-half months later. The radiographs showed rugal folds still enlarged and distorted but much less abnormal than on the initial examination. Gastroscopic examination showed the folds to be still abnormal but not greatly enlarged. Biopsy showed an inflammatory reaction but no definite evidence of lymphoma.

*Comment.* In this instance histologic confirmation of the diagnosis was obtained with little discomfort to the patient, permitting prompt institution of appropriate therapy. Follow-up evaluation may be important at a later date should there be a recurrence of the lesion.

**Case 5.** A 74-year-old Caucasian man had taken glutamic acid hydrochloride for 30 years because of presumed achlorhydria. No significant gastrointestinal symptoms were present at the time of study, but the death of a brother with carcinoma of the liver caused him to seek medical advice. Radiographic examination showed a small filling defect on the greater curvature of the upper portion of the gastric antrum, and also what appeared to be a fairly large filling defect on the greater curvature in the midportion of the body of the stomach. Gastroscopy was used to confirm the presence or absence of the masses and to obtain a biopsy specimen. The gastric mucosa throughout the stomach was thin and atrophic. A benign-appearing mucosal polyp approximately 8 mm in diameter was noted on the posterior wall near the greater curvature in the antrum. The upper portion of the stomach was well seen and no masses were present. The instrument was turned for retrograde views of the fornix and cardia of the stomach. No lesion was seen. Biopsy was made of the polyp, and demonstrated mucosal inflammatory change, no malignant neoplasm.

*Comment.* In this instance an unnecessary laparotomy was avoided by the ability of the endoscopist to clarify the roentgen findings and to provide histologic evidence of the benign nature of the lesion discovered.

## Summary

Biopsy specimens were taken during 121 of the 631 peroral gastrointestinal endoscopic examinations in the Department of Gastroenterology at the Cleveland Clinic during 1969. Accurate diagnoses were made in regard to 110 of the 121 cases. There were no complications from the procedure. Prompt definitive diagnosis of malignant disease facilitated early institution of appropriate treatment in all cases.

Biopsy would have been useful in an additional 218 cases, but was not performed. The nature of the lesions was such that the procedure seemed inadvisable or unnecessary in 292 cases.