

Lipomas in the hand and wrist

Diagnosis and treatment

JUAN M. RODRIGUEZ, M.D.*

GEORGE S. PHALEN, M.D.

Department of Orthopaedic Surgery

OF all the benign soft-tissue tumors, lipomas are the most frequently encountered. The presence of a small lipoma on the back or about the hip or shoulder is seldom even mentioned in a routine physical examination unless the patient has some symptoms referable to the tumor. The doughy, cystic feeling of a subcutaneous lipoma is so typical that the examining physician may assure his patient that the tumor is benign and excision is not necessary unless the tumor is causing pain, is increasing in size, or is lying in a region that is subject to constant irritation.

Despite the fact that there is a moderate amount of fat distributed throughout the hand and wrist, lipomas in these sites are not common. Less than 50 lipomas of the hand have been reported in the literature, and the majority of these reports were of a single case.¹⁻⁴ In a series of 500 benign subcutaneous tumors of the hand seen at our institution during a 10-year period, there were only seven lipomas.⁵

We have recently reviewed the records of all patients with the diagnosis of lipoma of the upper extremity, seen at the Cleveland Clinic during the period 1948 to 1967.⁶ There were 247 patients in this series; 112 patients underwent surgical excision of the tumors, and pathologic examination revealed a benign lipoma in each specimen.

In our series of 112 pathologically proved lipomas there were 12 in the hand—one affecting the entire palm, two each in the thenar eminence, four each on the dorsum, and five each in the digits. There were also three lipomas each on the volar aspect of the wrist.

The ages of the patients with lipomas in the hand or wrist ranged from 44 years to 67 years, with an average age of 56 years. Two of the patients were Negroes, and 13 were Caucasians. There were six women and nine men.

Diagnosis

Although most lipomas are subcutaneous, these tumors may also be intermuscular, intramuscular, parosteal, or visceral. Deep or subfascial lipomas are not easy to palpate; these are the tumors that often cause

* Fellow, Department of Orthopaedic Surgery.

symptoms and usually require excision. Roentgenographic examination, using a soft-tissue technic, will often be helpful in making the diagnosis of a deep lipoma. Because fat ranks second to air in radiolucency, lipomas present a characteristic area of decreased density in contrast to the adjacent soft tissues (Fig. 1 C). The examining physician must also remember that a lipoma does not transilluminate as a ganglion does, and local applications of ice may cause a lipoma to lose its cystic feeling.

It is often difficult to recognize a lipoma in the palm because the tumor beneath the tense elastic palmar fascia feels entirely different from the way a subcutaneous lipoma feels. The palmar lipoma feels much more firm and less cystic than the same type of tumor in more lax surroundings. The palmar lipoma may present itself in one or many separate locations—wherever there is a defect in the palmar fascia. The tumor may be localized to the thenar area (Fig. 1 B) or to the hypothenar eminence; or the tumor may affect the entire palm with extensions up into the lumbrical canals. Lipomas that originate on the dorsum of the hand may often extend into the palm.

Lipomas of the palm are usually classified into two groups—a superficial or subcutaneous group, and a deep or subfascial group.⁷ The deep lipomas usually lie outside the tendon sheaths (epivaginal) but occasionally the tumor may grow within the tendon sheaths (endovaginal). The three palmar lipomas in our series were all epivaginal.

A ganglion is a cystic subcutaneous swelling that is so frequently encountered in the hand or wrist that lipomas in those areas are often diagnosed initially as ganglions. The characteristic radiolucency of a lipoma and its lack of transillumination readily differentiate the two cystic swell-

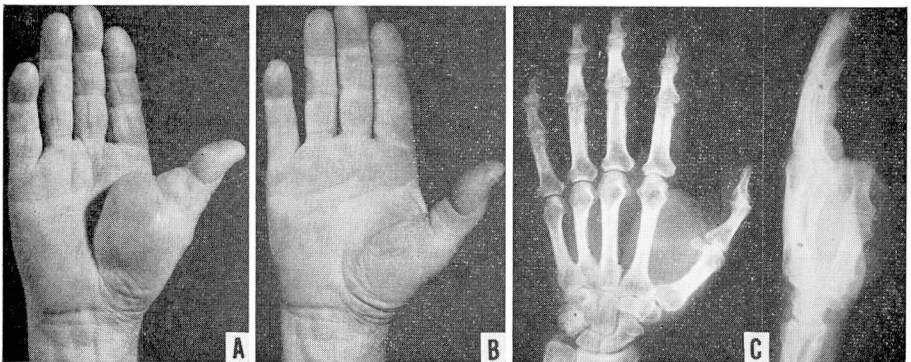


Fig. 1. A, Photo of lipoma of the thenar eminence in a 63-year-old man. This tumor caused no pain but interfered with grasp. B, Appearance of hand two months postoperatively. There has been no recurrence in 13 years. C, Anteroposterior and lateral roentgenograms of same hand preoperatively, showing soft-tissue tumor in first web with radiolucency compatible with diagnosis of lipoma.

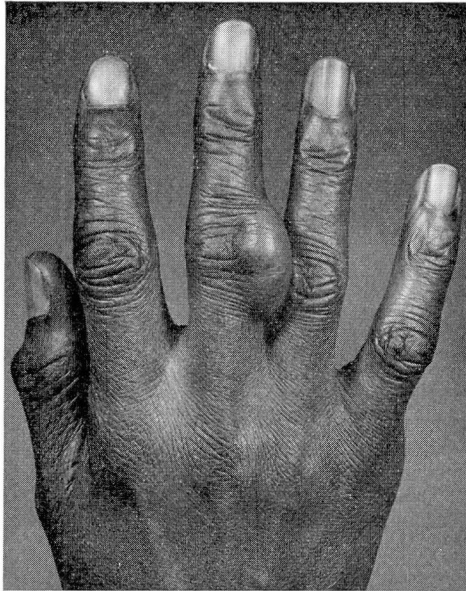


Fig. 2. Photo of dorsum of the hand of a 51-year-old woman. This cystic-feeling, painless tumor of the middle finger had been present for at least 23 years. A preoperative diagnosis of ganglion was made; a typical lipoma was excised.

ings. In our series of 15 lipomas, a preoperative diagnosis of ganglion was made for four patients (*Fig. 2*).

Lipomas are essentially asymptomatic. In the hand, lipomas often produce a feeling of fullness or clumsiness. It is apparent that a tumor as large as the one shown in *Figure 1 A and B* would reduce the dexterity of the hand as well as reduce the size of objects that could be adequately grasped. Of the 15 patients in this series, in 14 there was no significant restriction of motion in the wrist or hand; one patient had pain and restriction of motion in his hand because of rheumatoid arthritis.

None of the tumors in the hand caused nerve compression, but one of the tumors on the volar aspect of the wrist caused slight compression of the median nerve. That tumor was in a 45-year-old Caucasian man who had noticed numbness and tingling in his thumb, and index and middle fingers of his right hand for two weeks. There was no history of injury. The episodes of numbness would recur at least six times each day and would last about five minutes each time. Examination revealed absence of Tinel's sign over the median nerve at the wrist, a negative wrist flexion test for carpal-tunnel syndrome,⁸ no thenar atrophy, and only subjective numbness in the median distribution in the hand. There was a small (approximately 15 mm by 7 mm) subcutaneous, cystic-feeling, non-tender, mass lying beneath the deep fascia at the level of the proximal margin of

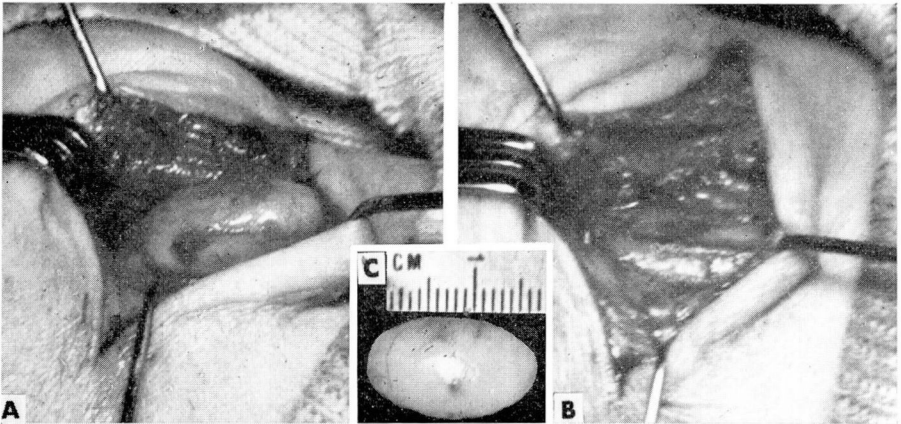


Fig. 3. A, Photo of lipoma on volar aspect of the wrist of a 44-year-old man. Through a transverse incision at the wrist, the deep fascia has been incised, exposing a well-encapsulated lipoma. (The thenar eminence is at the left side of the photo.) B, The lipoma was removed, revealing a slight compression in the median nerve. C, Photo of excised lipoma.

the transverse carpal ligament. The patient stated that this mass had been present only for the last two months. The tumor did not move with the flexor tendons of the fingers. Roentgenograms of the hand and wrist showed no evidence of abnormality.

Because the initial diagnosis of a ganglion was made, a needle was passed into the tumor, but it was not possible to aspirate any fluid. A small amount of Novocain and steroid was injected around the area of the tumor and about the flexor tendons at the wrist. This injection completely relieved all symptoms for the next five months, and then numbness and tingling in the median distribution in the hand recurred.

At the time of surgery, a typical, well-encapsulated lipoma was found lying immediately beneath the deep fascia, and this tumor was compressing the median nerve slightly (*Fig. 3 A, B, and C*). After removal of the tumor, the patient has had no further symptoms during the last three years.

Treatment

Surgical excision is the preferred treatment, even though the tumor may be asymptomatic. Because of the rarity of lipomas in the hand, surgical removal is recommended by the surgeon and usually requested by the patient in order to make an adequate diagnosis of the swelling. These tumors are well encapsulated and are easily removed. They tend to insinuate themselves around and between the vessels, nerves, and tendons in the palm; and they often extend distally into the lumbrical canals. Care must be taken to remove all of the tumor without damaging any of the soft-tissue structures.

As in most hand surgery, this can be accomplished only in a bloodless field obtained by use of a pneumatic tourniquet about the upper arm.

One of the tumors in our series was on the dorsum of the hand between the second and third metacarpals. Before the patient was examined by one of us, he had undergone two attempts at surgical removal of the lipoma, with recurrence following each operation. At the time of his operation here, it was observed that the lipoma had extended into the interosseous muscles, and for complete removal of the tumor it was necessary to remove a portion of these muscles. The pathologic diagnosis of this specimen was benign lipoma, and there has been no recurrence of this tumor in 21 years. If a lipoma is not completely removed, recurrence is most likely.⁹

The length of follow-up study in our series ranged from two years to 21 years, with an average of 7.8 years. There were no recurrences of tumor, and no postoperative complications.

Summary

In a series of 112 proved lipomas of the upper extremity, there were 12 tumors in the hand and three tumors in the wrist. Although lipomas of the wrist and hand are not common, the examining physician must include lipoma in his differential diagnosis of soft-tissue tumors in those regions.

References

1. Adair, F. E.; Pack, G. T., and Fariior, J. H.: Lipomas. *Amer. J. Cancer* **16**: 1104-1120, 1932.
2. Butler, E. D., and others: Tumors of the hand; a ten-year survey and report of 437 cases. *Amer. J. Surg.* **100**: 293-302, 1960.
3. Booher, R. J.: Lipoblastic tumors of the hands and feet; review of the literature and report of thirty-three cases. *J. Bone Joint Surg.* **47-A**: 727-740, 1965.
4. White, W. L., and Hanna, D. C.: Troublesome lipomata of the upper extremity. *J. Bone Joint Surg.* **44-A**: 1353-1359, 1962.
5. Phalen, G. S.; Kendrick, J. I., and McCormack, L. J.: Exhibit and Instructional Course, American Academy of Orthopaedic Surgeons: Benign Soft-Tissue Tumors of the Hand. *J. Bone Joint Surg.* **42-A**: 902, 1960.
6. Phalen, G. S.; Kendrick, J. I., and Rodriguez, J. M.: Lipomas of the upper extremity; report of fifteen cases in the hand and wrist and six cases causing nerve compression. *Amer. J. Surg.* In press.
7. Mason, M. L.: Tumors of the hand. *Surg. Gynec. Obstet.* **64**: 129-148, 1937.
8. Phalen, G. S.: The diagnosis of carpal tunnel syndrome. *Cleveland Clin. Quart.* **35**: 1-6, 1968.
9. Hueston, J. T.: Massive lipoma of the hand. *Aust. New Zeal. J. Surg.* **34**: 194-195, 1965.