

Corynebacterium pyogenes—a pathogen in man

Report of a case

LUIS EDUARDO VEGA, M.D.*

THOMAS L. GAVAN, M.D.
Department of Microbiology

THE number of published reports concerning clinical infections produced by microorganisms considered to be nonpathogenic in man increases each year. Most of the cases are opportunistic infections in patients whose immune mechanisms have been altered by disease or treatment. In general, we believe that many of these "rare" organisms are probably not so infrequent in man as they have been thought to be. In clinical medicine, many of the diseases that in the past were considered to be rare are at the present time not so uncommon. In most cases, the incidence of a disease has not actually increased, but the number of diagnoses has increased because of improved methods of detection.

The history of *Corynebacterium pyogenes* as an agent capable of producing disease in man dates from 1939 and the reports^{1, 2} of the case of a 64-year old shepherd who succumbed to systemic infection due to *Corynebacterium pyogenes* after an initial superficial abscess caused by that organism (*Table I*).

Eight years later, in 1947, Ballard, Upsher, and Seely³ reported the case of a 37-year-old truck driver who had frostbite of both feet, which eventually required amputation of several toes. A septic syndrome developed and a pure culture of *Corynebacterium pyogenes* was isolated from his blood. Later the same bacteria were isolated from draining sinuses of his feet. The septicemia responded rapidly to sulfanilamide, but the lesions on the feet never regressed, and *Corynebacterium pyogenes* was repeatedly grown from exudates as long as 18 months after the patient was discharged from the hospital.

In 1954, Laufe,⁴ working in a United States Army Hospital in Japan, reported 32 cases of severe acute ulcerative vulvovaginitis due to *Corynebacterium pyogenes*. Twenty-six of the cases were proved to be caused by *Corynebacterium pyogenes* and, in the other six cases, there was enough clinical and epidemiologic evidence to suggest the same causal organism. Thirty of the cases occurred within five months. None of the 32 cases responded to antibiotics, and in vitro susceptibility studies showed the organisms to be resistant to all antibiotics used (penicillin, chlortetracycline

* Fellow, Division of Laboratory Medicine.

Table 1.—Data of published cases¹⁻⁵ of human infection with *Corynebacterium pyogenes*, including case at Cleveland Clinic

Year reported	Reference, author(s)	Number of patients, sex, occupation	Age, yr	Clinical diagnosis	Treatment	Clinical course
1939	Halbron,	1 male, shep-	64	Superficial abscess;	Potassium iodide	Death
1940	Forgeot, and others ^{1, 2}	herd		systemic infection		
1947	Ballard, Upsher, and Seely ³	1 male, truck driver	37	Frostbite, septicemia, draining sinuses in feet	Sulfanilamide	Cleared from blood but not from feet
1954	Lauf ⁴	32 females	(Child-bearing age)	Acute ulcerative vulvovaginitis	Antibiotics and (or) topical agents	Resistant to antibiotics; spontaneous cures
1970	Chlosta and associates ⁵	1 female, housewife	39	Carcinoma of the breast; empyema	Penicillin	Infection cleared
1970	Vega and Gavan (Cleveland Clinic)	1 female, housewife	57	Chronic atypical pneumonitis (lipid)	Oxacillin and dicloxacillin	No change; vasovagal death

hydrochloride, streptomycin, and chloramphenicol). In these cases the infection appeared to be self-limiting, lasting from 15 to 19 days, independent of treatment.

Sixteen years elapsed until the next report was published. In February 1970, Chlosta and associates⁵ reported a case of a 39-year-old housewife who for four years had a fungating carcinoma of the left breast. She had consulted no physician because she was "afraid of surgery." She was in the terminal stage of disease, and in addition to metastases had a massive right pleural effusion from which a pure culture of *Corynebacterium pyogenes* was obtained on several occasions. This empyema was successfully treated with penicillin and pleural drainage.

Although reports of human infection with this organism are few, *Corynebacterium pyogenes* is a common pathogen among animals—it is the most common single organism responsible for purulent infections in cattle, swine, and sheep.^{6, 7}

We recently had the opportunity to study extensively a case of human infection caused by this organism.

Report of a case

A 57-year-old housewife was admitted to the Cleveland Clinic Hospital in January 1970 because of a history of chronic nonresolving pneumonitis of fairly recent onset. Roentgenograms initially had shown evidence of a dense alveolar infiltrate in both lower lobes (*Fig. 1*). These findings were considered to be consistent with atypical pneumonia, probably fungal or tuberculous. Skin tests for coccidiomycosis, histoplasmosis, and tuberculosis proved negative. Repeated sputum cultures and all other diagnostic tests were negative. The leukocyte count never exceeded 10,000 per cubic millimeter, and her temperature was never above 100.5 F. On her eighth hospital day a brief vasovagal reaction developed while she was undergoing lung biopsy that proved to be unsuccessful. Eleven days after this episode when her clinical status and roentgenograms still showed no improvement despite administration of antibiotics and intermittent positive-pressure breathing, a second lung biopsy was attempted and this time irreversible pleural shock developed.

At autopsy, a pure culture of pleomorphic gram-positive bacilli was obtained from the lower lobes and identified as *Corynebacterium pyogenes* by one of us (L.E.V.). Sections of the lungs (*Fig. 2*) showed an extensive interstitial fibrosis with focal organizing bronchopneumonia. There were severe bronchiectasis and an extensive foreign-body giant cell infiltrate. Oil red O stains were positive for lipid within the macrophages and giant cells, and also free in some of the distorted alveolar spaces. The clinical and pathologic findings were consistent with bronchopneumonia complicating an atypical chronic fibrosing pneumonitis highly suggestive of lipid pneumonitis. The patient had, in fact, been subject all her life to sinus congestion, and probably used large amounts of nose drops and sprays.

Lung sections were stained by the Brown-Brenn technic, in search of bacteria, and many were found in the diseased tissues (*Fig. 3*). The bacteria varied in shape from slender rods to extremely small cocci. Most were found in lymphatics, though some were also seen in alveoli and terminal bronchioles. We can only speculate that these represent the microorganisms that were isolated at the time of autopsy.

Bacteriologic characteristics

Corynebacterium pyogenes is a pleomorphic gram-positive bacillus that, when grown in thioglycollate medium, is usually coccoid in shape. It is characteristically nonmotile and is the only *Corynebacterium* that is cata-

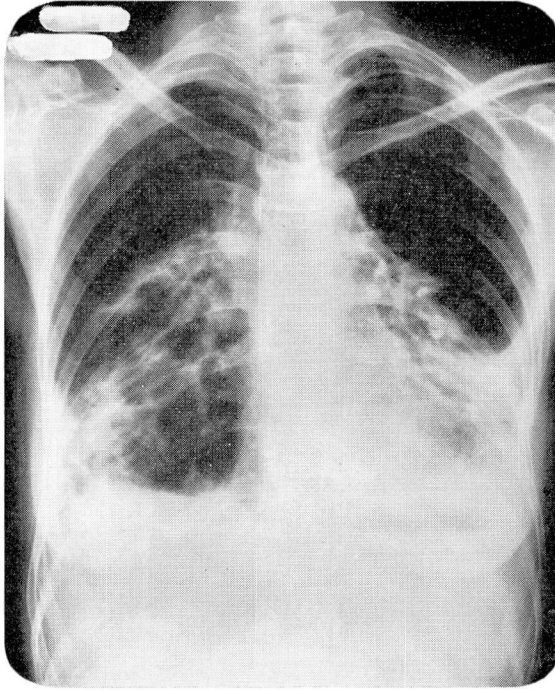


Fig. 1. Roentgenogram (eight days before death) shows dense alveolar infiltrate and fibrosis in lower lung lobes.

lase-negative. It grows well on blood agar, phenylethyl alcohol agar, and chocolate agar. It does not grow on MacConkey agar, and on Mueller-Hinton agar it produces a poor and slow growth, making antimicrobial susceptibility tests by the disk method impractical. It grows both aerobically and anaerobically, and it also has a wide temperature range that includes room temperature. On blood agar, it produces a small zone of beta hemolysis that has been described⁶ as a “soft” type of beta hemolysis.

On subcultures and especially in thioglycollate medium, coccal forms are common, representing perhaps 98 percent or more of the bacteria in a gram stain. In liquid media, beaded chains are quite common. Bizarre forms can also be seen, and these are especially abundant in gram stain from colonies grown on chocolate agar.

Corynebacterium pyogenes is negative for catalase, oxidase, motility, urease, nitrate reduction, phenylalanine deaminase, and indole production. Gelatinase production, though negative in some human pathogenic strains (as in the case we report), is apparently positive in the majority of animal pathogenic strains.^{5, 6} *Corynebacterium pyogenes* produces acid from dextrose, maltose, sucrose, and lactose. It does not produce acid from mannitol, inulin, inositol, or dulcitol. The strain we isolated produced acid from

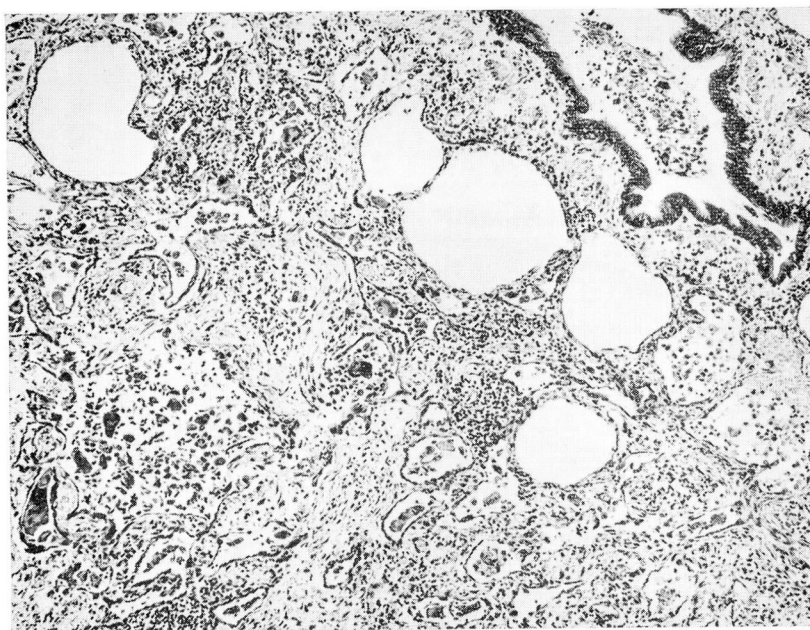


Fig. 2. Histologic section of lung shows extensive interstitial fibrosis, bronchiolar and alveolar dilatation, inflammatory and giant cell infiltrate, and general destruction of pulmonary architecture. Hematoxylin-eosin stain; magnification $\times 65$.

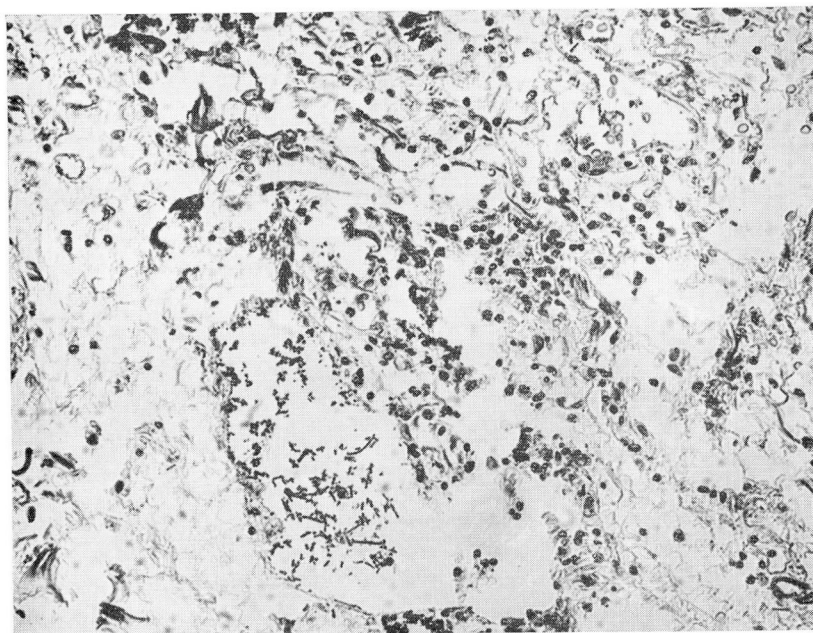


Fig. 3. Histologic section of lung shows bacillary and coccoid bacteria in distorted alveolar space. Brown-Brenn stain; magnification $\times 200$.

Table 2.—Carbohydrate fermentation characteristics of *Corynebacterium pyogenes* presented in publications

Carbohydrate	Vega and Gavan (Cleveland Clinic) (1970)	Ballard, Upsher, and Seely ³ (1947)	Chlosta and others ⁵ (1970)	Bergey's Manual of Determinative Bacteriology ⁸ (1957)	Roberts ⁶ (1968)*
	Reactions				
Dextrose	+	+	+	+	100%
Maltose	+	+	+	No data	61%
Sucrose	+	+	+	+	44%
Lactose	+	+	+	+	79%
Raffinose	+	No data	No data	—	0%
	(delayed)				
Salicin	+	No data	—	—	0%
Dulcitol	—	No data	No data	No data	0%
Inositol	—	No data	No data	No data	21%
Inulin	—	No data	No data	—	0%
Mannitol	—	—	No data	—	10%

* Percentages in this column represent positive results of 100 animal strains.

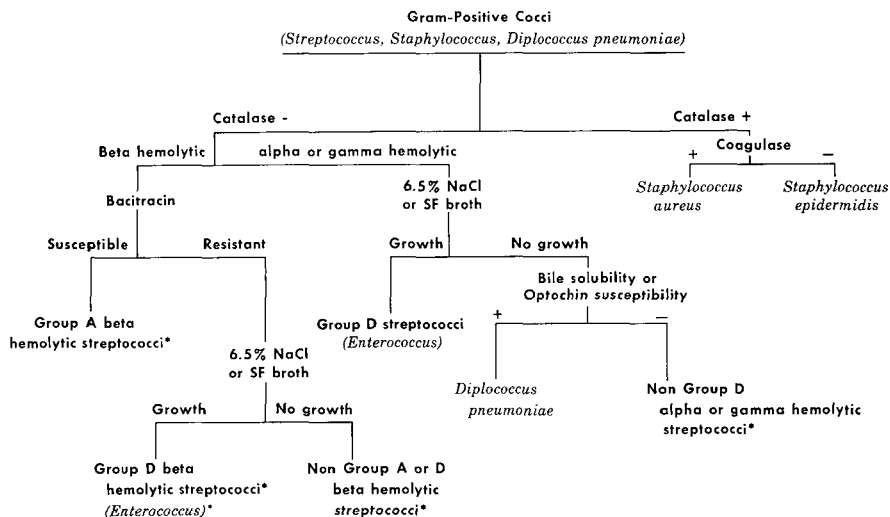
raffinose and salicin, whereas all animal pathogenic strains reported by Roberts⁶ did not ferment those carbohydrates. (Table 2.)

If gram stains are not performed from surface colonies, this bacterium can easily be misidentified as a gram-positive coccus that will then be classified as a *Streptococcus*, beta hemolytic, not Group A or D (Fig. 4). It is important to note that Chlosta and associates⁵ state that the present classification of *Corynebacterium pyogenes* is apparently insecure and that some authors believe that it should be placed in the genus *Streptococcus*, since it is catalase-negative, it has a large proportion of coccoid forms, and the chemical composition of the cell wall hydrolysates is similar to that of streptococci. In fact, formamine extracts of *Corynebacterium pyogenes* react with several Group G streptococcal antisera.⁵

When the organism has been correctly identified as a gram-positive bacillus it can easily be distinguished from the rest of the non-acid fast, non-spore formers (Fig. 5).

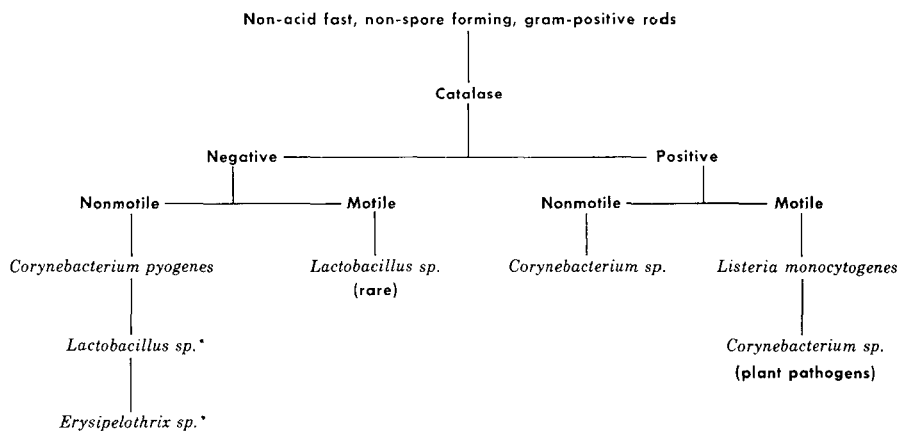
Summary

We have presented a case report of human infection due to *Corynebacterium pyogenes*. On review of the literature, we have found that in only one instance was this organism implicated as lethal in man, and that was the case of the shepherd in France in 1939 when antimicrobial agents were not generally available. In some instances, the infection appears to be of the



*The Lancefield grouping may be confirmed by Lancefield precipitin test or fluorescent antibody test with group specific antisera.

Fig. 4. Scheme for the identification of gram-positive cocci.



* *Lactobacillus* and *Erysipelothrix* can easily be differentiated from *Corynebacterium pyogenes* by other biological characteristics⁸

Fig. 5. Scheme for the identification of non-acid fast, non-spore forming, gram-positive rods.

opportunistic type, though cases reported by Laufe⁴ seem to have had an epidemic-like origin.

Practically all affected patients have shown a highly atypical infectious picture, with little or no fever and a normal or only slightly elevated leukocyte count. Quantitative immunoglobulin electrophoresis has been performed on sera of only two of the patients affected, the patient in the recent case reported by Chlosta and associates⁵ and the patient whose case we reported; in both instances, results were within normal limits.

We can offer no conclusions as to why some of the infections have responded well to antibiotic treatment, while others have not responded at all. We postulate that this common pathogen in animals, *Corynebacterium pyogenes*, produces infection in man much more commonly than anticipated. Its streptococcus-like properties probably mask its identification in clinical microbiology laboratories where only material of human origin is analyzed.

Addendum

On studying this case, we were stimulated to review the recent records of our microbiology laboratory and we found a case of subacute bacterial endocarditis also caused by *Corynebacterium pyogenes*.

References

1. Halbron, P., and others: Abcès multiples chez un berger dus au pyobacille du mouton "Coryne bacterium pyogenes." Bull. mém. Soc. Méd. hôp. Paris 55: 1373-1376, 1939.
2. Forgeot, P.; Halbron, P., and Lévy-Bruhl, M.: Pyobacillôse généralisée mortelle chez un berger. Ann. l'Inst. Pasteur 65: 326-335, 1940.
3. Ballard, D. O.; Upsher, A. E., and Seely, D. D.: Infection with *Corynebacterium pyogenes* in man. Amer. J. Clin. Path. 17: 209-215, 1947.
4. Laufe, L. E.: Acute ulcerative vulvovaginitis; due to *Corynebacterium pyogenes*. Obstet. Gynec. 3: 46-49, 1954.
5. Chlosta, E. M., and others: An opportunistic infection with *Corynebacterium pyogenes* producing empyema. Amer. J. Clin. Path. 53: 167-170, 1970.
6. Roberts, R. J.: Biochemical reactions of *Corynebacterium pyogenes*. J. Path. Bact. 95: 127-130, 1968.
7. Roberts, R. J.: A numerical taxonomic study of 100 isolates of *Corynebacterium pyogenes*. J. Gen. Microbiol. 53: 299-303, 1968.
8. Breed, R. S.; Murray, E. G. D., and Smith, N. R. (editors): Bergey's Manual of Determinative Bacteriology, 7th ed. Baltimore: Williams & Wilkins Co., 1957, 1132 p.; p. 585.