

# Metastatic cells in bone marrow

## *Study of 83 cases*

GERALD PITTMAN, M.D.\*  
Division of Laboratory Medicine

KENNETH S. K. TUNG, M.B., B.S.†  
Department of Pathology

GEORGE C. HOFFMAN, M.B., B.CHIR., M.R.C. PATH.  
Department of Laboratory Hematology

THE presence of metastatic cells in a bone marrow aspirate was reported by Rohr and Hegglin<sup>1</sup> in 1936. The incidence of such a finding and the importance attached to it vary considerably in reports published since that time. Our report concerns a retrospective study of the case records of 83 patients whose bone marrows were found to contain metastatic cells. The purpose of the study was to determine the significance of bone marrow findings and to correlate the presence of metastatic cells with other laboratory findings.

### Materials and methods

From 1959 through 1970 approximately 7,000 bone marrow aspirates were performed at the Cleveland Clinic. Of these, 83 contained metastatic cells, and are the basis of this study. In this group of patients, the indications for bone marrow aspirations varied widely, but it was not a part of the routine investigation of patients with cancer. Patients with myeloma, leukemia, or lymphoma were excluded from the study. The clinical record of each patient was reviewed, and the various investigations that led to the diagnosis of cancer were related temporally to one another. These investigations included the medical history, physical examination, roentgenographic findings, biopsy of the primary tumor, and bone marrow aspiration. The complete blood count, serum alkaline phosphatase content, and the duration of survival of each patient after bone marrow aspiration were observed when such information was available.

The bone marrow specimens were obtained from the sternum or from the posterior iliac crest. The aspirates were spread on coverslips and stained with Wright's stain. Sections of marrow particles or clots were not prepared. The

\*Fellow, Division of Laboratory Medicine.

† Former Fellow, Department of Pathology, The Cleveland Clinic Foundation, Cleveland, Ohio. Present address: Department of Pathology, St. Louis University School of Medicine, 1402 South Grand Boulevard, St. Louis, Missouri 63104.

cellularity of the aspirates was judged on the basis of few or many neoplastic cells, and also on the basis of reduced or normal numbers of marrow elements. Thus, there were four possible categories. With respect to tumor cells, Group I contained only a few scattered metastatic cells or rare, small clumps. In Group II, frequent clumps or large sheets of metastatic cells were present. With respect to the cellularity of normal marrow elements, Group A contained less than 50 percent of normal marrow elements, and Group B contained 50 percent or more normal marrow elements.

Findings

The group of 83 patients comprised 44 males and 39 females. There were eight children whose ages ranged from 2 to 12 years. The ages of the 75 adults ranged from 26 to 77 years.

In 60 patients the origin of the neoplasm was verified by histologic examination of the primary lesion. In five patients the origin was strongly indicated by roentgenographic evidence. In the other 18 patients the origin was not determined; in seven of those patients the only tissue available for histologic study was bone marrow, and in 11 the neoplasms were so widespread and anaplastic that it was not possible to determine their origin.

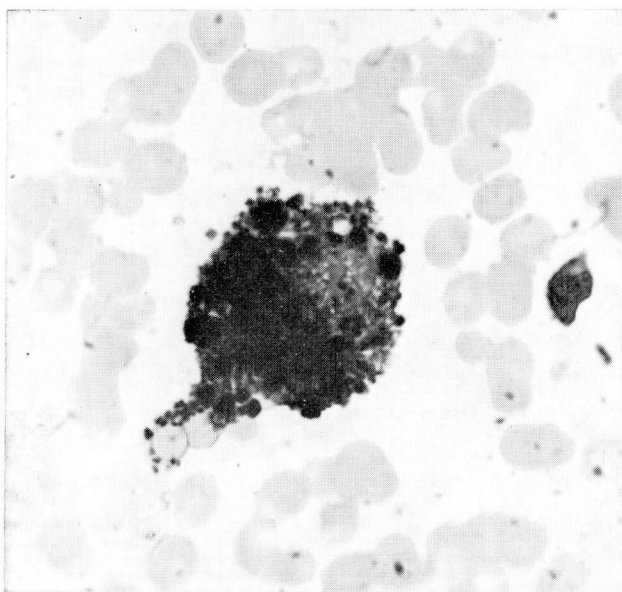
In women, carcinoma of the breast was the commonest primary tumor. In men, carcinoma of the prostate was the commonest (*Table 1*). All examples of carcinoma of the lung, the second most frequent primary neoplasm in men, were of the small-cell type (oat-cell carcinoma). Neuroblastoma or retinoblastoma was the primary neoplasm in seven of the eight children. The morphology of the malignant cells in the bone marrow aspirates offered no

**Table 1.**—Site or type of primary neoplasms in 83 patients whose bone marrow aspirates contained metastatic neoplasms

Site or type of primary neoplasm	Patients, number	
	Male	Female
Breast	0	22
Prostate	13	0
Lung	10	0
Neuroblastoma and retinoblastoma	3	4
Miscellaneous	5*	8†
Anaplastic or not known	13	5
Total	44	39

\* Bladder, melanoma, kidney, stomach, mouth.

† Cecum, pancreas, stomach (2), angiosarcoma (liver), ovary, ependymoblastoma, rhabdomyosarcoma (nose).



**Fig. 1.** Malignant melanoma with the characteristic granular pigment. Wright's stain; magnification  $\times 800$ .

basis for predicting the origin of the cancer except in one instance. The exception was a pigmented malignant melanoma (*Fig. 1*), a finding previously described by Battle and Stasney.<sup>2</sup> Metastases from the same organ were often strikingly dissimilar (*Fig. 2 A and B*); whereas, metastases from different organs were sometimes indistinguishable (*Fig. 3 A and B*).

The significance of the bone marrow findings is summarized in *Table 2*. In each of 34 (41 percent) patients, the finding of metastatic cells in the bone marrow was the first evidence of a malignant lesion, in 12 of these it was the only evidence; in 29 (35 percent) other patients, the bone marrow aspirate provided the first evidence of metastasis. In the remaining 20 (24 percent), the bone marrow aspirate provided confirmatory evidence of widespread metastases. Follow-up reports were complete for 67 patients and, of these, 40 (60 percent) were dead within one month of the bone marrow study (*Table 3*).

The cellularity of the aspirates ranged from a hypocellular specimen with few malignant cells (Group I A) to a hypercellular specimen containing ample bone marrow with large metastatic deposits (Group II B) (*Table 4*). The most frequent combination was a large number of metastatic cells among scant normal marrow elements (Group II A). The appearance of the metastatic cells varied widely. The most common pattern consisted of syncytia of pleomorphic cells with indistinct cellular outlines, abundant foamy cytoplasm, and prominent nucleoli. Less frequently the cell contained only scanty cytoplasm. Occasionally the appearance suggested gland formation. In

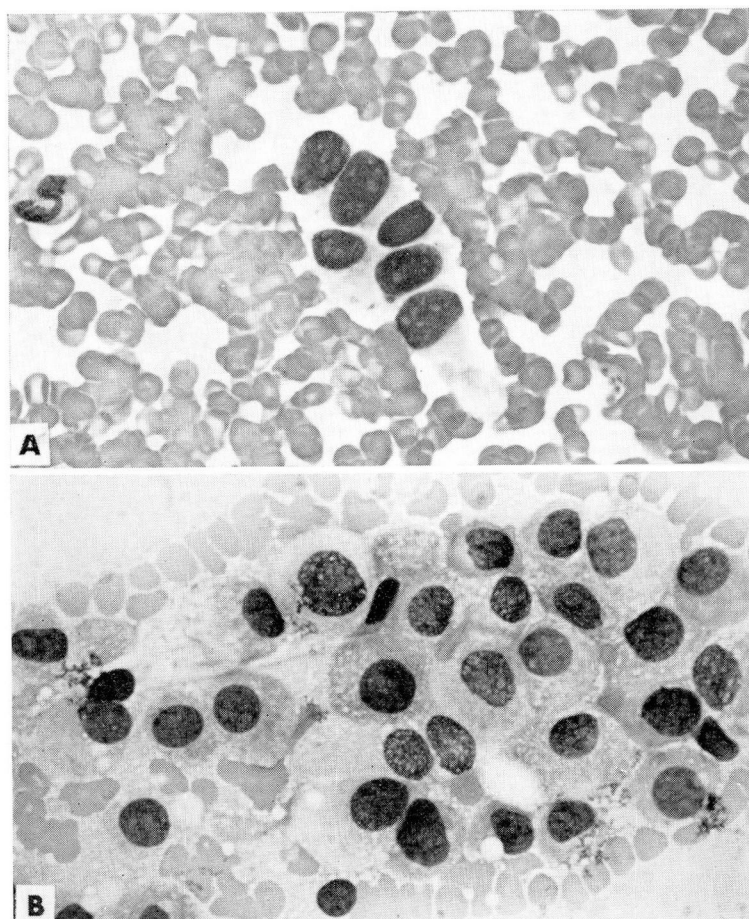


Fig. 2. Metastases from the same organ (breast) with different morphologic appearance. Wright's stain; magnification  $\times 500$ .

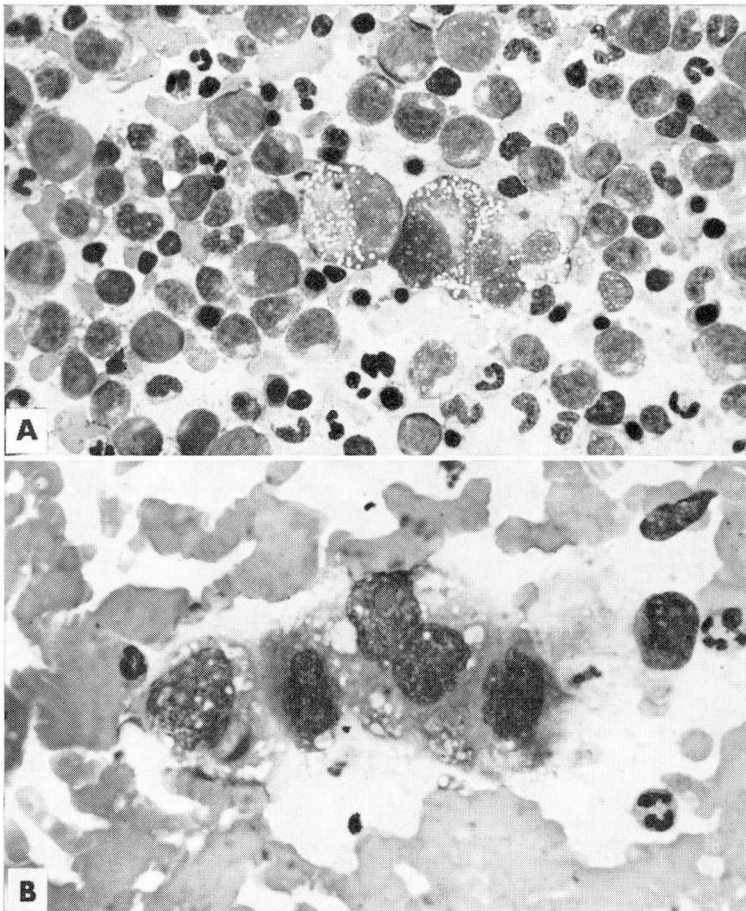
three specimens, the metastatic cells closely resembled atypical plasma cells (Fig. 4). The primary neoplasms were breast and pancreas and in each instance the original tumor contained abundant signet-ring cells.

The peripheral blood findings are summarized in Table 5. In 22 (26 percent) patients these were within normal limits. It is interesting that a normal peripheral blood picture was found in 7 of 10 patients with carcinoma of the lung. Anemia (blood hemoglobin content less than 12 g per 100 ml in men, and less than 10 g per 100 ml in women) was present in 59 patients (71 percent). A leukoerythroblastic blood picture, consisting of the presence of nucleated red blood cells and immature granulocytes was found in 44 patients (53 percent); all but one of these were anemic. A leukemoid reaction of granulocytic type with a white cell count of more than 45,000 per cubic millimeter was seen in four patients (5 percent), and leukopenia



**Table 2.**—Diagnostic value of the finding of metastatic neoplasm in bone marrow aspirates in 83 patients

	Number of patients (percent)
Only evidence of neoplasm before autopsy	12 (13)
First evidence of neoplasm	22 (28)
First evidence of metastasis	29 (35)
Evidence of extent of metastasis	20 (24)

**Fig. 3.** Metastases from different organs with similar morphologic appearance. Wright's stain. A, Renal cell carcinoma; magnification  $\times 500$ . B, Prostate; magnification  $\times 530$ .

with a white cell count less than 3,000 per cubic millimeter in three others (4 percent).

The serum alkaline phosphatase value was increased in 50 of 71 patients in whom it was measured. In more than 80 percent of the patients, an ab-

**Table 3.**—Survival of 67 patients after the demonstration of metastatic cells in bone marrow aspirates

Survival, months	Patients, number
<1	40
1-6	13
7-12	9
13-18	5

**Table 4.**—Relationship between tumor cells and normal marrow elements in 83 bone marrow aspirates (see text for explanation)

Metastatic cells	Normal marrow elements	
	A (Reduced)	B (Normal)
I (Few)	14 (18 percent)	11 (13 percent)
II (Many)	36 (43 percent)	22 (26 percent)

normal peripheral blood picture, an increased serum alkaline phosphatase value, or a combination of both, was found.

A skeletal roentgenographic survey, including the thorax, the lumbar vertebrae, and pelvis was performed in each of the 83 patients, and evidence of metastatic neoplasm was found in 39. Of the eight patients who had normal peripheral blood pictures and normal serum alkaline phosphatase levels, five had roentgenographic evidence of metastatic neoplasm.

### Discussion

In this series of cases, the commonest primary tumors are carcinoma of the breast in women and carcinomas of the prostate and lung in men. These are the same primary tumors that Meyer<sup>3</sup> found most frequently in his survey of metastatic carcinoma in the skeleton. Since these tumors are mainly anaplastic, it was only in the case of melanotic melanoma that the primary site or cell type could be inferred from a study of the bone marrow metastases. The grave prognostic significance of finding metastatic neoplastic cells in a bone marrow aspirate is a reflection of both the anaplastic nature of the neoplasm and its widespread distribution.

There was no common pattern between the proportion of metastatic cells and marrow elements in this group of bone marrow aspirates. In 33 instances, metastatic tumor cells were found in association with normal numbers of normal marrow cells. Detection of the metastatic cells may be

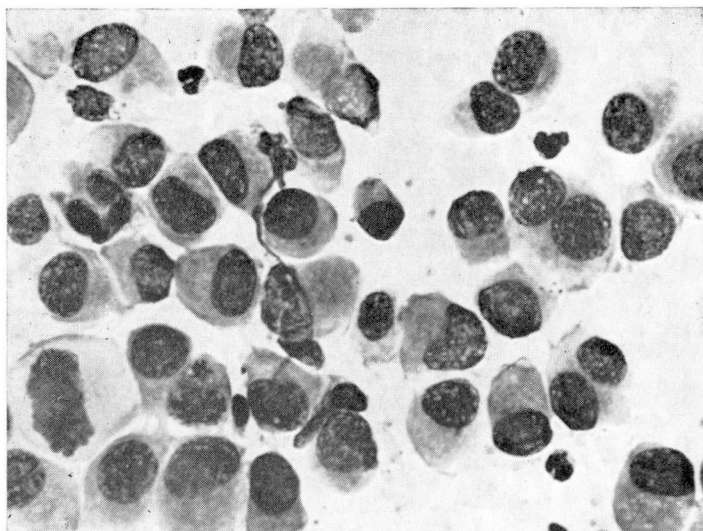


Fig. 4. Metastatic carcinoma with cytologic features resembling plasma cells. Wright's stain; magnification  $\times 500$ .

**Table 5.**—Abnormal peripheral blood findings in 83 patients with metastatic cells in the bone marrow

Abnormal blood finding	Number of patients
Anemia	59 (71 percent)
Leukoerythroblastosis	44 (53 percent)
Leukemoid reaction	4 (5 percent)
Leukopenia	3 (4 percent)

difficult in these circumstances. False-positive diagnoses are seldom a problem when groups of cells are a requisite. Slager and Reilly<sup>4</sup> pointed out that mistakes may occur when diagnosis is based on single cells.

The pleomorphic appearance of the metastatic cells not only makes it difficult to determine their origin, but may lead to confusion with primary neoplasms of the bone marrow. For example, cells from three signet-ring carcinomas (two adenocarcinomas of breast and one adenocarcinoma of pancreas) closely resembled the atypical plasma cells seen in multiple myeloma. The distinction between myeloma and metastatic carcinoma is further complicated by the fact that monoclonal gammopathies have been reported in association with metastatic carcinoma.<sup>5</sup> Furthermore, metastatic carcinoma in the bone marrow has been found to coexist with malignant disorders of plasma cells.<sup>6</sup> The histochemical demonstration of mucin in the metastatic cells may help to make a distinction. Neuroblastoma and acute lymphocytic leukemia may have morphologic similarities and the problem

**Table 6.**—Reported incidences of metastasis to bone marrow in patients known to have malignant neoplasms (lymphomas and leukemias excluded)

	Patients, number	Patients with bone marrow metastasis, percent	Comments
Rohr and Hegglin <sup>1</sup>	74	14	
Kreyberg and Poppe <sup>14</sup>	100	8	1 case of myeloma
Stöger <sup>15</sup>	110	9	
Lanier <sup>16</sup>	32	25	
Rundles and Jonsson <sup>11</sup>	30	57	Carcinoma of prostate
Weisberger and Heinle <sup>17</sup>	50	14	
Jonsson and Rundles <sup>18</sup>	152	46	
Rubinstein and Smelin <sup>9</sup>	100	45	All with late stage carcinoma
Clifton et al. <sup>10</sup>	57	33	Carcinoma of prostate
Hyman and Harvey <sup>8</sup>	650	10	
Pillers et al. <sup>19</sup>	601	6	All with early cancer
Pease <sup>20</sup>	186	18	
Sandberg et al. <sup>21</sup>	600	8	80 (13 percent) had atypical cells
Skelton <sup>7</sup>	225	20	Autopsy materials and tissue sections
Gaffney et al. <sup>13</sup>	31	50	Neuroblastoma
Delta and Pinkel <sup>22</sup>	79	35	Children
Welsh and MacKinney <sup>12</sup>	18	50	Carcinoma of prostate
Stonier and Evans <sup>23</sup>	83	13	
Grann et al. <sup>24</sup>	93	17	
Emerson and Finkel <sup>25</sup>	15	15	
Slager and Reilly <sup>4</sup>	410	10	
Mendoza et al. <sup>26</sup>	807	8	Many with advanced disease
Finklestein et al. <sup>27</sup>	213	28	Children

of distinguishing between each is compounded by the fact that both neoplasms occur most commonly in children.

The wide variation in the reported incidences of metastatic tumor cells in bone marrow aspirates is reflected in *Table 6*. This variation appears to be related to selection of patients, since much higher incidences were found in those patients with proved malignant neoplasms;<sup>7</sup> with the "late stage cancer";<sup>8, 9</sup> and with carcinoma of the prostate<sup>10-12</sup> or neuroblastoma;<sup>13</sup>—neoplasms that have known propensity for osseous metastasis. The indications used for performing a bone marrow aspirate also vary in these published reports. For instance, in some series all patients with a specific tumor were studied, in others only patients with advanced disease were studied. In the series we report here, the indication was most often hematologic, and aspirations were seldom performed for the specific purpose of searching for metastases. Thus, no information concerning the incidence of metastasis can be gained from our study. Selection of patients also accounts for the particularly high proportion of cases in which clinically useful information was obtained.



The commonest indications for performing marrow aspirates in our series of patients were unexplained anemia and a leukoerythroblastic blood picture. These findings, particularly when associated with an increased serum alkaline phosphatase value, are valid indications for performing a bone marrow aspiration. Although bone marrow aspiration is most likely to provide useful information under these circumstances, it is such a simple procedure to perform that it should be considered whenever metastatic neoplasm is suspected. Localized areas of tenderness or roentgenographic changes may indicate the best site for the aspiration.

### Summary

A retrospective study of 83 patients whose bone marrow aspirates contained metastatic cells is presented. The commonest primary neoplasm in men was carcinoma of the prostate or lung, and in women carcinoma of the breast. The prognosis was uniformly extremely poor. With one exception, it was not possible to ascertain the origin of the metastatic cells from a study of their morphology. In three cases, distinction from multiple myeloma was difficult to make. The finding of a leukoerythroblastic anemia and an increased serum alkaline phosphatase value are commonly associated with metastatic cells in the bone marrow.

### References

1. Rohr, K., and Hegglin, R.: Tumorzellen im Sternalpunktat Metastasennachweis Maligner Geschwülste im Knochenmark. *Deutsches Arch. f. klin. Med.* **179**: 61-79, 1936.
2. Battle, J. D., Jr., and Stasney, J.: Malignant melanoma cells in the bone marrow. *Arch. Path.* **31**: 631-633, 1941.
3. Meyer, P. C.: A statistical and histological survey of metastatic carcinoma in the skeleton. *Brit. J. Cancer* **11**: 509-518, 1957.
4. Slager, U. T., and Reilly, E. B.: Value of examining bone marrow in diagnosing malignancy. *Cancer* **20**: 1215-1220, 1967.
5. Hosley, H. F.: M-proteins, plasmacytosis and cancer. *Cancer* **20**: 295-307, 1967.
6. Weitzel, R. A.: Carcinoma coexistent with malignant disorders of plasma cells. *Cancer* **11**: 546-549, 1958.
7. Skelton, M. O.: The incidence found at necropsy of metastases to the sternum and iliac crest, with special reference to carcinoma of the lung. *J. Clin. Path.* **12**: 70-72, 1959.
8. Hyman, G. A., and Harvey, J. L.: A comparison of bone marrow aspiration and skeletal roentgenograms in the diagnosis of metastatic carcinoma. *Cancer* **8**: 576-581, 1955.
9. Rubinstein, M. A., and Smelin, A.: Neoplastic cells in bone marrow aspiration. *Acta Haemat.* **5**: 292-302, 1951.
10. Clifton, J. A., and others: Bone marrow and carcinoma of the prostate. *Amer. J. Med. Sci.* **224**: 121-130, 1952.
11. Rundles, R. W., and Jonsson, U.: Metastases in bone marrow and myelophthisic anemia from carcinoma of the prostate. *Amer. J. Med. Sci.* **218**: 241-250, 1949.
12. Welsh, J. F., and MacKinney, C. C.: Experiences with aspiration biopsies of the bone marrow in the diagnosis and prognosis of carcinoma of the prostate gland. *Amer. J. Clin. Path.* **41**: 509-512, 1964.

13. Gaffney, P. C.; Hansman, C. F., and Fetterman, G. H.: Experience with smears of aspirates from bone marrow in the diagnosis of neuroblastoma. *Amer. J. Clin. Path.* 30: 213-221, 1959.
14. Kreyberg, L., and Poppe, E.: Tumor cells in sternal bone-marrow. *Lancet* 1: 593-595, 1940.
15. Stöger, R.: Das Sternalpunktat beim malignen Neoplasma. *Deutsche Med. Wchnschr.* 67: 1389-1392, 1941.
16. Lanier, P. F.: Sternal marrow in patients with metastatic cancer. *A.M.A. Arch. Intern. Med.* 84: 891-906, 1949.
17. Weisberger, A. S., and Heinle, R. W.: Study of fixed tissue section of sternal bone marrow obtained by needle aspiration. III. Metastatic carcinoma in sternal bone marrow. *Amer. J. Med. Sci.* 217: 263-268, 1949.
18. Jonsson, U., and Rundles, R. W.: Tumor metastases in bone marrow. *Blood* 6: 16-25, 1951.
19. Pillers, E. M.; Marks, J., and Mitchell, J. S.: The bone marrow in malignant disease. *Brit. J. Cancer* 10: 458-471, 1956.
20. Pease, G. L.: Diagnostic value of bone marrow aspiration. *Med. Clin. N. Amer.* 40: 1225-1244, 1956.
21. Sandberg, A. A., and others: The frequency of tumor cells in the bone marrow and blood. *Cancer* 11: 1180-1186, 1958.
22. Delta, B. G., and Pinkel, D.: Bone marrow aspiration in children with malignant tumors. *J. Pediat.* 64: 543-546, 1964.
23. Stonier, P. F., and Evans, P. V.: Carcinoma cells in bone marrow aspirates. *Amer. J. Clin. Path.* 45: 722-727, 1966.
24. Grann, V.; Pool, J. L., and Mayer, K.: Comparative study of bone marrow aspiration and biopsy in patients with neoplastic disease. *Cancer* 19: 1898-1900, 1966.
25. Emerson, C. P., and Finkel, H. E.: Problem of tumor cell identification in the bone marrow. *Cancer* 19: 1527-1533, 1966.
26. Mendoza, C. B., Jr., and others: Prognostic significance of tumor cells in the bone marrow. *Surg. Gynec. Obstet.* 129: 483-488, 1969.
27. Finklestein, J. Z., and others: Bone marrow metastasis in children with solid tumors. *Amer. J. Dis. Child.* 119: 49-52, 1970.