

Polycythemia secondary to pheochromocytoma

Report of a case

JOHN D. BATTLE, JR., M.D.
Department of Hematology

RALPH J. ALFIDI, M.D.
Division of Radiology

RALPH A. STRAFFON, M.D.
Department of Urology

POLYCYTHEMIA is uncommon in patients with pheochromocytoma. Waldmann and Bradley¹ reported the case of a 10-year-old boy with profound polycythemia that was corrected by surgical extirpation of bilateral pheochromocytoma. The patient also had associated hypertension and increased urinary excretion of catecholamine. Erythropoietic-stimulating factor was demonstrated in the tumor.

Our report concerns a normotensive woman with polycythemia, in whom an unsuspected pheochromocytoma was discovered by means of arteriography. After surgical removal of the tumor, polycythemia regressed.

Report of a case

A 41-year-old woman was admitted to a hospital on December 29, 1968, because of gastrointestinal upset. At that time, she had a ruddy complexion; the blood hemoglobin value was 19.6 g per 100 ml, and the hematocrit 65 percent. She was not cyanotic. The leukocyte count was 4200 per cubic millimeter, with normal differential count; the platelet count was 365,000 per cubic millimeter. The reticulocyte count was 1 percent. The patient had no symptoms of bath pruritis or shortness of breath. The spleen was not palpable. A pelvic examination disclosed evidence suggestive of uterine fibroids. After several venesections hysterectomy was performed on January 17, 1969. The uterus weighed 170 g, and contained several small fibroids. The possibility of familial erythrocytosis was excluded by examinations of the siblings and other members of the family. In April 1969 the patient was referred to the Cleveland Clinic because of polycythemia of unknown etiology. The blood pressure was 135/76 mm Hg, and the pulse rate 80 and regular. The skin and mucous membranes revealed mild plethora but no cyanosis. The liver and spleen were not palpably enlarged. The other results of the physical examination were normal.

Results of laboratory studies were: blood hemoglobin, 17.6 g per 100 ml; the erythrocyte count, 7,000,000 per cubic millimeter; 0.4 percent reticulocytes. The cell volume was 57 ml per 100 ml, MCV 82 cubic microns, MCH 25 micromicrograms, and the MCHC 31 percent. The leukocyte count was 6400 per cubic millimeter, with 57 percent segmented neutrophils, 2 percent basophils, 36 percent lymphocytes, and 5 percent monocytes. The platelet count was 280,000 per cubic millimeter. The blood volume according to the radioiodinated serum albumin method disclosed an erythrocyte mass of 38 ml per kilogram of body weight, and a plasma volume of 32 ml per kilogram of body weight. The leukocyte alkaline phosphatase score was 30 (normal range, 7 to 100). Creatinine clearance and other measured values of renal function were normal. The serum values for cholesterol, calcium, inorganic phosphate, bilirubin, amylase, globulin, alkaline phosphatase, glutamic oxalacetic transami-

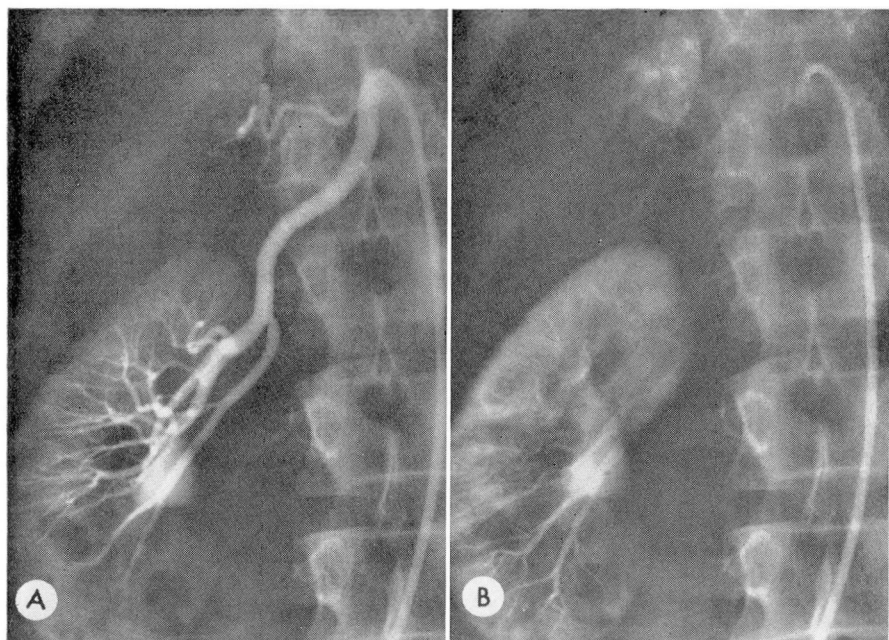


Fig. 1. Arteriograms: A, arterial phase, showing selective injection of the right renal artery and an enlarged inferior adrenal artery partially opacified. B, Late arterial phase, showing a vascular neoplasm in the region of the right adrenal gland.

nase, uric acid, urea nitrogen, lactic acid dehydrogenase, and glucose, were normal. The hemoglobin A₂ was 3.6 percent, which is within the normal range. Results of pulmonary function studies were entirely normal. The oxyhemoglobin dissociation curve also was normal.

Roentgenograms of the chest were normal. An intravenous urogram, performed in January 1969, was reviewed and thought to show inadequate demonstration of the inferior pole of the left kidney. Selective renal arteriograms showed that the left kidney was normal. Much to our surprise, a vascular right suprarenal tumor was demonstrated (*Fig. 1A and B*). No elevation of blood pressure occurred during arteriography. Bilateral adrenal phlebograms also disclosed changes indicative of right adrenal tumor (*Fig. 2*). On June 26, 1969, surgical exploration was performed and a mass in the upper portion of the right adrenal gland was found. The left adrenal gland was normal. The adrenal tumor was removed; it was 6 by 2 by 2 cm and weighed 12.5 g. Microscopic study disclosed changes indicative of benign pheochromocytoma with extensive sclerosis. Postoperatively, the patient required no specific treatment, but blood counts performed in September and November 1969 revealed mild anemia. The hemoglobin was 11.6 g, erythrocyte count 4,500,000 per cubic millimeter, and hematocrit 36 percent. The leukocyte and platelet counts remained normal. Serum iron was 27 μ g per 100 ml, and the iron-binding capacity was 492 μ g per 100 ml. The patient was advised to take oral iron therapy for a period of several months. In June 1970, one year after removal of the pheochromocytoma, results of hematologic examination were normal. The blood pressure was 124/74 mm Hg, the hemoglobin 14.2 g per 100 ml; hematocrit was 44 percent; leukocyte count 7500 per cubic millimeter with a normal differential count. The platelet count was normal. Assay of the tumor for erythropoietic-stimulating factor* was technically unsatisfactory because the specimen had become defrosted in transit.

* We wish to acknowledge the cooperation of J. W. Fisher, M.D., Tulane University, New Orleans, Louisiana.

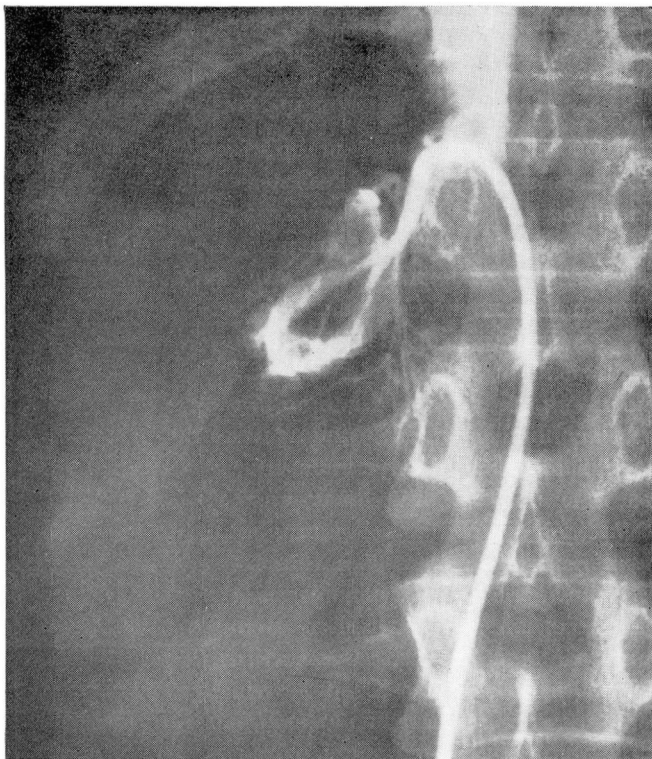


Fig. 2. Right adrenal phlebogram showing enlarged veins in the region of the previously demonstrated adrenal tumor.

Discussion

Polycythemia due to benign and malignant tumors has been recognized with increased frequency in the last 15 years. The term erythrocythemia has been suggested because only the erythrocytic elements are increased. There is no hypoxia to explain the increase of red cell mass, but rather a number of cases have been reported of an associated erythropoietic-stimulating factor in these tumors. These have included renal carcinoma, fluid from renal cysts, and cystic cerebellar hemangioblastomas. Surgical removal of the tumor has permanently corrected the erythrocythemia.

The occurrence of polycythemia with pheochromocytoma is uncommon. Waldmann² reported the cases of two patients with polycythemia in a series of 15 with pheochromocytoma in whom blood volume studies were performed. Eleven patients with pheochromocytoma were studied at the Cleveland Clinic and none had a significant increase of erythrocyte mass. All had hypertension and increased urinary excretion of catecholamine.³

Alfidi, Gill, and Klein⁴ recently reported that adrenal arteriography is quite accurate in demonstrating adrenal neoplasms. Pheochromocytomata have

proved to be highly vascular tumors that are dramatically shown by arteriography. The possible dangers associated with arteriography performed in patients with pheochromocytoma have been overcome by continuous blood pressure monitoring and the availability of phentolamine for immediate intravenous injection. Rossi, Young, and Pankey⁵ successfully used phenoxybenzamine hydrochloride to avert possible adverse blood pressure responses in patients with pheochromocytoma. However, in unsuspected cases of pheochromocytoma, the use of phenoxybenzamine chloride probably would not be useful to control possible elevations of blood pressure, as several days' preparation is necessary.

Summary

A 41-year-old woman with an increase of red cell mass and normal blood pressure by means of arteriography was found to have a benign pheochromocytoma. Surgical removal of the 12-g adrenal tumor corrected the polycythemia.

References

1. Waldmann, T. A., and Bradley, J. E.: Polycythemia secondary to a pheochromocytoma with production of erythropoiesis stimulating factor by the tumor. *Proc. Soc. Exp. Biol. Med.* **108**: 425-427, 1961.
2. Clinical Staff Conference. Pheochromocytoma: current concepts of diagnosis and treatment. Combined Clinical Staff Conference at the National Institutes of Health. *Ann. Intern. Med.* **65**: 1302-1326, 1966.
3. Tarazi, R. C.: Personal communication, June 27, 1969.
4. Alfidi, R. J.; Gill, W. M., Jr., and Klein, H. J.: Arteriography of adrenal neoplasms. *Amer. J. Roentgen.* **106**: 635-641, 1969.
5. Rossi, P.; Young, I. S., and Pankey, W. F.: Techniques, usefulness, and hazards of arteriography of pheochromocytoma. Review of 99 cases. *J. A. M. A.* **205**: 547-553, 1968.