

Behçet's syndrome, Crohn's disease and toxic megacolon

Seid Hossein Mir-Madjlessi,
M.D.

Richard G. Farmer, M.D.
Department of Gastroenterology

Behçet's syndrome is characterized by a triad of symptoms: recurrent oral and genital ulcerations, and ocular inflammation. Since the first report by Behçet in 1937¹ similar cases have been described, and it is now acknowledged that this disorder has a wide spectrum of clinical manifestations.²⁻⁴

The gastrointestinal involvement in this disease was first described by Bechgaard⁵ in 1940, and since then several reports have been published.⁶⁻⁹ The literature on Behçet's disease has been extensively reviewed.¹⁰⁻¹³

This report describes a case of Behçet's disease associated with Crohn's disease of the colon and terminal ileum complicated by toxic megacolon. To our knowledge such a combination has not been described previously.

Case report*

A 15-year-old Caucasian girl was first seen at the Cleveland Clinic in 1950, when a diagnosis of grand mal and petit mal epilepsy was made. She was treated with diphenylhydantoin and phenobarbital; on this regimen she had fewer than seven seizures a year. On several occasions she complained of severe pain in the hips, legs, and ankles. By 1959 the electroencephalogram had returned to an almost normal pattern. However, the number of seizures increased in November 1963 and the patient complained of fever, malaise, and diffuse skeletal aching.

* *This patient's clinical course until 1965 has been reported by O'Duffy et al¹⁴ (case 1 in their series).*

In June 1964 she noticed some clumsiness of her movements. Physical examination revealed mild slurring of speech, coarse horizontal nystagmus greater to the right, mild vertical nystagmus, truncal ataxia, dysmetria of the upper extremities, and positive Romberg test. She had synovitis, and limited movement of elbows, ankles, knees, and wrists. Roentgenograms of chest, skull, and right elbow were negative. A few days later erythema nodosum appeared on her shins. Blood counts were normal, LE and latex fixation test were negative. Erythrocyte sedimentation rate was 1.3 mm/min (normal less than 0.65); C-reactive protein 2+; glycoprotein 211-225 mg/100 ml (150 upper limit of normal); serum polysaccharide 204 μ g/100 ml (normal 80-150); serum protein electrophoresis showed albumin 3.17 g/100 ml; alpha-1 globulin, 0.45 g/100 ml; alpha-2 globulin, 1.02 g/100 ml; beta globulin,

1.09 g/100 ml; gamma globulin 1.57 g/100 ml. Blood and urine cultures were negative. A trial of 20 mg of prednisone per day resulted in definite improvement of her joints, and the shin lesions cleared. For the first time she complained of nausea and loose stools.

The patient's neurological condition continued to deteriorate and she was confined to a wheelchair. A change in personality was noted. The spinal fluid was normal; colloidal gold and serology tests were negative. A biopsy of the right vastus lateralis muscle was normal. The Kveim test was negative. A tentative diagnosis of "connective tissue disorder" was made and ACTH (40 units IV per day for 36 days and 20 units IM per day for 7 days) and nitrogen mustard (total of 24 mg) were given. Erythema nodosum recurred in October 1964. In December 1964 large, painful oral aphthous ulcerations with central yellow necrotic base and erythematous rim were observed. The patient stated these had been recurring for 10 years, but she had not noticed ocular or vulvar lesions, although significant redness and irritation of the vulvar area were observed on examination.

In February 1965 she complained of daily chills, fever up to 103F, arthralgias, and one to two loose bowel movements. The oral lesions had healed, and her speech was somewhat improved; cerebellar signs persisted. In March 1965 left ileofemoral thrombophlebitis was diagnosed. Improvement followed the administration of heparin.

Meanwhile, diarrhea had increased with no evidence of rectal bleeding; she had crampy abdominal pain and had lost weight. Multiple oral aphthous ulcerations, a distended and tender abdomen, and perianal tenderness and swelling were found on examination. A proctosigmoidoscopic examination was normal. Barium enema, normal in 1964, now showed evidence of Crohn's disease of descending and transverse colon with nodular, distorted mucosal pattern (*Fig. 1*). Barium was seen in the vagina, but a definite

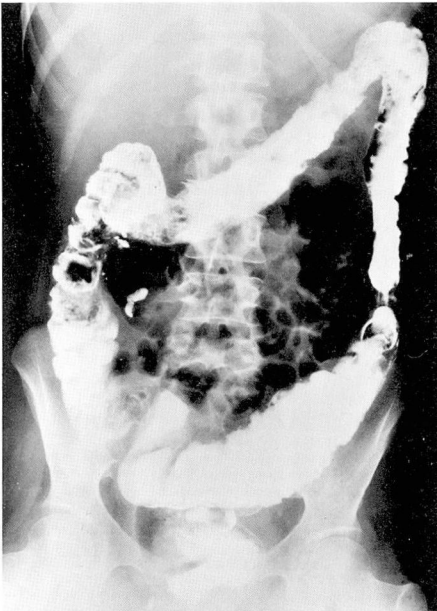

Fig. 1. Roentgenogram of the colon after barium enema, March 1965. Loss of haustral markings; ulceration; asymmetrical but diffuse involvement characteristic of transmural (Crohn's) colitis. Note "whiskering" ulceration of transverse colon and narrow distal descending colon.

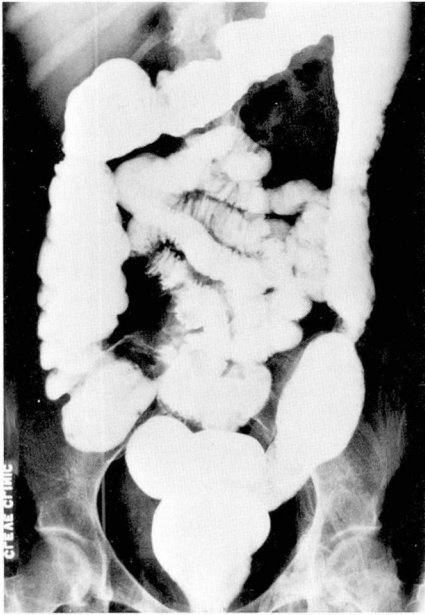

Fig. 2. Roentgenogram of the colon after barium enema, July 1968. Residual ulceration in descending colon but improvement from previous study. Note lack of shortening of colon.

fistulous tract could not be identified. A small bowel series showed normal jejunum and proximal ileum, with some abnormality of the distal ileum.

In March 1966 vulvar ulcerations, recurrent oral ulcerations, diarrhea, and intermittent abdominal pain developed. The vulvar ulcerations recurred several times thereafter. Diarrhea decreased after treatment with salicylazosulfapyridine (Azulfidine).

In July 1968 the patient complained of retrobulbar ocular pain, especially of the left eye; painful knees, and some abdominal cramps. She had three semisolid stools a day. Proctoscopic examination showed thickening, edema, and friability of the anal canal suggestive of Crohn's disease; the rectum appeared normal. Barium enema showed "cobble-stoning" and ulcerated mucosa (*Fig. 2*). A reflux of barium into the vagina was noted again without demonstration of the fistulous tract. Re-

sults of ophthalmologic examination were normal.

From 1964 until 1968 the patient was treated with 20 units of ACTH two to three times a week, plus symptomatic treatment of diarrhea and prophylaxis for epilepsy. The ACTH was discontinued in late 1968.

In August 1971 the patient was admitted to Cleveland Clinic Hospital with severe diarrhea, abdominal pain, fever, and rapid deterioration of her general condition. No rectal bleeding was observed.

On physical examination temperature was 102F; pulse, 116/min; and blood pressure, 120/64 mm Hg. The patient appeared "toxic" with dry skin and mucous membranes, hypoactive bowel sounds and rebound abdominal tenderness. There was brawny pitting edema of legs. The anal canal was thickened and edematous. A plain film of the abdomen showed dilatation of the transverse and descending colon, and paralytic ileus of the small bowel (*Fig. 3*). Hemoglobin was 12.6 g/100

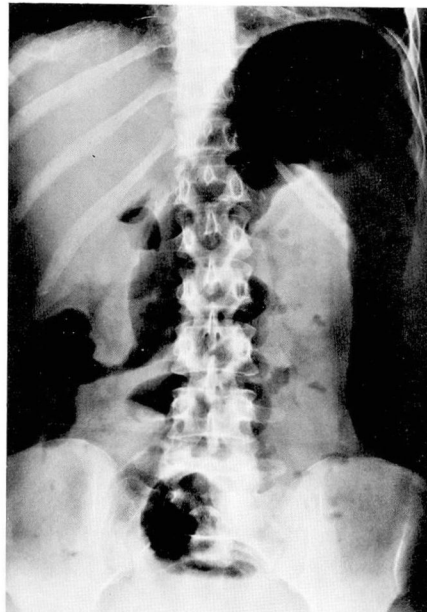


Fig. 3. Roentgenogram of abdomen, August 1971. Toxic megacolon, with dilatation of colon maximal in splenic flexure.

ml; hematocrit reading, 39%; white cell count, 8500 with 12% segmented neutrophils, 78% nonsegmented neutrophils, 6% lymphocytes, and 4% monocytes. Serum cholesterol was 115 mg/100 ml; serum calcium, 8.2 mg/100 ml; serum albumin, 2.4 g/100 ml; total protein, 5.8 g/100 ml; with normal serum phosphorus, total bilirubin, uric acid, blood urea nitrogen, creatinine, LDH, SGOT, and alkaline phosphatase. Stool and urine cultures were negative. Serum immunoglobulins showed IgG, 950 mg/100 ml; IgA, 280 mg/100 ml; and IgM, 220 mg/100 ml. Coombs' test was negative. After 3 days of conservative treatment, she underwent operation on August 23, 1971. Proctosigmoidoscopy performed under general anesthesia revealed "cobble-stoning" and ulceration of the mucosa and narrowing of the lumen in the rectosigmoid region. Operation consisted of "blow hole" colostomy in the

left transverse colon and loop ileostomy. The colon was dilated maximally at the splenic flexure. Typical features of Crohn's disease of the colon and terminal ileum were observed with serositis, submucosal edema, and irregular ulceration of the mucosa. The postoperative course was uneventful. The patient underwent subtotal colectomy on February 3, 1972. Pathological examination confirmed the diagnosis of transmural colitis, nongranulomatous type, involving the ascending and transverse colon and appendix.

Discussion

The diagnosis of Behçet's disease in this case was based upon the presence of recurrent oral and genital ulcerations, polyarthritis, erythema nodosum, ileofemoral thrombophlebitis and central nervous system lesions (*Table 1*). Whether the epileptic seizures were part of this disease or an independent entity is not known. Although skin rash, erythema nodosum,¹⁴ arthritis,¹⁵ and phlebitis¹⁶ have been reported in Crohn's disease, the typical oral and genital lesions, and especially the cerebellar and brain stem manifestations are characteristic of Behçet's disease. Whether some of those lesions were related to the bowel disease is difficult to determine.

This case also demonstrates long survival of a patient affected by "neuro-Behçet"¹⁷ and its relationship to inflammatory bowel disease.

Bøe et al⁷ reviewed the intestinal involvement in mucocutaneous syndromes which included Behçet's disease. In two of their four patients the main lesions were in the colon and were associated with a clinical picture of ulcerative colitis. Dowling,¹¹ in a review of 124 reported cases of Behçet's disease from 1906 to 1959 reported a 3% incidence of diarrhea. Oshima et

Table 1.—Summary of clinical course

Age	Clinical features
Early teens	Frontal headaches
15 yr.	Grand mal and petit mal
17 yr.	Severe pain in hips, legs, and ankles, without arthritis; poor memory; difficulty in concentration
19 yr.	Recurrent oral ulcerations
28 yr.	Fever, diffuse skeletal pain
29 yr.	Cerebellar involvement; erythema nodosum; polyarthritis; loose stools
30 yr.	Left ileo-femoral thrombophlebitis; diagnosis of Crohn's disease of the colon and terminal ileum; rectovaginal fistula
30 yr.	Vulvar ulcerations
33 yr.	Ocular pain without positive objective signs; improvement of cerebellar disorders
36 yr.	Toxic megacolon secondary to Crohn's disease

al,³ reporting on 85 cases of "complete and incomplete" Behçet's disease, found a 40% incidence of gastrointestinal symptoms but no evidence of intestinal hemorrhage. Radiological examination revealed various nonspecific abnormalities, mainly in the small intestine. Ramsay⁸ reported the case of a 16-year-old boy with Behçet's disease in whom bloody diarrhea developed. Proctosigmoidoscopy showed acute ulcerative colitis. The patient responded favorably to prednisone and sulphasalazine. Mention was made of a case described by Tsakada et al¹⁸ of "neuro-Behçet" with perforating ulcer of the ileum and ileocecal region, and a patient discussed by Curth had rectal ulcers and multiple colonic perforations. Menkes et al⁹ described the case of a 37-year-old man with Behçet's disease and chronic ulcerative colitis. O'Duffy et al⁴ also found three cases of inflammatory bowel diseases, including this case, in a series of 10 cases of Behçet's disease.

A review of the literature suggests that Behçet's disease may be associated with either mucosal^{4, 7-9} or transmural colitis.⁵ The clinical and radiological features and the appearance of the bowel at operation in our case are typical of Crohn's transmural disease of the colon and terminal ileum. The interesting feature, however, is the appearance of toxic megacolon as evidenced by severe systemic toxicity and dilatation of the colon. Although toxic megacolon has been considered a feature of chronic ulcerative colitis, but not reported in association with Crohn's disease as late as 1966,¹⁹ several cases of toxic megacolon complicating transmural colitis have been described recently.²⁰⁻²⁹

The etiology of Behçet's disease has

been reviewed extensively.^{10, 30, 31} Viral etiology has been suggested³²⁻³⁴ and refuted.^{30, 35, 36} There is little evidence to support a vascular or allergic basis. At present an auto-immune basis for Behçet's disease is the most commonly accepted theory.

Oshima et al,³ Shimizu et al,³¹ and Lehner³⁷ showed various oral mucosal antibodies in Behçet's disease. Of particular interest is the fact that these antibodies are not organ-specific for fetal oral mucosa, but cross-react with fetal skin and colonic mucosa. This cross-reactivity suggests the possibility of a common pathogenesis of the intestinal and cutaneous manifestations of Behçet's disease. Despite increasing interest, there is no definite proof that humoral or cellular immune mechanisms play a role in the pathogenesis of Crohn's disease.³⁸ Although a negative response to the Kveim antigen has been reported in Crohn's disease,³⁹ Mitchell et al⁴⁰ found 51% positive tests in 74 patients with definite or probable Crohn's disease. Furthermore, Mitchell et al⁴¹ presented evidence of a transmissible agent in tissue from human Crohn's disease. In the patient reported here the Kveim test was negative.

It is possible that intestinal lesions observed in Behçet's disease represent instances of coexistence of two separate diseases. However they may indicate the reaction of the intestinal tract to the causative factor(s) of Behçet's disease. An elucidation of the etiology of Behçet's disease might contribute to our knowledge of etiopathogenesis of inflammatory bowel disease.

This patient's humoral and cellular immune system seemed to be intact. Serum immunoglobulins were normal or elevated. The significance of ele-

vated IgA and IgM in this case is not clear. Such elevations have been observed in chronic ulcerative colitis.⁴² Menkes et al⁹ reported an equivocal result of the lymphocyte transformation test to phytohemagglutinin. In this patient it was normal.

The treatment of Behçet's disease remains unsatisfactory as does the treatment of Crohn's disease. ACTH and corticosteroids¹⁰ are given for both conditions. Chaouat et al⁴³ reported beneficial effects of long-term, low dose cyclophosphamide in two patients with Behçet's disease. Antimetabolites or alkylating agents also have been used in the treatment of Crohn's disease.⁴⁴ Surgical treatment of toxic megacolon has been recently discussed by Turnbull et al.⁴⁵ This patient was treated with nitrogen mustard and ACTH with significant improvement in neurologic symptoms; decompression ileostomy and colostomy were required for treatment of toxic megacolon.

Summary

The clinical course of a patient with the classic features of Behçet's disease, transmural (Crohn's) colitis complicated by toxic megacolon is described. Their possible relationship is discussed, with emphasis on the various facets of etiology and treatment.

References

- Behçet H: Über rezidivierende, aphthöse durch ein Virus Verursachte Geschwüre am Mund, am Auge und an den Genitalien. *Dermatol Wschr* **105**: 1152-1157, 1937.
- Strachan RW, Wigzell FW: Polyarthritits in Behçet's multiple symptom complex. *Ann Rheum Dis* **22**: 26-35, 1963.
- Oshima Y, Shimizu T, Yokohari R, et al: Clinical studies on Behçet's syndrome. *Ann Rheum Dis* **22**: 36-45, 1963.
- O'Duffy JD, Carney JA, Deodhar SD: Behçet's disease: report of 10 cases, 3 with new manifestations. *Ann Intern Med* **75**: 561-570, 1971.
- Bechgaard P: Et tilfælde af recidiverende aphtøs stomatitis ledsaget af conjunctivitis og ulcerationer paa genitalia og hud. *Ugeskr Laeger* **102**: 1019-1023, 1940, cited by Bøe et al.
- Jensen T: (a) Recidiverende aphtøse ulcerationer paa mundslimhinden og genitalia. *Ugeskr Laeger* **102**: 1023-1030, 1940 (b) Sur les ulcérations aphteuses de la muqueuse de la bouche et de la peau génitale combinées avec les symptômes oculaires. *Acta Derm Venereol* **22**: 64-79, 1941, cited by Bøe et al.
- Bøe J, Dalgaard JB, Scott D: Muco-cutaneous-ocular syndrome with intestinal involvement. *Am J Med* **25**: 857-867, 1958.
- Ramsay CA: Behçet's syndrome with large bowel involvement. *Proc R Soc Med* **60**: 185-187, 1967.
- Menkès CJ, Méry C, de Saint-Maur P, et al: Syndrome de Behçet et recto-colite hémorragique. *Rev Rhum* **37**: 489-852, 1970.
- Francis C: Recurrent aphthous stomatitis and Behçet's disease; a review. *Oral Surg* **30**: 476-486, 1970.
- Dowling GB: Behçet's disease. *Proc R Soc Med* **54**: 101-104, 1961.
- Mamo JG, Baghdassarian A: Behçet's disease; a report of 28 cases. *Arch Ophthalmol* **71**: 4-14, 1964.
- France R, Buchanan, RN, Wilson MW, et al: Relapsing iritis with recurrent ulcers of mouth and genitalia (Behçet's syndrome). *Medicine (Baltimore)* **30**: 335-355, 1951.
- McCallum DI, Kinmont PD: Dermatological manifestations of Crohn's disease. *Br J Dermatol* **80**: 1-8, 1968.
- Ford DK, Vallis DG: The clinical course of arthritis associated with ulcerative colitis and regional ileitis. *Arthritis Rheum* **2**: 526-536, 1959.
- Chapin LE, Scudamore HH, Baggenstoss AH, et al: Regional enteritis: associated visceral changes. *Gastroenterology* **30**: 404-415, 1956.
- Schotland DL, Wolf SM, White HH, et al: Neurologic aspects of Behçet's disease. Case report and review of the literature. *Am J Med* **34**: 544-553, 1963.

18. Tsakada S, Yamazaki T, Iyo S, et al: The newest medicine (Japan). *19*: 1533, 1964, cited by Ramsay.
19. Marshak RH, Linder AE, Janowitz HD: Granulomatous ileocolitis. *Gut* **7**: 258-264, 1966.
20. Hawk WA, Turnbull RB Jr: Primary ulcerative disease of the colon. *Gastroenterology* **51**, 802-805, 1966.
21. Farmer RG, Hawk WA, Turnbull RB Jr: Regional enteritis of the colon: a clinical and pathological comparison with ulcerative colitis. *Am J Dig Dis* **13**: 501-514, 1968.
22. Hawk WA, Farmer RG, Turnbull RB Jr: Toxic dilatation (megacolon) in transmural colitis (regional colitis, Crohn's disease of the colon) p. 991 *In*, *Modern Gastroenterology, Verhandlungsbericht. Proceedings. Communications. Edited by O Gregor and O Riedl, Stuttgart, New York: Shattauer, 1969.*
23. Schachter H, Goldstein MJ, Kirsner JB: Toxic dilation complicating Crohn's disease of the colon. *Gastroenterology* **53**: 136-142, 1967.
24. McGovern VJ, Goulston SJ: Crohn's disease of the colon. *Gut* **9**: 164-176, 1968.
25. Papp JP, Pollard HM: Toxic dilatation of the colon in granulomatous colitis: report of two cases. *Am J Dig Dis* **15**: 1105-1113, 1970.
26. Javett SL, Brooke BN: Acute dilatation of colon in Crohn's disease. *Lancet* **2**: 126-128, 1970.
27. Leoutsakos B, Pedridis G: Toxic megacolon complicating Crohn's disease of the colon. *Am J Proctol* **21**: 258-262, 1970.
28. Foley WJ, Weaver DK, Coon WW: Toxic megacolon and granulomatous colitis: report of two cases. *Am Surg* **37**: 67-72, 1971.
29. Soll EL, Ferrante WA, Gathright JB Jr: Toxic dilatation of the colon due to granulomatous colitis (Crohn's disease). *South Med J* **64**: 349-353, 1971.
30. Dudgeon JA: Virological aspects of Behçet's disease. *Proc R Soc Med* **54**: 104-106, 1961.
31. Shimizu T, Katsuta Y, Oshima Y: Immunological studies on Behçet's syndrome. *Ann Rheum Dis* **24**: 494-500, 1965.
32. Sezer FN: The isolation of a virus as the cause of Behçet's disease. *Am J Ophthal* **6**: 301-315, 1953.
33. Evans AD, Pallis CA, Spillane JD: Involvement of the nervous system in Behçet's syndrome; report of three cases and isolation of a virus. *Lancet* **2**: 349-353, 1957.
34. Nakagama Y, Shingu M: Studies on the pathogenic agents of Behçet's disease; the isolation of Behçet's disease virus on the chorioallantois of developing chick embryos. *J Jap Assoc Infect Dis* **32**: 270-276, 1958, cited by Francis.
35. Curth HO: Recurrent genito-oral aphthosis and uveitis with hypopyon (Behçet's syndrome); report of 2 cases. *Arch Dermatol* **54**: 179-196, 1946.
36. Breslin HJ: Behçet's disease; report of a case history of seventeen years' duration. *Am J Ophthal* **53**: 132-136, 1962.
37. Lehner T: Behçet's syndrome and autoimmunity. *Br Med J* **1**: 465-467, 1967.
38. Law DH: Regional enteritis. *Gastroenterology* **56**: 1086-1110, 1969.
39. Williams WJ: The laboratory diagnosis of Crohn's syndrome. *Proc R Soc Med* **56**: 490, 1963.
40. Mitchell DN, Cannon P, Dyer NH, et al: Further observations on Kveim test in Crohn's disease. *Lancet* **2**: 496-498, 1970.
41. Mitchell DN, Rees RJ: Agent transmissible from Crohn's disease tissue. *Lancet* **2**: 168-171, 1970.
42. Deodhar SD, Michener WM, Farmer RG: A study of the immunologic aspects of chronic ulcerative colitis and transmural colitis. *Am J Clin Pathol* **51**: 591-597, 1969.
43. Chaouat Y, Paquet J, Pélisson J, et al: Le cyclophosphamide au long cours a petites doses dans le traitement des rhumatismes inflammatoires Graves. *Rev Rhum* **35**: 649-656, 1968.
44. Winkelman EI, Brown CH: Nitrogen mustard in the treatment of chronic ulcerative colitis and regional enteritis. *Cleve Clin Q* **32**: 165-174, 1965.
45. Turnbull RB Jr, Weakley FL, Hawk WA, et al: Choice of operation for the toxic megacolon phase of non-specific ulcerative colitis. *Surg Clin North Am* **50**: 1151-1169, 1970.