

Splenectomy for hematologic disease in children

Robert E. Hermann, M.D.
Luis Burbano, M.D.*

Department of General Surgery

Splenectomy for the treatment of hematologic disorders in adult patients is frequently performed with relative assurance of success, depending on the hematologic disease.¹⁻³ In children with hematologic disease, however, splenectomy is often undertaken with much more concern. There are several reasons why removal of the spleen in a child may be associated with greater morbidity. (1) The risk of any major surgical operation in a child may be greater than the risk of the same procedure in an adult. (2) In the young child or infant, loss of the spleen may weaken the immunologic defense of the body to infection. (3) The long-term effects of splenectomy on host resistance and bodily defense to other noninfectious processes, such as malignancies or collagen disorders, are not known. (4) Less is known about the response of hematologic disorders to splenectomy in children, as compared to adults. Fewer follow-up studies have been conducted on the results of splenectomy for hematologic disease in children than in adults.

Clinical material

This report concerns the results of splenectomy for hematologic disorders in 51 children seen at the Cleveland Clinic from 1956 through 1970. Follow-up reports have been obtained on 49 of the 51 children, with a mean follow-up period of 8 years and 10 months (106 months).

* *Fellow, Department of General Surgery.*

thrombocytopenic purpura included a history of epistaxis or other prolonged

During this 14-year period, 690 splenectomies were performed for hematologic disorders in both adults and children. Splenectomy for hematologic disease in children thus accounted for 7.4% of our total experience with splenectomy during this period; a small but significant number of all patients with hematologic disease.

Age and Sex. The patients ranged in age from 8 days to 15 years (*Fig. 1*). The mean age was 5 years; the median age was 7 years. Thirty patients were boys, 21 were girls.

Diagnoses. In all but three patients in this pediatric age group, hereditary hemolytic anemia (spherocytosis or elliptocytosis) or chronic idiopathic thrombocytopenic purpura was the indication for splenectomy (*Table 1*).

The indications for splenectomy in the children with hereditary hemolytic anemia included persistent anemia, aplastic crises, and hyperbilirubinemia. Fourteen of these 27 children had family histories of hemolytic anemia. Twenty of the 27 children had palpably enlarged spleens.

The indication for splenectomy in the patients with chronic idiopathic

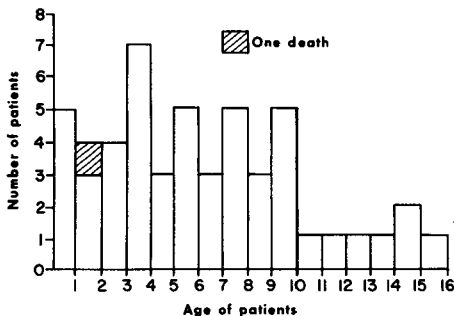


Fig. 1. Bar graph shows the number of patients at each year of age. The single death in the series is identified.

Table 1.—Splenectomy for hematologic disease in 51 children

Diagnosis	Patients, number
Hereditary hemolytic anemias	27 (53%)
Spherocytosis	24
Elliptocytosis	3
Chronic idiopathic thrombocytopenic purpura	21 (41%)
Other diseases	3 (6%)
Gaucher's disease	1
Hypoplastic anemia	1
Wiskott-Aldrich syndrome	1
Total	51

bleeding episodes, and frequent petechiae and ecchymoses after minor trauma. All these patients had thrombocytopenic purpura which persisted for more than 6 months despite therapy. Since the advent of steroid therapy, all patients have been treated with steroids, usually for 4 months or more with no remission of the disease.

In the one patient with Gaucher's disease, a 5-year-old boy, splenectomy was performed for giant splenomegaly with pancytopenia. In the patient with hypoplastic anemia, a 3-year-old boy, splenectomy was performed to prolong red cell and platelet survival. The child with Wiskott-Aldrich syndrome was a 17-month-old boy in whom splenectomy was performed in a final and unsuccessful attempt to improve the platelet count and prevent further hemorrhage (see case report).

Results of operation

Accessory spleens. Accessory spleens were found in 8 of the 51 children (16%) at the time of operation; of the 8 children, 4 were in the group of 27

who had hereditary hemolytic anemia; 3 had chronic idiopathic thrombocytopenic purpura, and 1 had Gaucher's disease. All accessory spleens were removed.

Postsplenectomy infections. Only four patients had unusually severe upper respiratory infections or common colds during the year after splenectomy. There have been no episodes of severe or uncontrolled infections of other types in the follow-up period in this group of patients.

None of the children have had non-infectious conditions, such as collagen disorders or malignancy develop. A follow-up of 8 to 9 years is too brief to draw any conclusions from these observations. However, there is no correlation between malignant disease or collagen disorders and splenectomy in adults.

Mortality. Among the children in whom splenectomy was performed for hereditary hemolytic anemia, there were no postoperative deaths; none have died since operation (mean follow-up of 10 years and 6 months), and all who have been contacted or seen for follow-up examination (one patient is lost to follow-up) are doing well and are no longer anemic. Included in this group are the three youngest patients in this series, two infants 7 weeks of age and one infant 8 days old; all three had severe hemolytic anemia. The results of splenectomy for hereditary hemolytic anemia are excellent.

Among the children in whom splenectomy was performed for chronic idiopathic thrombocytopenic purpura, none died postoperatively, and none have died since operation (mean follow-up of 8 years and 5 months). Eighteen of the 21 patients have had

excellent and sustained response to splenectomy, with marked increase in the platelet counts. Two patients continue to bruise easily: a 6-year-old boy with a platelet count of 100,000/cu mm and a 17-year-old boy with a platelet count of 81,000/cu mm. One patient has been lost to follow-up.

The 5-year-old boy with Gaucher's disease is now 10 years old and from a hematologic standpoint the pancytopenia has improved; however, aseptic necrosis of the right hip (femoral head) has developed. The 3-year-old boy with hypoplastic anemia died of continued intracranial hemorrhages 21 months after splenectomy. He had persistent pancytopenia with platelet counts of about 20,000/cu mm. He had frequent episodes of epistaxis, hematuria, and intracranial hemorrhages. The 17-month-old boy with Wiskott-Aldrich syndrome is the only postoperative death in this group of 51 patients.

Case Report

An 18-month-old white boy was referred to the Cleveland Clinic in August 1961 for evaluation of a red, eczematous rash. This rash first developed shortly after birth as a vesicular and disseminated bullous eruption on the face, both axillae, diaper area, and antecubital regions; it recurred periodically. The bullae became hemorrhagic. There was also a history of repeated upper respiratory and other infections. One month before examination his right knee became swollen, painful, and tender. Two days before this visit, sores developed in the mouth, and the child had a fever of 101-102F. There was no family history of similar lesions, no definite history of allergy or exposure to toxins,

and no evidence of insect or other bites. Growth and development had been normal.

Results of physical examination were normal except for the disseminated skin rash, enlargement of both tonsils, and swollen gums. There was no adenopathy, and the spleen was not palpable. A complete blood count showed the hemoglobin to be 9.3 g/100 ml, hematocrit reading 30%, and white cell count 9600/cu mm with a normal differential count. The platelet count was 60,000/cu mm; a repeat platelet count was 30,000/cu mm. Bleeding and clotting times were normal. Serum proteins and electrophoretic pattern were normal. X-ray films of the chest and knee were normal. Nasopharyngeal cultures grew pure *Staphylococcus aureus*. A bone marrow aspirate was hypercellular and contained normal megakaryocytes. A skin biopsy of one of the lesions showed only nonspecific dermatitis. The tentative diagnosis was Wiskott-Aldrich syndrome.

The patient was given prednisone, 5 mg four times daily. The skin lesions improved, but he continued to bruise easily with many petechiae and ecchymotic areas. He was released from the hospital after 1 week.

During the next 2 years he had frequent respiratory infections and episodes of pneumonia. His platelet counts remained in the range of 40,000 to 50,000/cu mm, and he had further petechiae and ecchymoses. The eczematoid dermatitis improved.

In October 1963 the child fell and bumped his head, sustaining minimal trauma. He became drowsy, then comatose, vomited three or four times, and had a generalized convulsion. He was again admitted to the Cleveland

Clinic Hospital where examination showed fixed, pinpoint pupils, complete flaccidity, and a left Babinski reflex. Hemoglobin was 10 g/100 ml, white cell count was 27,500/cu mm, and a platelet count was 20,000/cu mm. The diagnosis was intracranial bleeding, and the patient was given fresh whole blood and platelet transfusions. In a further effort to increase the platelet count, emergency splenectomy was performed October 18, 1963. He tolerated the operative procedure well, but remained in coma postoperatively. The platelet count 4 days after operation was 40,000/cu mm. He showed no neurologic improvement and died October 22, 1963.

Discussion

The major indications for splenectomy for hematologic diseases in children are hereditary hemolytic anemias and chronic idiopathic thrombocytopenic purpura. Less common indications for splenectomy are hypoplastic or aplastic anemia, acquired hemolytic anemia, the lipoid storage disorders (Gaucher's disease, Niemann-Pick disease), Letterer-Siwe disease, histiocytosis, thalassemia major or sickle cell anemia (when there is marked splenomegaly and hemolysis), sarcoidosis (involving the spleen), splenic infarctions, and splenic neutropenia.⁴ In reviewing our experience with splenectomy for hematologic disorders from 1956 through 1970, hereditary hemolytic anemia and chronic idiopathic thrombocytopenic purpura accounted for the majority of cases.

We have not performed splenectomy in any patient with acquired hemolytic anemia because this type of anemia is uncommon in children and is usually controlled by steroid

therapy. Splenectomy has not been necessary in any of our patients with sickle cell disease during this 15-year period. The lipoid storage diseases, *thalassemia major*, *sarcoidosis*, and other disorders are uncommon. We have not included in this review cases of children in whom splenectomy was performed for portal hypertension. In these patients, the cause of the portal hypertension is more often thrombosis or cavernous transformation of the extrahepatic portal vein. Splenectomy should be delayed until the child is about 10 years old, when the splenic vein is sufficiently large to permit a splenorenal shunt for portal decompression at the same operative procedure.

Our follow-up studies of these 51 children indicate that there is an excellent prognosis for children who undergo splenectomy for both congenital hemolytic anemia and idiopathic thrombocytopenic purpura. All the children who have had splenectomies for hereditary hemolytic anemia were relieved of the anemia. Approximately 85% of patients with chronic idiopathic thrombocytopenic purpura have had a sustained response to splenectomy with elevation of platelet counts. Two patients in our series continue to bruise easily but have platelet counts in the 80,000 to 100,000/cu mm range. We perform splenectomy only on children with chronic idiopathic thrombocytopenic purpura of 4 months' duration or longer. Those children in whom acute idiopathic thrombocytopenic purpura develops should be treated initially with prednisone for at least 6 weeks with dosages of about 1 mg/kg. Steroid levels can then be reduced. If several trials of steroid therapy fail to produce a

sustained elevation of platelets, then splenectomy should be advised.

Much has been written about the increased risk of severe infections after removal of the spleen in children. This was initially reported by King and Schumacher⁵ in 1952, and since then other authors have also reported increased susceptibility to infection after splenectomy.⁶ We did not find any evidence of increased susceptibility to infection during the months and years after splenectomy in our series of 51 children. Eraklis et al⁷ studied the cases of 467 patients who underwent splenectomies and the conditions that seemed to predispose these patients to an increased risk of infection. The most significant variable seemed to be the underlying or primary disease. Those patients who had serious primary disorders (*thalassemia major*, Aldrich's syndrome, *histiocytosis* or *lipoidosis*) had an increased risk of subsequent fatal infection. In other patients, the risk of infection was minimal. Haller and Jones⁸ reported similar findings in their study of the cases of 51 children who had undergone splenectomies. On the basis of their study, however, they suggested, as have others, that infants less than 1 year of age should be carefully observed after splenectomy and perhaps should be given prophylactic antibiotics. They suggested that, "evidence of early infection after splenectomy calls for immediate, aggressive and specific antibiotic therapy." We agree with this recommendation.

Summary

The cases of 51 children in whom splenectomy was performed for hematologic disease are reviewed. Twenty-seven of the patients had hereditary

hemolytic anemia (spherocytosis or elliptocytosis) and 21 had chronic idiopathic thrombocytopenic purpura. Three children had less common disorders. In this group of 51 patients, the one postoperative death was related to the underlying disease, Wiskott-Aldrich syndrome.

The mean follow-up period in these 51 children has been 8 years and 10 months. Splenectomy cured the anemia in the 27 patients with hereditary hemolytic anemia. In the 21 children with chronic idiopathic thrombocytopenic purpura, splenectomy was successful in 85%; the platelet count increased, and there was no further bruising. We have not found an increased susceptibility to severe infection in any of the children who had splenectomies in this series.

References

1. Gomes MM, Silverstein MN, ReMine WH: Indications for splenectomy in hematologic diseases. *Surg Gynecol Obstet* **129**: 129-139, 1969.
2. Sandusky WR, Leavell BS, Benjamin BI: Splenectomy: indications and results in hematologic disorders. *Ann Surg* **159**: 695-710, 1964.
3. Schwartz SI, Bernard RP, Adams JT, et al: Splenectomy for hematologic disorders. *Arch Surg* **101**: 338-347, 1970.
4. Smith CH: Indications for splenectomy in the pediatric patient. *Am J Surg* **107**: 523-530, 1964.
5. King H, Schumacher HB Jr: Splenic studies. I. Susceptibility to infection after splenectomy performed in infancy. *Ann Surg* **136**: 239-242, 1952.
6. Smith CH, Erlandson M, Schulman I, et al: Hazard of severe infections in splenectomized infants and children. *Am J Med* **22**: 390-404, 1957.
7. Eraklis AJ, Kevy SV, Diamond LK, et al: Hazard of overwhelming infection after splenectomy in childhood. *N Engl J Med* **276**: 1225-1229, 1967.
8. Haller JA Jr, Jones EL: Effect of splenectomy on immunity and resistance to major infections in early childhood: clinical and experimental study. *Ann Surg* **163**: 902-908, 1966.