

# Retroperitoneal cystic lymphangioma

## *Report of two cases and review of the literature*

Brij M. Rekhi, M.D.\*

Caldwell B. Esselstyn, Jr., M.D.

Issac Levy, M.D.†

*Department of General Surgery*

Robert D. Mercer, M.D.

*Department of Pediatrics and Adolescent Medicine*

Cystic lymphangiomas (cystic hygromas) are comparatively rare tumors. Seventy-five percent of these lesions are in the neck, 20% are in the axillary region, and 5% are in the mediastinum, retroperitoneal region, pelvis, or groin.

Rarest are retroperitoneal cystic lymphangiomas. Beahrs et al<sup>1</sup> reported nine cases of such tumors diagnosed at the Mayo Clinic from 1911 to 1947. Rauch<sup>2</sup> found 22 cases of retroperitoneal lymphangiomas reported before 1959. Kafka and Novak<sup>3</sup> added 10 cases and reported one of their own. Recently, Singh et al<sup>4</sup> described another case, bringing the total number of reported cases of retroperitoneal cystic lymphangiomas to 34.

We report two cases with unusual features: one patient had preoperative angiograms, the second patient had an acute condition within the abdomen.

### **Pathology**

It is believed that cystic lymphangiomas develop from portions of the sacs sequestered from the primary lymph sacs during embryonic life. Different theories regarding the pathogenesis of these lesions have included infiltrating neoplasm, areas of localized lymphatic stasis due to

\* *Present address: 205 A Conant Road, Rochester, N.Y. 14623.*

† *Fellow, Department of General Surgery.*

congenital blockage of regional lymphatic drainage, lymph node degeneration, obstruction secondary to inflammation, or fibrosis of existing lymph channels. When a lymphangioma develops, the increase in size is probably due to partial or complete lack of lymphatic communication with adjacent channels.

Grossly these lesions are multilocular masses of cysts varying from 1 mm to 5 cm or more in diameter. They are thin-walled and often communicate with each other. The cysts are filled with clear or straw-colored serous fluid. Microscopically, cyst walls appear as a single layer of flattened endothelium. There may be entrapped muscle fibers, thrombosed blood vessels, or bits of fascia in the enlarging cysts.

### Clinical features

Cystic lymphangiomas occur with equal frequency in children of both sexes. Fifty to 60% of the lesions appear during the first year of life, and 80% to 90% are diagnosed during the second year; they rarely occur in adults. The lesions may appear suddenly, grow rapidly, or cease growth and even regress spontaneously.

A slowly enlarging abdomen may be the only symptom. Small intra-abdominal lymphangiomas are usually asymptomatic. These may be discovered in one of three ways: as a mass found at routine abdominal examination, as an incidental finding during abdominal surgery performed for another reason, or by displacement of organs as seen on routine abdominal roentgenograms.

Routine diagnostic studies will identify an abdominal mass. Intravenous pyelograms and barium studies of the gastrointestinal tract may show

displacement of kidneys, ureter, duodenum, or colon. Although lymphangiography may prove of value in demonstrating such lesions, its use preoperatively has not been reported. Our Case 1 is the first reported use of angiography preoperatively.

### Treatment

The ideal therapy is complete excision of the cystic mass. Cystic lymphangioma is not malignant, and there is no need to sacrifice normal structures in the course of operation. In cases of huge, multilocular lesions, complete excision may be technically impossible, and excision of most of the mass is the procedure of choice. This internal marsupialization results in apparent cure with minimal morbidity. Ascites has not been found in our patients, and it has not been reported by others.

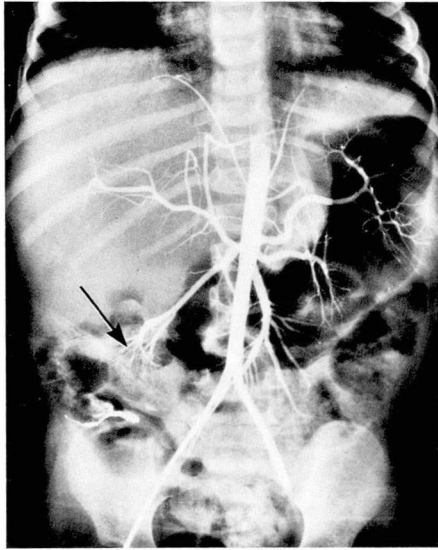
### Case reports

**Case 1.** A 23-month-old girl was admitted to the Cleveland Clinic Hospital on September 26, 1971. She had failed to gain weight and had loose stools. On examination the abdomen was slightly distended. An ill-defined intra-abdominal mass was found in the epigastric, umbilical, and right hypochondriac regions; otherwise the examination was unremarkable. Roentgenograms of the chest, skull, upper gastrointestinal tract, and colon were normal; bone scan, liver scan, and bone marrow study were also normal.

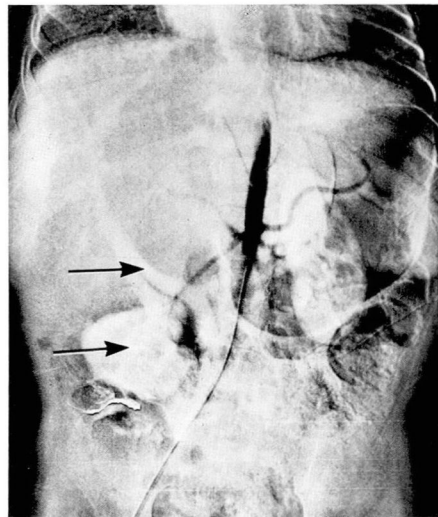
Percutaneous retrograde abdominal angiography showed a mass lesion to the right of the lower thoracic and upper lumbar spine which had displaced the right kidney inferiorly (*Fig. 1*). The inferior vena cava was displaced from the level of the diaphragm to the second lumbar vertebra (*Fig. 2*). The diagnosis of primary hepatic tumor or neurogenic tumor was considered.

At exploration multiple large cysts were

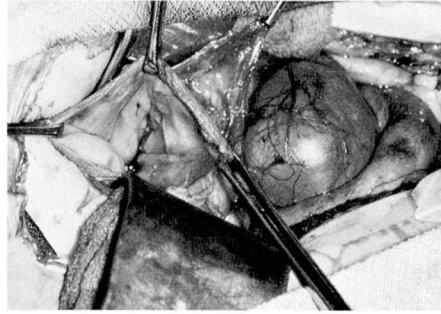
found extending to the diaphragm from underneath the structures of the porta-hepatis, displacing the inferior vena cava and right kidney inferolaterally (*Fig. 3*). It was technically impossible to remove these cysts intact because of the attach-



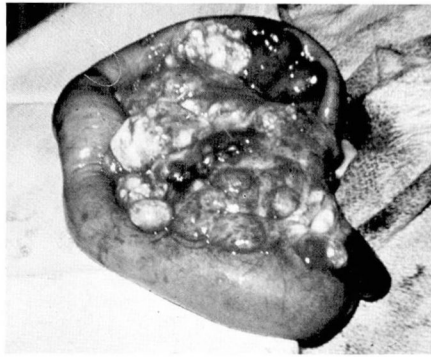
**Fig. 1.** Case 1. Angiogram shows displacement of right kidney inferiorly.



**Fig. 2.** Case 1. Angiogram shows displacement of right kidney and inferior vena cava.



**Fig. 3.** Case 1. Appearance of cystic lymphangioma at laparotomy.



**Fig. 4.** Case 2. Appearance of cystic lymphangioma at laparotomy.

ment to vital structures. After wide excision of the wall, the cysts were left open to drain into the peritoneal cavity. The patient had an uneventful postoperative course, and at a follow-up visit 6 months later the child was healthy, was gaining weight normally, and had no ascites.

Histopathologic diagnosis was cystic lymphangioma.

**Case 2.** A 4-year-old boy was admitted to St. Vincent Charity Hospital on an emergency basis. Increasing vomiting and abdominal pain had begun 15 hours before admission.

On admission the child had a temperature of 38.5 C, and a pulse rate of 92 beats per minute. Generalized tenderness of the region was observed on rectal examination. The clinical impression was an acute condition within the abdomen, pos-

sibly an acute appendicitis. Except for an elevated white cell count of 14,100/cu mm, the laboratory findings were normal.

At exploration large, soft, fluid-filled masses were palpable at the base of the mesentery (*Fig. 4*). These intercommunicating cystic masses contained clear, bright yellow fluid. The largest cyst was drained through a small excisional biopsy of the wall. Histopathologic examination confirmed the diagnosis of cystic lymphangioma.

The cause of the onset of acute symptoms in this child is not known. The normal appearing appendix was removed. The appearance of free fluid in the abdominal cavity was suggestive of possible leakage of fluid from one of the cysts. The periaortic lymph nodes were large and firm, but nodes of the terminal ileum did not appear sufficiently enlarged to support a diagnosis of mesenteric adenitis. However, the nodes of the terminal ileum were not biopsied.

#### Discussion and summary

Although retroperitoneal cystic lymphangioma is rare, it should be considered a possibility whenever there is roentgenographic evidence of intra-abdominal organ displacement, especially in children under 2 years of age.

Retroperitoneal cystic lymphangiomas may present unusual symptoms as an acute condition within the abdomen as in one of our patients, or a failure to thrive as in the other. Angiography, although not diagnostic of cystic lymphangioma, may aid in locating the lesion. The benign nature of the lesion warrants a conservative surgical approach. It is unnecessary to sacrifice adjacent vital structures. Internal marsupialization of cystic lymphangiomas has been curative.

#### Acknowledgment

The authors thank Patrick A. Ferrara, M.D. for permitting study of the patient in Case 2.

#### References

1. Beahrs OH, Judd ES Jr, Dockerty MB: Chylous cysts of the abdomen. *Surg Clin North Am* 30: 1081-1096, 1950.
2. Rauch RF: Retroperitoneal lymphangioma. *Arch Surg* 78: 45-50, 1959.
3. Kafka V, Novak K: Multicystic retroperitoneal lymphangioma in an infant appearing as an inguinal hernia. *J Pediatr Surg* 5: 573, 1970.
4. Singh S, Baboo ML, Pathak IC: Cystic lymphangioma in children, report of 32 cases including lesions at rare sites. *Surgery* 69: 947-951, 1971.