

Coexistent herpes simplex encephalitis and malignant astrocytoma

A clinicopathologic study of three cases

Sanford P. Benjamin, M.D.*

Lawrence J. McCormack,
M.D.

M. Eyad Chatty, M.D.†

Department of Pathology

Donald F. Dohn, M.D.

Department of Neurological Surgery

Of the multitude of oncogenic viruses known to man, the herpesvirus is most commonly associated with malignancy. Herpesvirus Type II has been implicated as an oncogenic agent in carcinoma of the cervix.¹⁻⁶ Epstein-Barr virus (EBV), a herpes-like virus, has been found with striking frequency in isolates of Burkitt's lymphoma, Hodgkin's lymphoma, and nasopharyngeal carcinoma.⁷⁻¹⁸ The purpose of this paper is to discuss the previously unreported entity of coexistent herpesvirus infection of the brain and malignant astrocytoma (glioblastoma multiforme) in three patients.

Case reports

Case 1. A 57-year-old man was confused and lethargic for 4 months before he was admitted to the Cleveland Clinic Hospital for the first time. He had diarrhea which did not respond to tetracycline or penicillin therapy, and a temperature of 100 to 101 F. He was hospitalized 4 weeks in another hospital for treatment of viral pneumonia. After discharge the patient's wife noted that he continued to be confused, repeated questions, and had lapses of memory, especially of recent events.

* *Fellow, Department of Pathology.*

† *Present address: Sabky Park, Damascus, Syria.*

One month before admission to Cleveland Clinic Hospital the patient was rehospitalized because of persistent fever and confusion. Roentgenograms of the skull and chest and four electroencephalograms were interpreted as normal. The cerebrospinal fluid contained 70 mg/100 ml glucose and 76 mg/100 ml protein. Direct smears and culture for acid-fast bacilli, fungus, and "routine" pathogens were negative; 5 mononuclear white blood cells and 328 red blood cells, mostly crenated, were seen. The patient was transferred to Cleveland Clinic Hospital for further evaluation and treatment.

On admission his temperature was 100.8 F, pulse rate 110, respirations 24 per minute, blood pressure 160/100 mm Hg. He was drowsy and the sensorium was described as "blunted." Pertinent neurological findings included a right homonymous hemianopsia, bilateral horizontal and vertical nystagmus, and decreased strength in the right upper extremity. The remainder of the physical examination was normal. Diagnostic impression was intracranial neoplasm or abscess.

Laboratory studies disclosed the following values: hemoglobin, 14.8 g/100 ml; white blood cell count, 6,000/cu mm, with 70% segmented neutrophils, 24% lymphocytes, and 6% monocytes. Urinalysis was normal. Serum cholesterol, calcium, phosphorus, bilirubin, albumin, total protein, uric acid, BUN, glucose, LDH, alkaline phosphatase, and SGOT were within normal limits. Spinal fluid obtained by lumbar puncture was clear, with less than 100 red blood cells and 6 mononuclear white cells, protein 61 mg/100 ml, and glucose 68 mg/100 ml. No atypical cells were found in the spinal fluid.

Electroencephalography revealed an abnormal focus in the left temporal region, more suggestive of glioma than abscess. Pneumoencephalography and left carotid angiography suggested the presence of a deep posteromedial left temporal space-occupying lesion.

A left temporal craniotomy was performed. A large infiltrating neoplasm was found in the posterior-inferior temporal lobe. The surrounding nonneoplastic inferomedial temporal cerebrum was swollen, red, and partially necrotic. A large segment of the abnormal temporal lobe was removed by suction cauterization.

Diagnoses based on histopathologic findings were malignant astrocytoma (glioblastoma multiforme) and inclusion body encephalitis. Postoperatively the patient remained febrile but was awake and moved all extremities. Viral cultures of brain obtained during surgery were positive for herpes simplex virus. A tracheostomy was performed 48 hours later for respiratory insufficiency. The patient was comatose until his death 11 days later.

At postmortem examination, the remnant of the left temporal lobe showed hemorrhagic necrosis with a small amount of residual neoplasm. Transverse brain sections revealed recent gross hemorrhages in the posterior midbrain, pons, medulla oblongata, and cerebellum. These hemorrhages were thought to be secondary to supratentorial pressure. No gross or microscopic evidence of extracerebral herpetic infection was encountered.

Cases 2 and 3. These cases were remarkably similar to Case 1. In both cases the patients had been febrile preoperatively. In both, the physical examination, electroencephalogram, pneumoencephalogram, and arteriogram were suggestive of a mass lesion in the temporal lobe. Both patients had elevated spinal fluid protein and microscopic confirmation of malignant astrocytoma and inclusion body encephalitis. One patient died. The other patient, in whom the neoplasm was incompletely removed, has maintained useful functional activity for 3 months postoperatively, with no evidence of encephalitis.

The diagnosis of malignant astrocytoma was established by macroscopic criteria as well as by light and electron

microscopy. Grossly, all three neoplasms were soft, friable, and grey with areas of necrosis and hemorrhage. Light microscopy demonstrated pseudopalisading of tumor cells in the areas of necrosis, astrocytic cellular pleomorphism with giant cell forms, numerous mitotic figures, and proliferation of small blood vessels with capillary endothelial proliferation (*Fig. 1*).

The diagnosis of herpes simplex encephalitis was established by: (1) characteristic light microscopic changes (three cases); (2) identification of classic herpesvirus particles by electron microscopy (two cases); and (3) isolation of herpesvirus by tissue culture techniques (two cases).

Light microscopy. As noted during craniotomy or at postmortem examination, in all three cases the encephalitic

temporal cerebrum was grossly swollen, partially necrotic and hemorrhagic, with broadening and flattening of the cerebral gyri. On microscopic examination of Zenker's-fixed, hematoxylin-eosin stained tissue, these areas of acute hemorrhagic necrosis demonstrated infiltration of the overlying meninges by lymphocytes and occasional macrophages. The blood vessels of both the cortex and white matter were uniformly surrounded by dense aggregates of lymphocytes, macrophages, rare polymorphonuclear leukocytes, and plasma cells extending into the perivascular Virchow-Robin space (*Figs. 2 and 3*). Petechial hemorrhages, and foci of reactive astrocytic and oligodendroglial gliosis were also noted.

The single most important finding

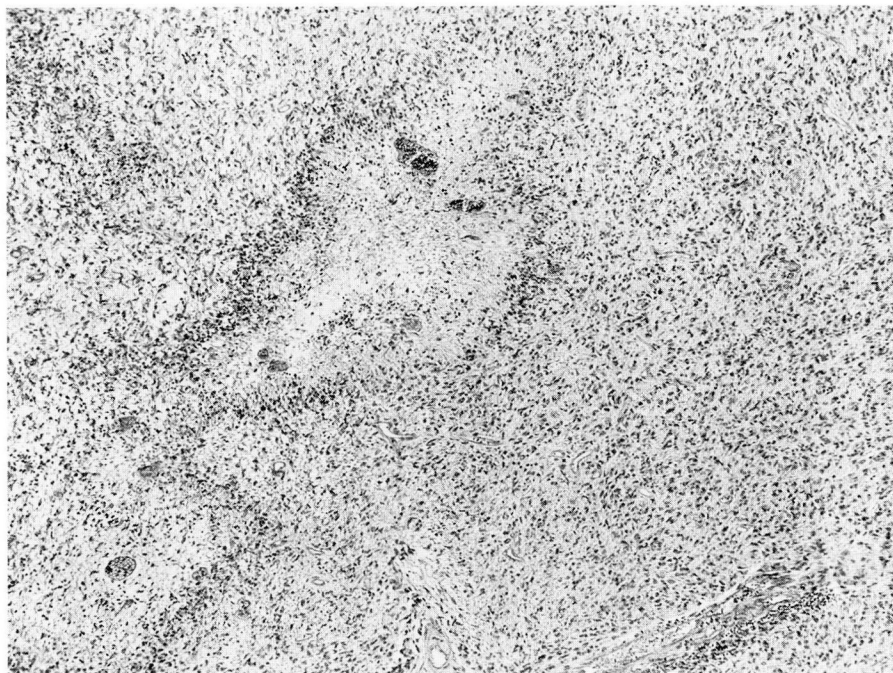


Fig. 1. Photomicrograph of malignant astrocytoma (glioblastoma multiforme) with prominent pseudopalisading about an area of necrosis (hematoxylin-eosin, $\times 64$).

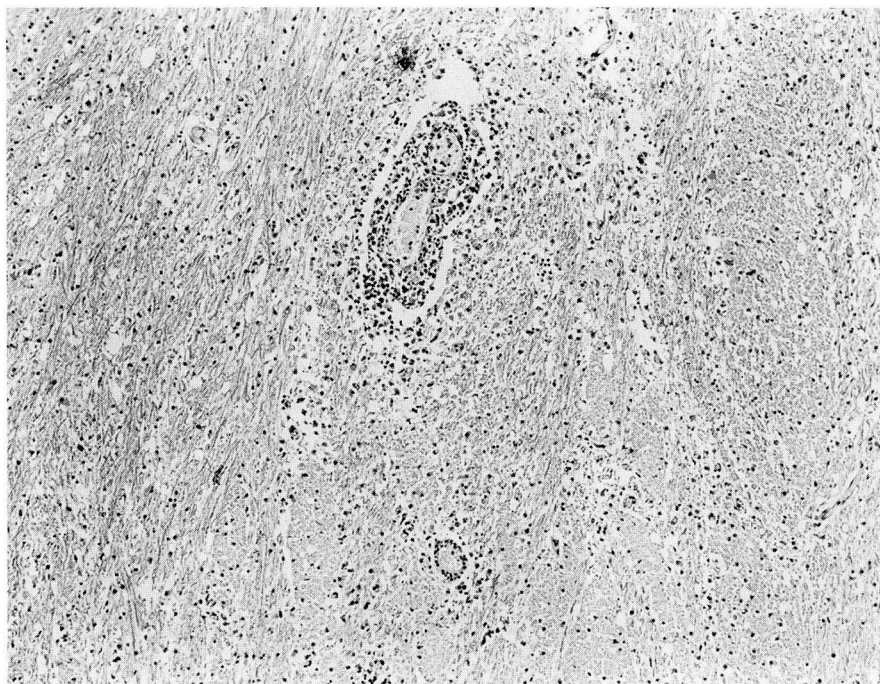


Fig. 2. Photomicrograph demonstrating perivasculitis in nonneoplastic temporal white matter (hematoxylin-eosin, $\times 64$).

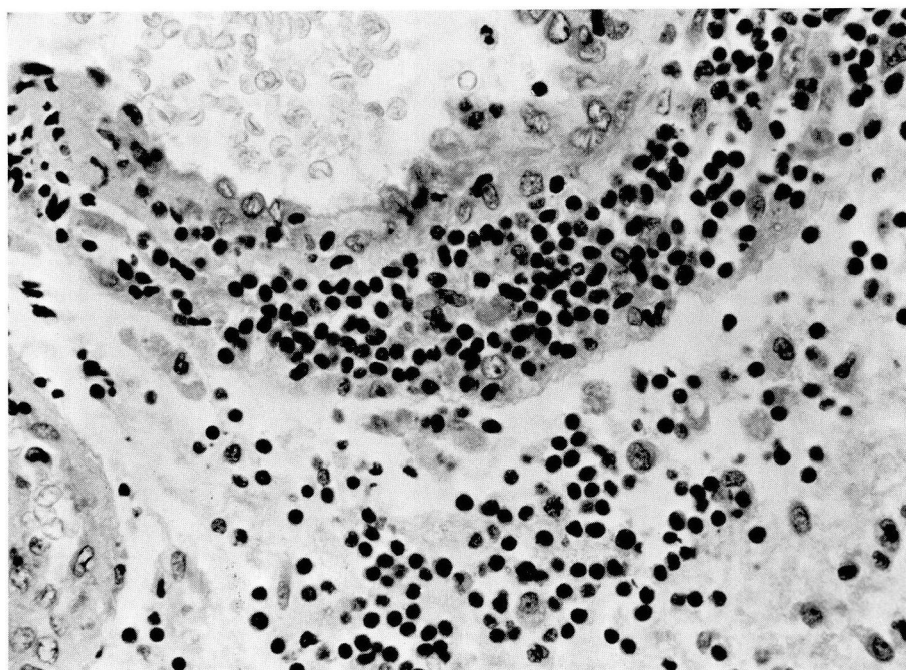


Fig. 3. Photomicrograph showing predominantly mononuclear inflammatory infiltrate involving a vessel of the temporal white matter with extension into the Virchow-Robin perivascular space (hematoxylin-eosin, $\times 400$).

by light microscopy was the presence of characteristic Cowdry Type A inclusion bodies in astrocytes and oligodendroglia within the encephalitic process. The Cowdry Type A inclusion body is a homogeneous eosinophilic intranuclear sphere surrounded by a clear halo, with resultant displacement of the chromatin material to the periphery of the nucleus (*Fig. 4*).¹⁹⁻²⁸ The inclusion bodies showed positive selective staining with phosphotungstic acid hematoxylin. In human encephalitis these inclusion bodies may be associated with a variety of viruses including measles, varicella (herpes zoster), cytomegalovirus, and subacute inclusion-body encephalitis of Dawson.^{24, 29-31} Therefore, the demonstration of inclusion bodies is only presumptive evidence of herpes simplex infection; yet some investigators be-

lieve that the diagnosis of herpes simplex encephalitis is justified for any acute necrotizing inclusion-body encephalitis with unique localized involvement of the inferomedial portions of the frontal and temporal lobes.^{24, 28, 32}

Electron microscopy. Specimens for electron microscopy were fixed in gluteraldehyde or retrieved from formalin, postfixed in osmium tetroxide, embedded in Epon, and stained with uranyl acetate and lead citrate. Examination of the cells with Cowdry A inclusions and peripheral margination of chromatin revealed numerous nuclear and cytoplasmic viral particles morphologically characteristic of herpes simplex.^{31, 33-38} Most particles consisted of an electron-dense central core 400-500 Å in diameter surrounded by a halo of low electron

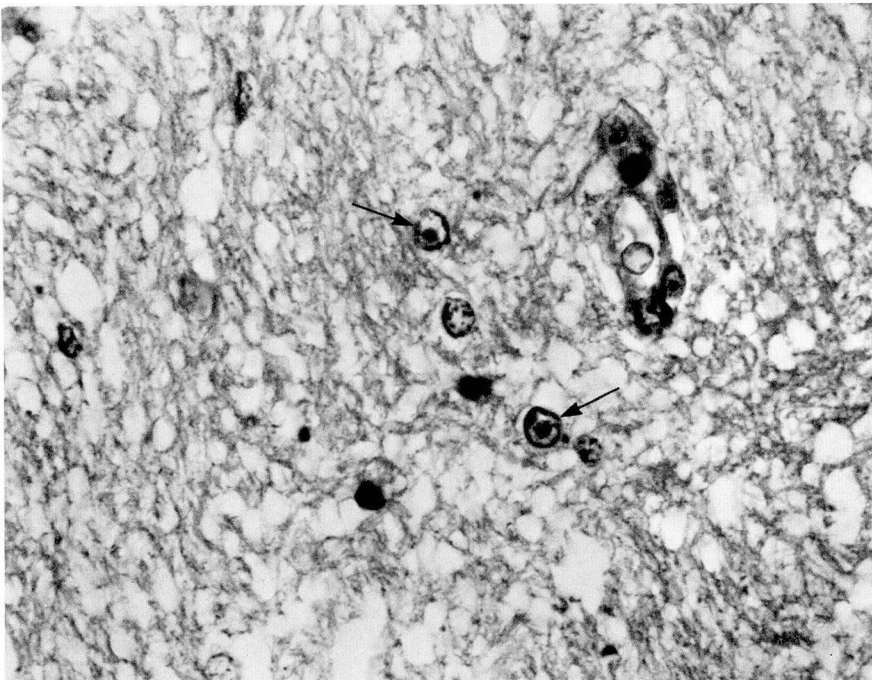


Fig. 4. Photomicrograph of Cowdry Type A inclusion bodies with peripheral margination of chromatin in two nonneoplastic astrocytic nuclei (hematoxylin-eosin, $\times 640$).

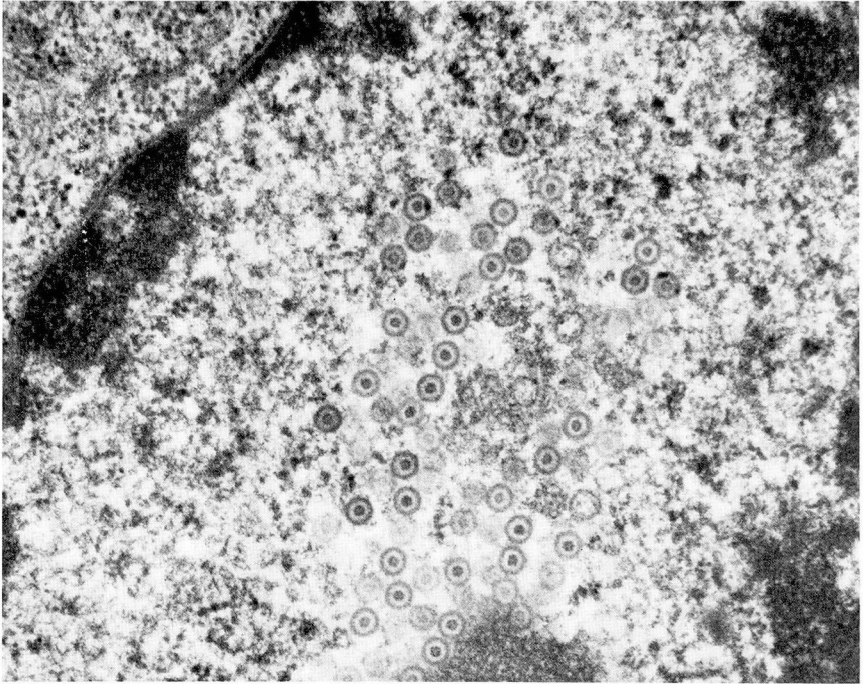


Fig. 5. Electron micrograph of intranuclear herpesvirus particles with central core and surrounding capsid envelopes ($\times 29,800$).

density and encapsulated by a thin outer hexagonal membrane known as the capsid (*Fig. 5*). A few capsids were devoid of their central core. The herpesvirus particles were identified in two cases, primarily in nonneoplastic glial cells, although in each case intensive search revealed a few malignant astrocytes with intranuclear and intracytoplasmic herpes simplex viral particles.

Viral studies. Viral isolations by tissue culture technique were positive for herpes simplex virus in two cases; attempts at isolating herpes simplex from brain specimens in Case 3 were unrewarding, despite the presence of Cowdry A inclusion bodies and electron microscopic demonstration of viral particles. It has been suggested that inability to isolate the herpesvirus,

or any other virus, in similar cases of acute necrotizing inclusion body encephalitis is an unfortunately common occurrence.^{29, 32, 38} Some authors relate this to chronicity of the disease, noting that herpesvirus previously isolated in a brain can no longer be isolated after a certain interval, even though the acute encephalitic process is still clinically and histologically active.²⁹

A fourth patient who had a brief history of febrile illness with rapidly progressive neurological deficit was seen on the neurological service. Results of physical examination, electroencephalography, and arteriography suggested a deep lesion of the right temporal lobe, inferomedial aspect. After craniotomy, we were able to confirm the diagnosis of malignant astrocytoma and inclusion-body encephalitis in the

adjacent temporal cerebrum. Tissue culture techniques and electron microscopy failed to reveal the presence of virus, thus preventing an objective conclusion as to the exact nature of the inclusion-body encephalitis.

Discussion

The large number of animal cancers with a documented viral etiology suggests that some human cancers may be virus-induced or virus related. Herpesvirus is an especially well-documented agent in neoplastic transformation in lower animals, including Marek's lymphoma of chickens,³⁹ lymphoma of rabbits and monkeys,⁴⁰ leukemia of guinea pigs,^{41, 42} and Lucke renal adenocarcinoma of frogs. The search for human cancer virus was further stimulated when Burkitt described a malignant lymphoma of African children.⁴³ The Burkitt lymphoma, as initially described, occurred only in certain geographic areas of Africa, with a distribution overlapping that of certain insect vectors. Burkitt suggested that the lymphoma was induced by an infectious agent transmitted by an insect vector. Since Burkitt's initial report, numerous investigators have demonstrated that tissue cultures of Burkitt lymphoma cells contain characteristic DNA herpes-like virus.⁷⁻¹⁷

The fact that latency in the central nervous system is a well recognized *in vivo* biologic characteristic of herpes simplex virus may bear a relationship to brain neoplasia. Herpes simplex virus differs from other infectious agents in its capacity to remain latent in the central nervous system of man and to be subsequently reactivated.^{18, 44-46} Latent or so-called "dormant forms" of herpes simplex virus appear to occur within brain cells that are not

actively growing and dividing.⁴⁵⁻⁴⁷ Thus an equilibrium exists between host brain cells and virus. The mechanism for latency is not known, yet herpesvirus latency appears to occur in cells not actively growing. This is an appealing premise on which to base the hypothesis that some unidentified factor related to mitotic activity is associated with virus maturation. All four malignant astrocytomas in this series were highly cellular, with prominent mitotic activity providing what is theoretically an optimum environment for herpes virus maturation. We are unable to conclude objectively whether the herpesvirus is truly an oncogenic agent or a potentially lethal secondary invader in the company of malignant astrocytoma.

Summary

The well-known biologic characteristic of herpesvirus latency in the human central nervous system may bear an important relationship to astrocytic neoplasia. Coexistent herpes simplex encephalitis and malignant astrocytoma is a previously unreported entity seen in three patients during a 20-month period. The diagnosis of herpes simplex encephalitis was established by two or more parameters: (1) light microscopic demonstration of characteristic Type A inclusion bodies and other nonspecific changes such as mononuclear perivasculitis, petechial hemorrhages and necrosis; (2) herpes simplex isolation in tissue culture; or (3) electron microscopic demonstration of characteristic herpesvirus particles. Past and present evidence cannot objectively distinguish between herpesvirus as a causal agent of malignant astrocytoma or as a potentially lethal

“passenger” virus of important clinical significance.

Acknowledgments

We thank Dr. M. Rosenthal, St. Luke's Hospital, Cleveland, Ohio, and Mr. Dallas Gary Osborne, Department of Electron Microscopy, Cleveland Clinic, for assistance in the preparation of this manuscript.

References

1. Rawls WE, Tompkins WA, Figueroa ME, et al: Herpesvirus Type 2; association with carcinoma of the cervix. *Science* **161**: 1255-1256, 1968.
2. Nahmias AJ, Naib ZM, Josey WE: Association of a genital herpesvirus with cervical cancer. *Int Virol* **1**: 187-188, 1969.
3. Naib ZM, Nahmias AJ, Josey WE, et al: Genital herpetic infection: association with cervical dysplasia and carcinoma. *Cancer* **23**: 940-945, 1969.
4. Nahmias AJ, Dowdle WR: Studies on herpesvirus hominis type 2. *Int Virol* **1**: 254, 1969.
5. Josey WE, Nahmias AJ, Naib ZM: Genital infection with type 2 herpesvirus hominis; present knowledge and possible relation to cervical cancer. *Am J Obstet Gynecol* **101**: 718-729, 1968.
6. Royston I, Aurelian L: The association of genital herpesvirus with cervical atypia and carcinoma in situ. *Am J Epidemiol* **91**: 531-538, 1970.
7. Epstein MA: Aspects of the EB virus. *Adv Cancer Res* **13**: 383-411, 1970.
8. Henle W, Henle G, Ho HC, et al: Antibodies to Epstein-Barr virus in nasopharyngeal carcinoma, other head and neck neoplasms, and control groups. *J Natl Cancer Inst* **44**: 225-231, 1970.
9. Levine PH, Ablashi DV, Berard CW, et al: Elevated antibody titers to Epstein-Barr virus in Hodgkin's disease. *Cancer* **27**: 416-421, 1971.
10. Goldman JM, Aisenberg AC: Incidence of antibody to EB virus, herpes simplex, and cytomegalovirus in Hodgkin's disease. *Cancer* **26**: 327-331, 1970.
11. Henle G, Henle W, Clifford P, et al: Antibodies to Epstein-Barr virus in Burkitt's lymphoma and control groups. *J Natl Cancer Inst* **43**: 1147-1157, 1969.
12. Diehl V, Henle G, Henle W, et al: Demonstration of a herpes group virus in cultures of peripheral leukocytes from patients with infectious mononucleosis. *J Virol* **2**: 663-669, 1968.
13. Dalton A, Manaker RA: The comparison of virus particles associated with Burkitt lymphoma with other herpes-like viruses, p. 72 in *Carcinogenesis: A Broad Critique; a collection of papers. Annual Symposium on Fundamental Cancer Research*, M.D. Anderson Hospital and Tumor Institute, Houston, Tex. Baltimore: Williams and Wilkins, 1967.
14. Henle G, Henle W, Diehl V: Relation of Burkitt's tumor-associated herpes-type virus to infectious mononucleosis. *Proc Natl Acad Sci USA* **59**: 94-101, 1968.
15. Dulbecco R: Viruses in carcinogenesis. *Ann Intern Med* **70**: 1019-1030, 1969.
16. Allen DW, Cole P: Viruses and human cancer. *N Engl J Med* **286**: 70-82, 1972.
17. MacMahon B: Epidemiologic aspects of acute leukemia and Burkitt's tumor. *Cancer* **21**: 558-561, 1968.
18. Miller RW: Radiation, chromosomes and viruses in the etiology of leukemia; evidence from epidemiologic research. *N Engl J Med* **271**: 30-36, 1964.
19. Smith MG, Lennette EH, Reames HR: Isolation of the virus of herpes simplex and the demonstration of intranuclear inclusions in a case of acute encephalitis. *Am J Pathol* **17**: 55-68, 1941.
20. Zarafonitis CJ, Smadel JE, Adams JW, et al: Fatal herpes simplex encephalitis in man. *Am J Pathol* **20**: 429-445, 1944.
21. Pearson HE, Butt EM: Hemorrhagic herpetic encephalitis. *Am J Clin Pathol* **26**: 1174-1179, 1956.
22. MacCallum FO, Potter JM, Edwards DH: Early diagnosis of herpes-simplex encephalitis by brain biopsy. *Lancet* **2**: 332-334, 1964.
23. Pierce NF, Leeds NR, Portnoy B, et al: Encephalitis associated with herpes simplex infection presenting as a temporal lobe mass; report of 2 cases with survival. *Neurology* **14**: 708-713, 1964.
24. Drachman DA, Adams RD: Herpes simplex and acute inclusion body encephalitis. *Arch Neurol* **7**: 45-63, 1962.

25. Cowdry EV: The problem of intranuclear inclusions in virus diseases. *Arch Pathol* 18: 527-542, 1934.
26. Harland WA, Adams JH, McSeveney D: Herpes-simplex particles in acute necrotizing encephalitis. *Lancet* 2: 581-582, 1967.
27. McKee AP, Hudson JD, Kimura J, et al: Herpes simplex encephalitis. *South Med J* 61: 217-225, 1968.
28. Haynes RE, Azimi PH, Cramblett HG: Fatal herpesvirus hominis (herpes simplex virus) infections in children. Clinical, pathologic, and virologic characteristics. *JAMA* 206: 312-319, 1968.
29. Johnson RT, Olson LC, Buescher EL: Herpes simplex virus infections of the central nervous system. Problems in laboratory diagnosis. *Arch Neurol* 18: 260-264, 1968.
30. Tellez-Nagle I, Harter DH: Subacute sclerosing leukoencephalitis; ultrastructure of intranuclear and intracytoplasmic inclusions. *Science* 154: 899-901, 1966.
31. Hashida Y, Yunis EJ: Re-examination of encephalitic brains known to contain intranuclear inclusion bodies; electron-microscopic observation, following prolonged fixation in formalin. *Am J Clin Pathol* 53: 537-543, 1970.
32. Rawls WE, Dyck PJ, Klass DW, et al: Encephalitis associated with herpes simplex virus. *Ann Intern Med* 64: 104-115, 1966.
33. Baringer JR, Griffith JF: Experimental herpes simplex encephalitis; early neuropathologic changes. *J Neuropathol Exp Neurol* 29: 89-104, 1970.
34. Friedrich ER, Cole W, Middelkamp JN: Herpes simplex. Clinical aspects and electron microscopic findings. *Am J Obstet Gynecol* 104: 758-779, 1969.
35. Morgan C, Rose HM, Mednis B: Electron microscopy of herpes simplex virus I entry. *J Virol* 2: 507-516, 1968.
36. Swanson JL, Craighead JE, Reynolds ES: Electron microscopic observations of Herpesvirus hominis (herpes simplex virus) encephalitis in man. *Lab Invest* 15: 1966-1981, 1966.
37. Ames RP, Reagan RL, O'Connor CC: Herpes-type infection in adult with hematologic disorder. Electron microscopic observations of virus and case report. *Cancer* 20: 2159-2169, 1967.
38. Olson LC, Buescher EL, Artenstein MS, et al: Herpesvirus infections of the human central nervous system. *N Engl J Med* 277: 1271-1277, 1967.
39. Churchill AE: Herpes-type virus isolated in cell culture from tumors of chickens with Marek's disease. I. Studies in cell culture. *J Natl Cancer Inst* 41: 939-950, 1968.
40. Melendez LV, Hunt RD, Daniel MD, et al: Herpesvirus saimiri; II. Experimentally induced malignant lymphoma in primates. *Lab Anim Care* 19: 378-386, 1969.
41. Hsiung GD, Kaplow LS: Herpes-like virus isolated from spontaneously degenerated tissue culture derived from leukemia-susceptible guinea pigs. *J Virol* 3: 355-357, 1969.
42. Opler SR: Animal model of viral oncogenesis. *Nature* 215: 184, 1967.
43. Burkitt D: A children's cancer with geographical limitations. *Cancer Progr* pp 102-113, 1963.
44. Lennette EH, Magoffin RL, Knouf EG: Viral central nervous system disease; etiologic study conducted at Los Angeles County Hospital. *JAMA* 179: 687-695, 1962.
45. Burnet FM, Williams SW: Herpes simplex; new point of view. *Med J Aust* 1: 637-642, 1939.
46. Leider W, Magoffin RL, Lennette EH, et al: Herpes-simplex-virus encephalitis; its possible association with reactivated latent infection. *N Engl J Med* 273: 341-347, 1965.
47. Goodheart CR: Herpesvirus and cancer. *JAMA* 211: 91-96, 1970.