

## SILICOSIS

A. CARLTON ERNSTENE, M.D.

Although excellent discussions of the clinical, roentgenologic, and pathologic aspects of silicosis are available in the literature, accurate knowledge of the characteristics of the disease has not yet been widely diffused. Because of this and because the industrial and medicolegal importance of silicosis is constantly increasing, it seemed that a report of a typical case and a brief discussion of the more important features of the disease should be of interest.

### REPORT OF CASE

The patient, a white man, aged 56 years, had experienced frequent attacks of bronchitis during the winter months for more than twenty years. Fifteen years ago he had had a persistent productive cough which was accompanied by low-grade fever, night sweats, weakness, and a loss of 20 pounds in weight. A diagnosis of pulmonary tuberculosis was made, but the patient did not know whether tubercle bacilli were found in the sputum. A daily elevation in temperature to 100° or 101° F. had persisted for several months, and for the next three years the patient had spent practically all his time resting. He had then taken up farming and had been able to do hard work although a productive morning cough continued and strenuous exertion always caused definite dyspnea. He had continued to have frequent "colds" during the winter months, and of late years these had been accompanied by severe attacks of wheezing which were relieved by the subcutaneous administration of epinephrine. The weight which had been lost at the onset of the illness had never been regained.

Three weeks before coming to the Clinic the patient had experienced an acute infection of the upper respiratory tract and since that time he had been unable to work because of dyspnea, cough, and general weakness.

Between the ages of 14 and 41 years the patient had been employed continuously in a stove works making large molds from sand.

Physical examination revealed a well developed but rather poorly nourished individual who experienced moderate dyspnea upon such slight exertion as undressing and dressing. There was no cyanosis. The pupils reacted normally. The thorax was symmetrical and the respiratory movements were equal on the two sides although diminished in extent. The breath sounds were diminished and expiration was prolonged throughout both lungs. Rhonchi were present in all lung fields, and numerous medium moist râles were heard over both bases. The heart was not enlarged and its rate and rhythm were normal, but all sounds were somewhat faint. The arterial blood pressure was 115 mm. systolic and 80 mm. diastolic. Examination of the abdomen and of the extremities revealed nothing abnormal.

Urinalysis and blood counts gave normal results. The erythrocyte sedimentation rate was moderately elevated above the normal. Four specimens of sputum were examined and no tubercle bacilli were found.

Roentgenologic examination of the chest (Fig. 1) showed extensive nodular mottling throughout both lungs characteristic of silicosis. The individual nodules were discrete and sharply circumscribed and for the most part were between 2 mm. and 4 mm. in diameter. All lung fields were involved although the most extensive changes were present in the mid-portion on either side.

## SILICOSIS

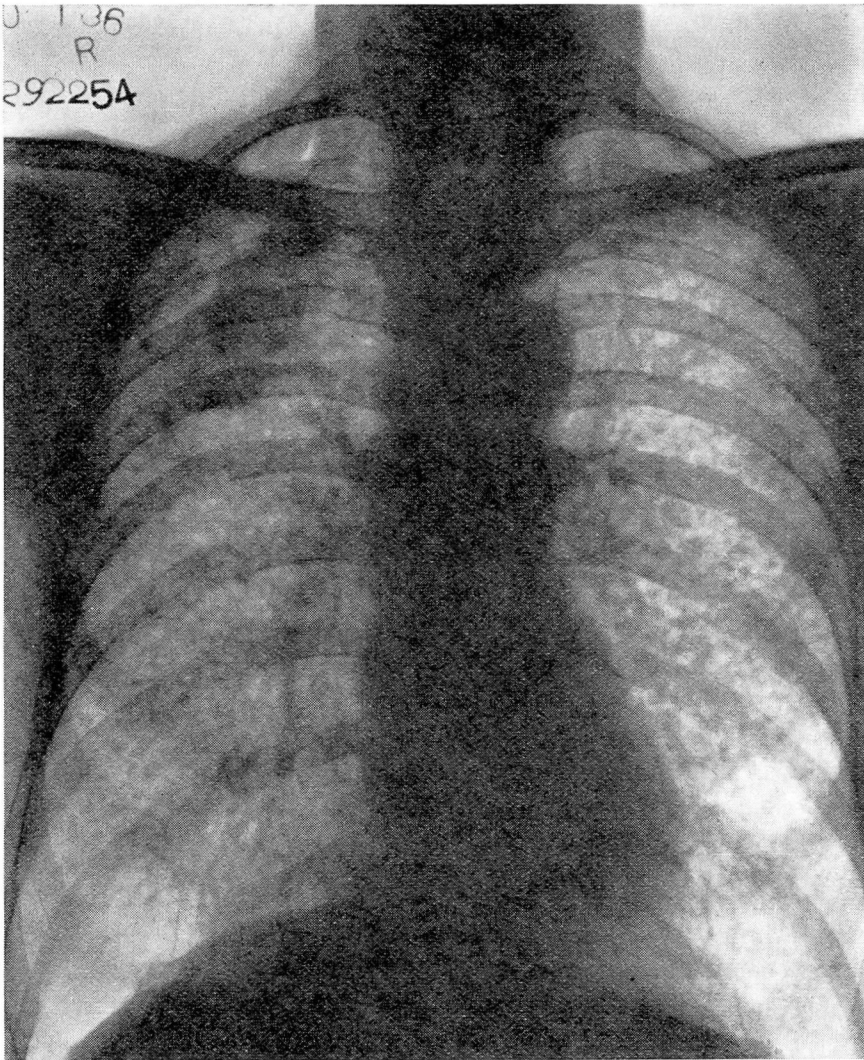


FIGURE 1: Roentgenogram of the chest.

In addition to the generalized mottling, the upper lobe of the right lung contained an area of fairly uniform infiltration which measured 6 cm. by 4 cm. in its greatest diameter. The upper lobe of the left lung contained two similar areas which were circular in outline and measured 2.5 cm. and 1.4 cm. respectively in diameter.

### DISCUSSION

Silicosis results only from the inhalation of free silica (silicon dioxide). All other dusts, with the exception of asbestos, are quite harmless; they may cause pigmentation and slight proliferation of

## A. CARLTON ERNSTENE

fibrous tissue in the lungs but they do not in any way interfere with pulmonary function. Asbestos is a hydrated magnesium silicate of variable composition and causes a type of pulmonary pathology entirely different from silicosis. Silicon dioxide is encountered in industry in several different forms, most commonly as sand, sandstone, tripoli, quartz, quartzite, flint, and diatomaceous earth.

The development of silicosis is governed by a number of factors, the most important of which are: (1) the size of the inhaled particles of silica, (2) the intensity of exposure to silica particles of suitable size, and (3) the duration of exposure. In order to reach the air spaces of the lungs and become of importance pathologically, particles of silicon dioxide must be less than ten microns in diameter. The silica content of dust to which a worker is exposed may vary from extremely low to as high as 99 per cent. Usually exposure to silica-containing dust must extend over a period of 10 or 12 years before evidence of silicosis develops. Occasionally, however, extreme exposure may result in the appearance of the disease within 2 or 3 years.

The exact manner in which silica produces harmful effects in the lungs has not been determined. The earlier belief that the pathologic changes were due to the mechanical action of particles of silica has been discarded, and it is now believed that silica acts as a tissue poison through a chemical or a physico-chemical action.

Silicosis is characterized by the occurrence of fibrosis about the lymphatic vessels of the lungs and the development of nodules of fibrosis in the lymphoid tissue. It is this latter nodular fibrosis which gives rise to the pathognomonic roentgenologic findings in the disease, namely diffuse granular mottling throughout the lungs. The development of this mottling is preceded by an increase in the linear markings in the lungs, but these earlier changes are not of diagnostic importance. Even though a person may have a history of prolonged exposure to silica-containing dust, a diagnosis of silicosis cannot be made until roentgenologic examination reveals discrete, nodular fibrosis throughout the lungs. Roentgen examination of the patient with silicosis may also reveal large areas of increased density in the lungs, as was true in the present case. According to Gardner<sup>1</sup> these shadows may be due either to conglomerate lesions of uncomplicated silicosis or to silico-tuberculosis. Differentiation of the two may be extremely difficult.

In the early stages of silicosis the patient appears well and has few or no complaints. When symptoms develop they consist most commonly of dyspnea, cough, and susceptibility to infections of the upper respiratory tract. Dyspnea on exertion frequently precedes all other symptoms by a considerable length of time and usually dominates the clinical picture, progressing gradually in severity until the patient is

## SILICOSIS

prevented from carrying on any work. The cough is usually unproductive although exceptions to this are not rare. Fever and loss of weight are seldom present in uncomplicated cases; when they do occur they usually are the result of tuberculosis or some other complicating disease of the respiratory tract. Physical examination is of little assistance in diagnosis although more or less marked limitation of the respiratory movements of the thorax is present and the breath sounds may be greatly diminished.

Perhaps the two most important clinical features of silicosis are its tendency to progress even though the patient is removed from a dusty occupation and the great frequency with which the disease is complicated by pulmonary tuberculosis. Tuberculosis is by far the most common cause of death in patients with silicosis, and once evidence of tuberculosis appears, the illness usually runs a rapid course.

The case history summarized above illustrates a number of the most important features of silicosis, including the roentgenologic aspects of the disease, the symptomatology, and the prolonged, slowly progressive course in spite of removal from exposure to silica dust. A diagnosis of complicating pulmonary tuberculosis could not be substantiated in this patient, and it is our opinion that the larger shadows in the lungs were due to conglomerate lesions of simple silicosis. Repeated examinations will be necessary, however, before a final decision upon this point can be made.

## REFERENCE

1. Gardner, LeRoy U.: The diagnosis of silicosis, with special reference to roentgenological manifestations, *Ann. Int. Med.*, 10:166-173, (August) 1936.