

A CASE ILLUSTRATING THE ANALOGY BETWEEN ESSENTIAL HYPERTENSION AND RAYNAUD'S AND BUERGER'S DISEASE

GEORGE CRILE, M.D.

The patient was a man, 42 years of age, who was admitted to the Cleveland Clinic, April 30, 1937, with the complaint of pain in the fingers and toes of 15 years' duration. In addition to the pain, he had had numbness and tingling in his fingers. The symptoms were intermittent, but progressive in nature, so that he had been unable to work for five years. For three and one-half years, he had had severe paroxysmal pain in the finger tips which felt "glassy" and were very sensitive to pressure. He had resorted to morphine for relief of the pain. He stated that his fingers would become white, then red, and then blue, and that they were "ice cold" at times, even in hot weather. Partial relief could be obtained by plunging the hands into cool water. Exposure to cold produced numbness and a loss of sensation in both the hands and the feet. Because of gangrene, the right middle finger had been amputated in 1934 and the left middle finger in February, 1937. The patient is of Irish descent.

There was nothing of significance in the past history. Physical examination revealed a well developed male who was fairly nourished; height 67 inches, weight 153 pounds. The temperature and pulse were normal. The blood pressure in millimeters of mercury was 120 systolic, 70 diastolic. The skin over the hands and feet was moderately flushed, shiny, and somewhat atrophic. There were patchy areas of brownish pigmentation over the feet, ankles, and lower legs. The middle finger of each hand had been amputated (Fig. 1).

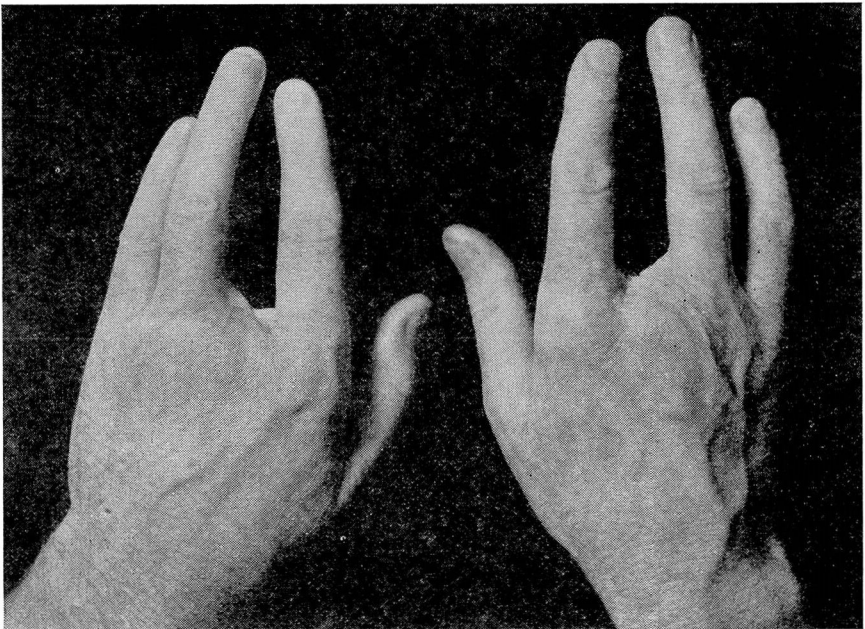


FIGURE 1: Photograph of patient's hands.

ESSENTIAL HYPERTENSION, RAYNAUD'S AND BUERGER'S DISEASE

The radial pulses were of fair volume. The dorsalis pedis pulse was barely palpable in the right foot and was not palpable in the left. The posterior tibial pulse was not palpable in either foot. Popliteal pulsations were present on both sides.

The laboratory findings were as follows: urinalyses, negative; blood count, 3,700,000 red blood cells, 6,300 white blood cells; hemoglobin, 84 per cent; fasting blood sugar, 66 mg. per hundred cubic centimeters; blood urea, 33 mg. per hundred cubic centimeters; the blood Wassermann and Kahn tests both gave negative results.

A diagnosis of Raynaud's disease was made.

A left celiac ganglionectomy, division of the remaining nerve supply to the adrenal gland, and division of the lumbar sympathetic chain were performed May 3, 1937. The ganglion weighed 1010 mg.; the average normal weight of the left celiac ganglion in the male is about 340 mg.

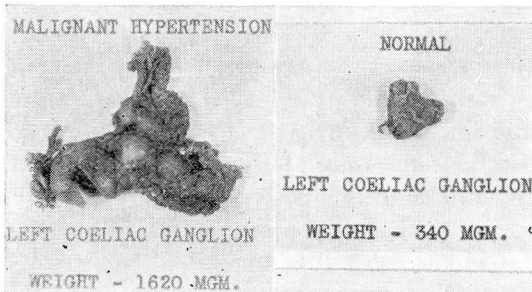


FIGURE 2: Celiac ganglion in case of essential hypertension.

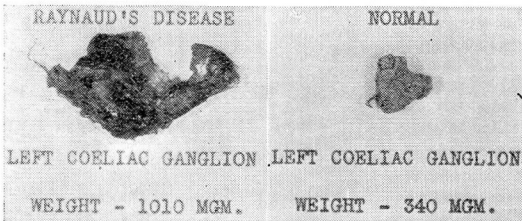


FIGURE 3: Celiac ganglion in case of Raynaud's disease.

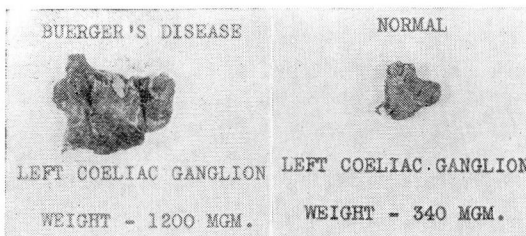


FIGURE 4: Celiac ganglion in case of Buerger's disease.

GEORGE CRILE

Immediately after the operation, the pain disappeared from the extremities and they were no longer sensitive to pressure. Examination of the hands and feet on the day of the operation showed them to be warm, pink, and dry. The skin temperature of the extremities was taken repeatedly by Dr. Zeiter under controlled conditions and showed a more constant elevation than was present before the operation, the average readings being about one to one and one-half degrees higher.

A right celiac ganglionectomy and division of the splanchnic nerves was performed May 17, 1937, and was followed by a good recovery. The ganglion on this side weighed 535 mg.

The skin temperatures have been more constantly elevated with less variation since the second operation. There has also been a marked change in the general appearance and disposition of the patient since he has been relieved of his pain and anxiety.

Comment: In this case, complete relief from the symptoms of Raynaud's disease occurred almost simultaneously with the completion of the first operation. This relief has endured for a period of six weeks. The left ganglion was approximately 300 per cent heavier than the average normal ganglion. The analogy between the hypertrophy of the thyroid gland in hyperthyroidism and the hypertrophy of the celiac ganglion in essential hypertension (Fig. 2), Raynaud's disease (Fig. 3), and Buerger's disease (Fig. 4), and the fact that in many cases of hypertension immediate relief follows celiac ganglionectomy make it seem worth while to call attention to the possibility of attacking Raynaud's disease and Buerger's disease by excision of the celiac ganglion. This operation has been performed in a case of Buerger's disease in which relief has already persisted for a period of three months. In this case, the left celiac ganglion weighed 1200 milligrams.

The reason for reporting a case in which operation was so recently performed is to call attention to this analogy between hypertension and Raynaud's disease. In cases of hypertension, the beneficial results of celiac ganglionectomy have already persisted for periods of more than a year. The permanence of the result in this case remains to be disclosed.