

GASTRO-INTESTINAL MANIFESTATIONS OF CARDIOVASCULAR DISEASE

A. CARLTON ERNSTENE, M.D.

Symptoms referable to the gastro-intestinal tract frequently are present in patients with cardiovascular disease and at times are of such prominence that they dominate the clinical picture. Since their misinterpretation may lead to serious errors in diagnosis, proper understanding of the mechanism of their production is of considerable importance. It will be the purpose of this communication to review the pathogenesis of the gastro-intestinal manifestations of cardiovascular disease and to point out the manner in which the correct evaluation of accompanying symptoms and signs will assist in differential diagnosis.

DYSPHAGIA

Dysphagia is an unusual symptom of cardiovascular disease but occasionally it occurs as the result of pressure upon the esophagus by an aortic aneurysm or a greatly enlarged left auricle. Less frequently it is produced by pressure from a large pericardial effusion.

The esophagus is situated in close anatomical relationship to both the aortic arch and the descending aorta, and an aneurysm in either of these portions may exert considerable pressure upon it. Recognition of the cause of the resulting dysphagia is seldom difficult. Aneurysms of the aortic arch may be accompanied by inequality of the pupils, venous congestion of the head and neck, a tracheal tug, dyspnea, disturbances in phonation, and inequality of the radial pulse wave and brachial blood pressure in the two arms. Aneurysms of the descending aorta frequently cause severe pain from pressure upon the spine and nerve roots, and at times they may be responsible for cough and expectoration due to pressure upon the left main bronchus. Roentgen examination of the chest establishes the diagnosis, but it is to be remembered that in ordinary anteroposterior films an aneurysm of the descending aorta may be completely concealed by the cardiac shadow. Radiological study of the heart, therefore, should always include a film taken in the right oblique diameter as well as fluoroscopic examination, and in all individuals in whom dysphagia is present, studies of the esophagus should be made after the administration of thin barium paste.

In patients with mitral valve disease (stenosis, insufficiency, or both) the left auricle is the first chamber of the heart to become enlarged. This enlargement alone may cause very little change in the size of the heart as seen in the anteroposterior diameter, although there usually is an associated prominence of the pulmonary conus. The posterior surface of the heart is comprised principally of the left

auricle, even moderate enlargement of which results in projection of the auricle into the retrocardiac space. The anterior wall of the esophagus normally is in contact with the posterior surface of the heart. Enlargement of the left auricle, therefore, causes displacement backward and occasionally rather sharp angulation of the esophagus. If the auricular enlargement is extensive, the pressure exerted upon the esophagus may result in marked dysphagia, as illustrated in the following case report.

Case 1: The patient, a white married woman, aged 54 years, was admitted to the Clinic on January 6, 1933 because of dyspnea on exertion, difficulty in swallowing, and prominence of the veins of the neck and upper chest. The past medical history was irrelevant except for pneumonia at the age of 19 years, at which time the patient had been ill for three months. In March 1932 fatigability and dyspnea on walking rapidly were first noted. These symptoms increased gradually in severity, and after two months a persistent, slightly productive cough and edema of the ankles developed. Approximately three months before her admission to the Clinic, the patient noted the onset of difficulty in swallowing liquids. Solid food caused no trouble, but every attempt to take liquids resulted in at least partial regurgitation, either immediately or within a few minutes. One month after the appearance of dysphagia, the veins over the neck and chest became prominent and this had increased progressively.

Physical examination revealed a poorly nourished individual who experienced definite dyspnea while at rest. The lips and nail beds were cyanotic. The veins in both sides of the neck, both temporal regions, the anterior wall of the chest, and in the arms were tortuous and engorged. When the patient coughed, a number of small tortuous veins also became visible over the upper back. The heart was considerably enlarged to percussion; its rhythm was regular and the rate 120 per minute. A harsh systolic murmur was heard over the apex, but no diastolic element could be made out. The arterial blood pressure was 122 mm. systolic and 90 mm. diastolic and was the same in both arms. The percussion note was impaired over the base of the right lung and the breath sounds were diminished over this area. A few medium moist râles were heard over the base of both lungs. The liver extended 6 cm. below the costal margin in the midclavicular line and was moderately tender. Slight edema was present over both lower legs. Urinalysis and blood counts revealed nothing of significance. The Wassermann and Kahn reactions of the blood were negative.

An electrocardiogram showed auricular flutter with 2:1 block. Roentgenograms of the chest in the anteroposterior diameter revealed enlargement of the heart with calcific deposits in the pericardium (Fig. 1). Films taken in the oblique diameter after the administration of barium paste by mouth showed obstruction of the esophagus due to pressure from an enlarged left auricle (Fig. 2). Fluoroscopic examination revealed greatly diminished cardiac pulsations.

It is of considerable interest that with absolute rest in bed and the administration of digitalis, the patient's dysphagia disappeared entirely within one week.

ANOREXIA, NAUSEA, AND VOMITING

Anorexia is a common symptom in patients who have slight or moderate congestive heart failure, and in individuals with advanced

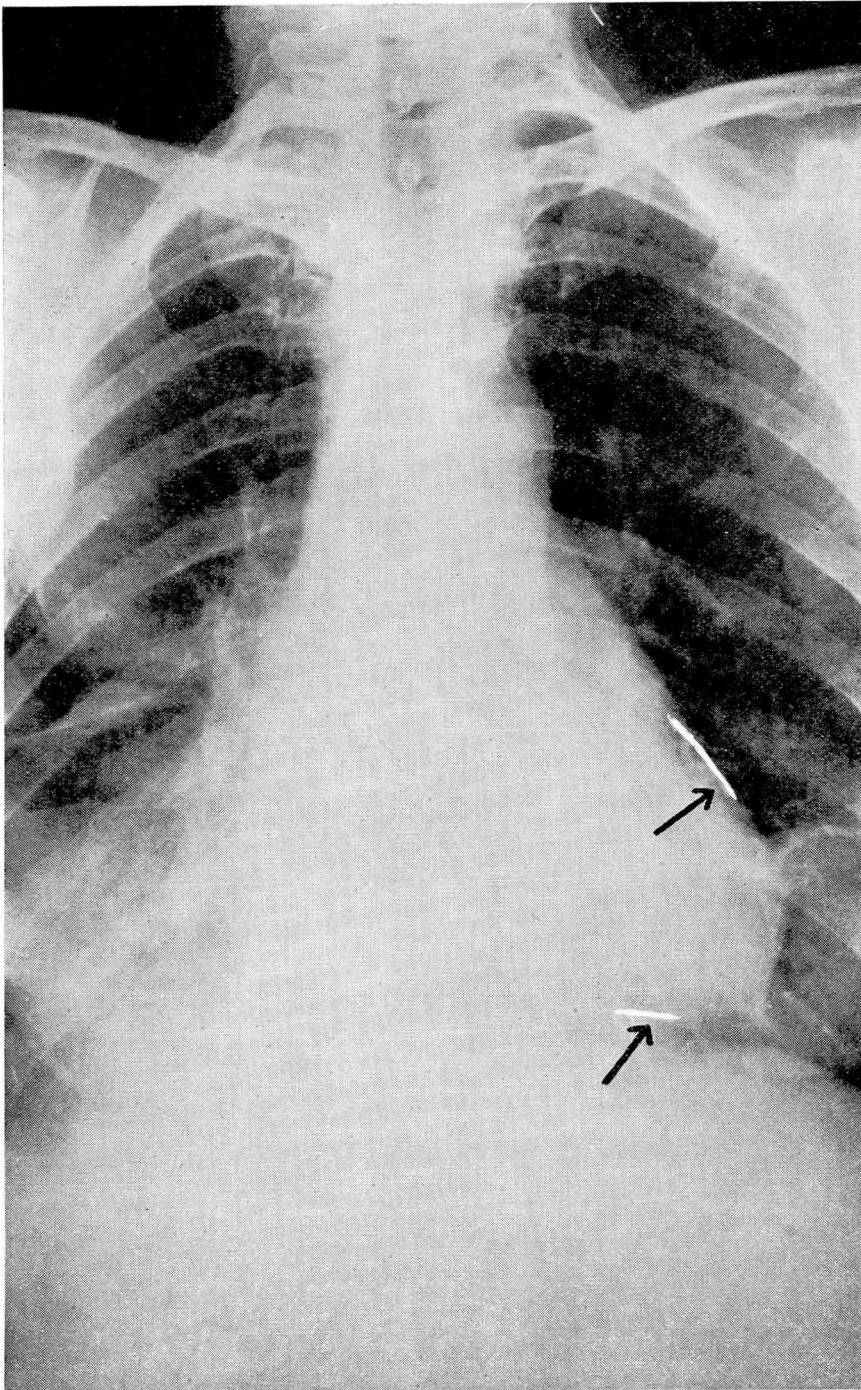


FIGURE 1: Case 1: Anteroposterior view showing enlargement of heart and calcified areas in the pericardium. (The areas of calcification have been retouched to show their location more clearly.)

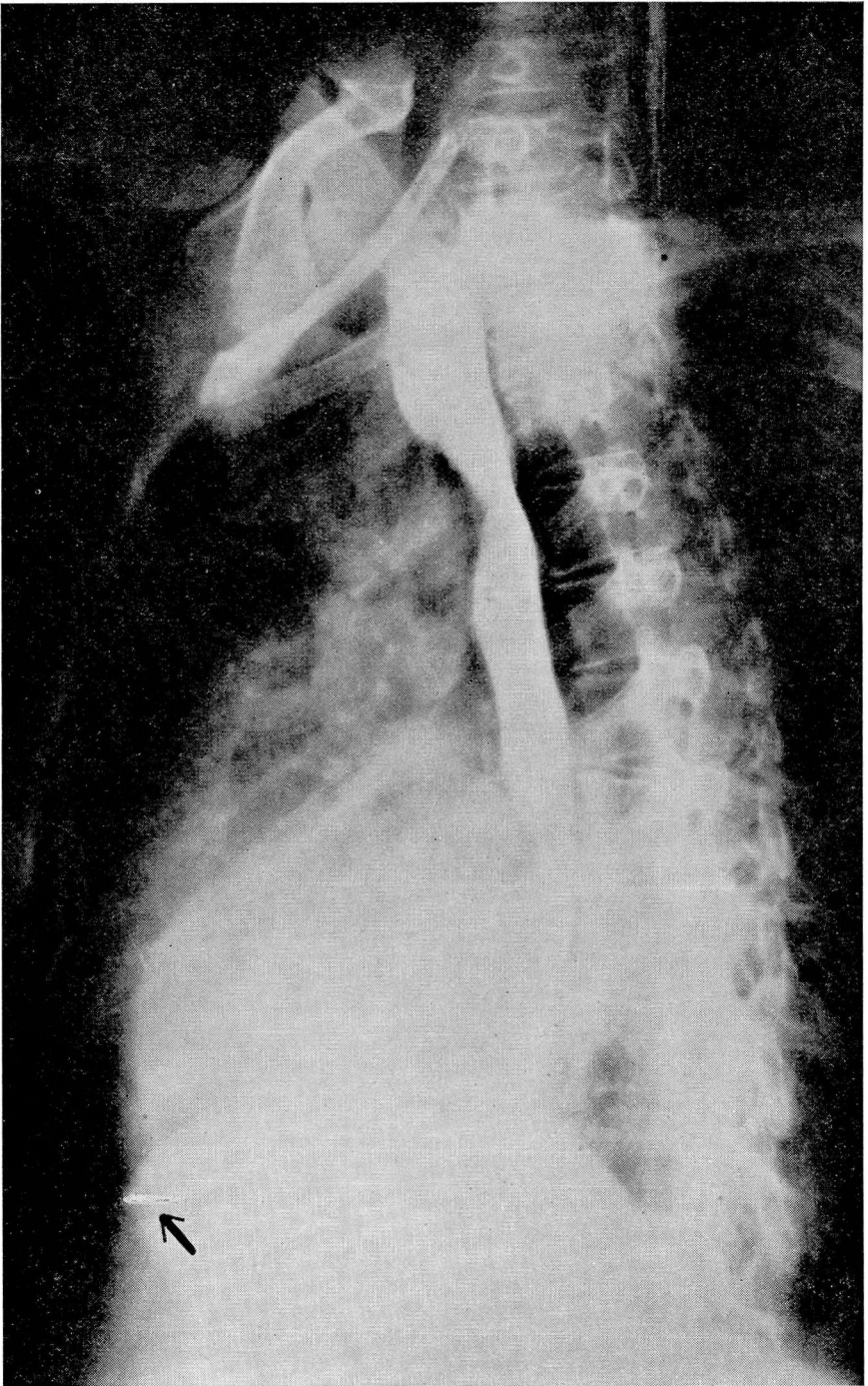


FIGURE 2: Case 1: Oblique view showing calcified area in pericardium and compression of the esophagus. (The areas of calcification have been retouched to show their location more clearly.)

failure there often is persistent nausea and repeated vomiting. In addition, many patients with congestive failure complain severely of flatulence. At times these symptoms may be of sufficient prominence and so far out of proportion to such symptoms as dyspnea and cough that a diagnosis of some form of primary gastro-intestinal disease is suggested. The symptoms are due to passive congestion of the gastric and intestinal mucosa and of the liver. Careful physical examination usually leads to proper interpretation of the patient's complaints. The heart is usually enlarged and its rhythm frequently is irregular. There generally is evidence of more or less extensive passive congestion of the lungs. The jugular veins are engorged and remain distended even when the patient is propped up in bed; the liver is enlarged and tender, and there is a variable degree of edema of the legs and over the lower back.

Not infrequently a patient with congestive heart failure is first seen only after he has been under the care of another physician for some time. The patient may or may not know what medication he has been receiving, and the question arises whether the anorexia, nausea, and vomiting have resulted from overdosage with digitalis. Fortunately, there are a number of points in the history and physical examination that usually enable one to make an accurate decision. In the first place, a description by the patient of the medicines he has taken and the dosages may be helpful. Secondly, if the patient has received sufficient digitalis to produce toxic symptoms he usually will report that there was decided improvement in the symptoms of myocardial failure after he began to take medicine and before anorexia or nausea and vomiting developed. If auricular fibrillation is present and the ventricular rate is very rapid, one may safely conclude that the patient has not had too much digitalis while the same arrhythmia with a ventricular rate of 60 or less suggests that large amounts of digitalis have been given. Frequent premature beats and especially bigeminal rhythm due to regularly recurring premature beats also increase the probability of digitalis overdosage. In general, however, it will be found that in the individual who presents objective evidence of congestive heart failure, anorexia, or nausea and vomiting are the result of heart failure rather than digitalis intoxication. Under such circumstances the administration of more digitalis often results in prompt and complete relief from the gastro-intestinal symptoms.

A sensation of distention or gas in the upper abdomen is a not infrequent complaint of individuals with coronary artery sclerosis, and occasionally repeated attacks of nausea and vomiting constitute one of the chief symptoms of the disease. Symptoms of this kind often cause the patient to diagnose his condition as "indigestion," but careful

questioning and thorough physical examination usually reveal things in their proper light. In all but the exceptional case, a history of relationship between the appearance of symptoms and exertion or emotional upsets will be present. Many patients will have observed that although even moderate activity soon after eating will cause symptoms, all discomfort can be avoided by limiting the size of the meal and by resting after eating. Furthermore, although there may be no actual pain in the substernal area during the time that symptoms are present, there almost always is at least a sensation of fullness, pressure, or gas in this location. Rest usually affords prompt relief from the symptoms, and vomiting, when it occurs, has a similar effect. Nitroglycerine also has a specific effect. On examination, the heart may or may not be enlarged, and its rhythm usually is regular. The arterial blood pressure frequently is elevated, and electrocardiograms often reveal evidence of coronary artery disease.

The following case report illustrates the manner in which vomiting may comprise an important part of the symptomatology of coronary artery disease.

Case 2: A white man, a musician, aged 68 years, was first seen on December 19, 1935, because of attacks of severe pain or pressure in the upper substernal area accompanied at times by forceful, almost projectile vomiting without preceding nausea. The first seizure had occurred one month earlier, and four of the five attacks that had been experienced had been brought on by exertion. In two attacks, relief had been obtained by resting for a few minutes, but in the other three the pain had persisted until the sudden onset of vomiting about thirty minutes later. All seizures had been accompanied by moderate dyspnea. There had been no radiation of the pain from its upper retrosternal location.

Physical examination revealed a well developed, well nourished, anxious individual. The pupils were equal, regular, and reacted normally. The heart was not enlarged, and its rate and rhythm were normal. There were no murmurs. The peripheral arteries showed advanced diffuse sclerosis, and the blood pressure was 192 mm. systolic and 104 mm. diastolic. The lungs were clear on percussion and auscultation. Abdominal examination revealed no areas of tenderness and no palpable masses or solid organs.

The three conventional leads of the electrocardiogram showed no evidence of myocardial damage but in precordial leads, the T waves were upright. Roentgen examination of the thorax revealed no evidence of pathologic change in the heart, aorta, or lungs. Roentgen examination of the gastro-intestinal tract also gave normal findings. Examination of the gastric contents after the administration of an Ewald meal showed normal concentrations of free and total acid. It was concluded, therefore, that the vomiting was due directly to coronary artery disease.

In spite of medication and a prolonged period of rest in bed with subsequent strict limitation of activity, the attacks of pain continued to occur with increasing frequency, and developed more and more often while the patient was at rest. Many nocturnal seizures were experienced. Nitroglycerine never failed to give relief within a few minutes, but if for some reason nitroglycerine was not

GASTRO-INTESTINAL MANIFESTATIONS CARDIOVASCULAR DISEASE

taken, almost explosive vomiting usually occurred within one-half hour and brought the attack to an end. The patient died on May 15, 1936, two hours after the onset of symptoms of acute coronary occlusion.

Nausea and vomiting often develop soon after the onset of acute coronary artery occlusion. Pain, however, is the outstanding symptom, and the differentiation between coronary occlusion and upper abdominal disease will be discussed from this viewpoint later.

JAUNDICE

The bilirubin content of the blood is increased in practically all cases of congestive heart failure, and occasionally this increase is sufficient to produce visible jaundice. Icterus, when it occurs, is the result of two factors. The first of these is depression of the excretory function of the liver due to the anoxemia which results from passive congestion. The second is increased production of bilirubin as evidenced by its increased concentration in the blood and its increased excretion as urobilin in the stools and urine.

Passive congestion of the liver due to causes other than myocardial failure may also result in the appearance of icterus. Extensive pericardial effusion, for example, is accompanied by increased peripheral venous pressure, congestion of the viscera, and occasionally by jaundice.

When jaundice develops quickly in patients with congestive heart failure, or rapidly becomes more intense after having been present for some time, the change is usually due to pulmonary infarction. Infarction of the lung causes a sudden increase in the degree of anoxemia of the liver and reduces the already impaired excretory function of the hepatic cells. In many instances, the increased anoxemia causes actual necrosis of the liver cells in the center of the lobules.

The following case report illustrates the occurrence of jaundice in congestive heart failure with rapid intensification due to pulmonary infarction.

Case 3: The patient was a white male, forty-six years of age, who had had chronic cough and dyspnea on exertion for ten years. During the week before admission to the hospital these symptoms had increased and edema of the legs had been present. On physical examination, there was orthopnea, moderate cyanosis, and slight jaundice. The heart was enlarged with systolic and diastolic murmurs at the apex. Auricular fibrillation was present. There were signs of congestion at the base of both lungs and of consolidation in the left midchest posteriorly. The liver extended almost to the level of the umbilicus, and there was edema of the legs and over the lower back.

During the first two days in the hospital, the jaundice increased greatly. Then for twelve days it gradually diminished as the patient's general condition improved. On the fourteenth day, however, there was an abrupt increase in dyspnea and cyanosis, and on the following day the jaundice was noted to be much more intense. There had been no cough, pain in the chest, or hemoptysis,

and examination of the chest revealed no significant changes in the physical findings. The patient became comatose and died two days later. During the entire period of observation, bilirubin had been present in the urine, but the stools had been of normal color.

Necropsy confirmed the diagnosis of rheumatic heart disease with mitral stenosis. The liver was enlarged and congested and showed necrosis of the central cells of the lobules in microscopic sections. The major portion of the cavity of the left auricle was occupied by a large, grayish-red, friable thrombus, and the lumen of the right inferior pulmonary vein was occluded by an attached thrombus which extended peripherally for a considerable distance along its tributaries. The lower lobe of the right lung was completely infarcted; it was deep red in color and of a firm, rubbery consistency throughout. Scattered through the remainder of the lungs were many areas of thrombotic infarction, ranging from a few millimeters to 5 or more centimeters in diameter. There were no areas of pneumonia.

Prolonged febrile illnesses which are accompanied by the development of severe anemia cause atrophy of the central hepatic cells and depress the excretory function of the liver. At the same time, the increased destruction of red blood cells results in a considerable increase in bilirubin production, and jaundice may therefore appear. In sub-acute bacterial endocarditis, the skin often has a diffuse, yellowish-brown color to which the term "café au lait" is applied. Occasionally, if the disease is accompanied by sufficiently severe anemia, the skin and sclera becomes definitely icteric.

Jaundice occasionally develops within the first two or three days after the occurrence of acute coronary occlusion. Usually the icterus is of only slight degree but at times it becomes quite deep. The liver is generally enlarged and tender, and in all probability the development of jaundice is to be explained as a result of anoxemia of the hepatic cells.

ABDOMINAL PAIN

A number of cardiovascular conditions may cause abdominal pain. Patients with advanced congestive heart failure often complain of discomfort or actual pain in the epigastrium and right upper quadrant of the abdomen due to the presence of an enlarged, congested liver. Recognition of the cause of the symptoms is a simple matter under such circumstances, and in favorable cases the institution of proper treatment results in prompt relief.

Although the pain of angina pectoris is typically retrosternal in location, it may occasionally be situated in the epigastrium. In general the differentiation of pain of this kind from that due to abdominal disease is not difficult. The relation of the pain of angina pectoris to exertion and its prompt subsidence with rest is of fundamental importance. Furthermore, although the pain may not spread beyond its epigastric location if the patient becomes inactive with the first appearance of dis-

GASTRO-INTESTINAL MANIFESTATIONS CARDIOVASCULAR DISEASE

comfort, it is much more common to have some radiation to the retrosternal area or at least an accompanying sensation of fullness, pressure, or tightness in this region. Physical examination in the patient with angina pectoris may reveal nothing of diagnostic significance, and the electrocardiogram may also fail to help. The ultimate diagnosis, therefore, must often be based upon a careful analysis of the patient's symptoms.

Early writers on coronary thrombosis directed attention to the fact that the disease might closely simulate surgical conditions in the upper abdomen, and the possibility of erroneously attributing the symptoms of coronary occlusion to upper abdominal disease has since been emphasized repeatedly. The pain of coronary thrombosis may be situated entirely in the upper abdomen for several hours, and on examination there may be muscle spasm and tenderness in the epigastrium or right upper quadrant. These findings and the occurrence of fever, leukocytosis, vomiting and at times jaundice may very strongly suggest biliary colic, perforated peptic ulcer, acute intestinal obstruction, or acute pancreatitis. An error in diagnosis usually can be avoided, however, by careful attention to the clinical history and to other points in the general physical examination. A large proportion of patients who have coronary thrombosis have had earlier attacks of typical angina pectoris, and in others there will be a history of "indigestion" on effort. The pain of coronary occlusion usually is accompanied by dyspnea while dyspnea is not commonly present in patients who have acute surgical conditions in the abdomen. Furthermore, although the pain of coronary thrombosis may be confined to the epigastrium for several hours, it is much more common to have at least some spread to the retrosternal area within a short time of its onset. Radiation of this kind does not occur in abdominal disease. Physical examination soon after the onset of coronary thrombosis frequently reveals great weakness of the heart tones, and gallop rhythm is often present. Pulsus alternans may be detected while recording the blood pressure, and in patients with extensive cardiac infarction, râles may appear over the base of the lungs within a very short time. A pericardial friction rub is detected in 10 or 15 per cent of all patients with myocardial infarction and usually develops within one to three days after the onset of symptoms. Its occurrence in patients who have experienced symptoms that might be due to coronary thrombosis furnishes a valuable diagnostic sign. Finally, the electrocardiogram may show pathognomonic evidence of coronary occlusion within a few hours of the onset of symptoms.

A few words of caution might well be introduced at this place. In the past, in discussions of the differential diagnosis of angina pectoris and coronary occlusion, emphasis has been placed almost entirely upon the

fact that these conditions may closely simulate upper abdominal disease. Of late, however, a few observers have pointed out the possibility that errors may be made in the reverse direction and have reported cases in which symptoms due to gallbladder disease, perforated peptic ulcer, or diaphragmatic hernia suggested coronary artery disease. In the great majority of cases, the presence of angina pectoris or coronary thrombosis is correctly recognized, but as the result of the popularity of these diagnoses, other diseases with similar symptoms undoubtedly are being included at times under the same classifications. Although such errors are not common, they are of importance because of their bearing on prognosis and treatment.

There are a few other cardiovascular conditions which may cause severe abdominal pain. Chief among these are aneurysm of the abdominal aorta and infarction of the kidneys, spleen, or mesentery due to emboli from the heart. Aneurysm of the abdominal aorta is of rare occurrence but may cause pain, usually constant and boring in character and often very severe, due to pressure upon the spine and nerve roots. The two most common cardiac conditions which may be complicated by embolic infarction of abdominal structures are bacterial endocarditis with the development of large friable vegetations upon the heart valves and endocardium, and coronary occlusion with infarction of the heart and the secondary formation of a mural thrombus over the endocardial surface of the myocardial infarct. Occasionally also, embolic accidents occur in patients with mitral stenosis and auricular fibrillation. In these patients the auricular appendages often contain thrombotic material, portions of which may be broken off and lodge in any part of the pulmonary or systemic circulation.

Infarction of the spleen, kidneys, or mesentery complicating bacterial endocarditis seldom causes confusion in diagnosis. The history of a febrile illness of variable duration, the occurrence of petechiae in the skin or conjunctivae and the presence of cardiac murmurs generally lead to prompt recognition of the primary condition, and the obtaining of a positive blood culture establishes the diagnosis beyond doubt. Embolic accidents which complicate coronary occlusion occur most commonly during the second week after the attack but may occur up to the sixth or eighth week. Under unusual circumstances it may happen that the symptoms of coronary occlusion are of such mildness that their significance is not appreciated by the patient or the physician. The development of severe abdominal pain at some time during the following few weeks may then present a difficult problem and may lead to an erroneous diagnosis of acute intestinal obstruction, acute pancreatitis, or perforated peptic ulcer. A careful review of the clinical history, however, should enable one to avoid such a mistake. Embolic accidents

GASTRO-INTESTINAL MANIFESTATIONS CARDIOVASCULAR DISEASE

which occur in patients with mitral stenosis and auricular fibrillation seldom offer difficulty in diagnosis if the possibility of this complication is kept in mind.

SUMMARY

Dysphagia, anorexia, nausea, vomiting, jaundice, and abdominal pain are not infrequently due to cardiovascular disease. Dysphagia due to compression of the esophagus may result from aneurysm of the aorta, marked enlargement of the left auricle in mitral valve disease, or extensive pericardial effusion. Anorexia, nausea, and vomiting are common manifestations of congestive myocardial failure and are due to congestion of the liver and the mucosa of the stomach and intestinal tract. Nausea and vomiting may also constitute a prominent symptom of coronary artery disease and especially acute coronary artery occlusion. Jaundice in patients with heart disease is the result of anoxemia of the liver cells and may occur in congestive heart failure, coronary thrombosis, and occasionally in subacute bacterial endocarditis. Abdominal pain due to congestion of the liver is present in many patients with congestive heart failure, while in angina pectoris and coronary occlusion the pain may be confined entirely to the upper abdomen. Severe abdominal pain may also result from an aneurysm of the abdominal aorta and from infarction of the spleen, kidneys, or mesentery due to emboli which arise from the vegetations of bacterial endocarditis, a mural thrombus secondary to myocardial infarction, or from thrombi in the left auricular appendage in patients with mitral stenosis and auricular fibrillation. While, at times, any of these symptoms may sufficiently dominate the clinical picture to suggest primary gastro-intestinal disease, attention to the details of the clinical history and a thorough physical examination usually enable one to make a correct diagnosis.