

TUMORS OF THE SPINAL CORD

A. T. BUNTS, M. D.

Although not common, primary tumors involving the spinal cord merit consideration for two important clinical reasons: In diagnosis they are often mistaken for other more common conditions, with consequent errors in treatment and serious results due to delayed surgical intervention. In our experience¹, about 50 per cent of these tumors prove to be of such a nature that they may be removed completely and a favorable prognosis given as regards life and restoration of normal function.

Any part of the spine or of the contents of the spinal canal may be the site of origin of a neoplasm. Various types of bone tumors and cartilaginous tumors may arise from the vertebrae and intervertebral disks and cause compression of the spinal nerve roots or of the spinal cord. Lipoma or sarcoma of the epidural connective tissue may occur. Angiomatous tumors may arise from extradural blood vessels or from those of the cord itself. The most common primary tumors are the neurofibroma which arises from the spinal nerve roots, the meningioma which arises from the meninges, and the glioma originating in the glial tissue of the spinal cord. Other less common tumors are the congenital dermoid and the pigmented nevus. Metastatic lesions from primary malignant tumors in other parts of the body may lodge in the spine and give rise to symptoms simulating those of primary spinal cord tumor. These, therefore, must be considered also in differential diagnosis. The breast, the prostate, and the kidney (hypernephroma) are the most common primary sites for such neoplasms.

The symptoms of spinal cord tumor are the result of involvement of sensory or motor nerve roots or of the cord itself. Inasmuch as the cord and its nerve roots lie within the spinal canal from the foramen magnum to the lower end of the spine, it is evident that symptoms may be referred to any part of the body, except to the anterior half of the head. In adults, the spinal cord terminates at the level of the lower end of the first lumbar vertebra, below which the spinal canal contains the long nerve strands, so grouped as to merit the descriptive name of "horse's tail." Tumors of the cauda equina, therefore, give rise to symptoms of involvement of the lumbar and sacral nerves but not to symptoms of compression of the spinal cord.

Pain, disturbances of sensation, disorders of motion in the legs or arms, and dysfunction of the vesical and anal sphincters are the chief symptoms caused by spinal cord tumors. Any of these symptoms may occur independently of the others or in association with one or more of

the others. Pain is the earliest and most common symptom of spinal cord tumor and may be present for many months or even for several years before symptoms of compression of the cord ensue. This is particularly true in the case of the slow-growing, benign, extramedullary tumors, such as the neurofibroma and the meningioma. By irritation of sensory nerve roots, such tumors give rise to pain which may be referred along the course of distribution of the nerve. This so-called "root pain" is often severe and may be mistaken for the pain of angina pectoris, intercostal neuralgia, neuritis, arthritis of the spine and sacro-iliac joints, gallstones, renal and ureteral stones, lesions of the gastro-intestinal tract, and "sciatica." In some instances, needless abdominal and pelvic operations have been performed for the relief of pain caused by spinal cord tumors. Pain may also occur in the spine at the site of the tumor and is often more noticeable at night. Sneezing, coughing, or straining at stool may increase the pain caused by a spinal cord tumor.

Progressive alterations in motor and sensory functions accompany the growth of a tumor as it produces compression of the spinal cord. The more common clinical manifestations are difficulty in gait, weakness and spasticity of the legs due to changes in the pyramidal tracts of the cord, and numbness or paresthesiae of the legs and trunk due to involvement of the sensory tracts of the cord. Obviously, if the tumor is located in the cervical region, it may give rise to similar phenomena in the arms in addition to those in the lower extremities.

Control of the anal and vesical sphincters may be disturbed in the presence of spinal cord tumors, and impotence or inability to ejaculate may occur in man. These phenomena are observed commonly in cases of intramedullary tumor and tumor involving the conus medullaris at the lower end of the cord and the cauda equina.

Diagnosis: After a thorough general physical examination has been made, together with routine blood counts, blood Wassermann reaction, and urinalysis, the following procedures are of major importance in the study of a patient who is suspected of harboring a tumor of the spinal cord.

1. Neurological examination.
2. Roentgenograms of the spine.
3. Lumbar puncture and Queckenstedt's test, including examination of the cerebrospinal fluid.

Neurological examination may reveal weakness or spasticity of one or more extremities, hypesthesia or anesthesia of the skin, and changes in the tendon, abdominal, and cremasteric reflexes. Babinski's sign may be positive unilaterally or bilaterally and ankle clonus may be

TUMORS OF THE SPINAL CORD

present. A working knowledge of the segmental distribution of the spinal nerves is of great assistance in identifying the site of the tumor. The disclosure of a "sensory level," below which there is anesthesia or hypesthesia is immediately important in locating the exact position of the tumor in relation to the length of the cord. Acute flexion of the head on the chest or bilateral compression of the jugular veins as described by Jones and Naffziger² may reproduce the pain caused by a spinal cord tumor.

Anteroposterior and lateral roentgenograms of the spine should be taken in every case. Primary bone tumors and metastatic tumors of the vertebrae may produce characteristic changes in the films. Increased width of the spinal canal, narrowing of the pedicles and laminae, and enlargement of an intervertebral foramen may reveal the site of an intraspinal tumor.

The most important aids to diagnosis are lumbar puncture, Queckenstedt's test, and examination of the cerebrospinal fluid. Lumbar puncture is performed usually between the third and fourth lumbar vertebrae with the patient lying on his side. When fluid appears, its color is noted and a glass manometer is attached to the end of the needle. The height of the column of fluid in the manometer is recorded in millimeters as the initial pressure. The patient should be completely relaxed and free from apprehension during this measurement. The fluid below a cord tumor is often yellow or faintly straw-colored (xanthochromia). The arterial pulsations of the fluid in the manometer are observed. Below a tumor these pulsations are often minimal or absent. Queckenstedt's test is performed by compressing the jugular veins in the neck, either by hand or by application of a pneumatic pressure cuff. Normally, in the absence of spinal subarachnoid block, the increased intracranial pressure thus produced is immediately transmitted to the cerebrospinal fluid which promptly rises in the manometer. On release of jugular compression, the column of fluid falls to its initial level. In the presence of a tumor obstructing the free flow of cerebrospinal fluid through the spinal subarachnoid space, Queckenstedt's test results in no rise or a slow, incomplete rise of the fluid in the manometer. A complete or partial spinal subarachnoid block, as shown by this test, occurs in more than 90 per cent of cases of spinal cord tumor. A "dry tap," a "bloody tap," or severe pain may occur in the presence of a tumor of the cauda equina. When obtainable, 5 cc. of fluid are removed for examination. Lumbar puncture may be followed by an increase in all the symptoms and signs of the tumor. Examination then may show a definite "sensory level" which previously was not clear.

A determination of the cell count, of globulin and total protein content, and the Wassermann reaction of the cerebrospinal fluid are made.

The cell count is rarely abnormal and the amount of globulin and total protein is almost always increased in cases of spinal cord tumor.

When the level of the tumor cannot be determined accurately by neurologic examination, it is helpful to inject 1 cc. of heavy lipiodol into the cisterna magna. Then, with the patient lying on a tilting table, under the fluoroscope, the descent of the oil is observed. The lipiodol is completely or partially blocked by a tumor obstructing the spinal subarachnoid space. At times, the major portion of the mass of oil may be arrested above a tumor and a thin stream of oil may be seen to "squeeze" past the tumor very slowly. Roentgen films of the site of obstruction are made so that the laminectomy may be planned to expose the tumor with accuracy.

In addition to the previously mentioned conditions which may simulate "root pain," many diseases of the spinal cord must be considered in differential diagnosis. Among these are the following: tabes dorsalis, multiple sclerosis, subacute combined degeneration of the cord associated with pernicious anemia, deficiency disease, syringomyelia, arteriosclerosis of the spinal arteries, amyotrophic lateral sclerosis, involvement of the cord in Hodgkin's disease, cord compression in Pott's disease of the spine, and extradural pyogenic abscess.

The following case reports may help to give a more graphic picture of the clinical manifestations of spinal cord tumor:

Case 1: A healthy young man, 23 years of age, was referred to the Clinic February 19, 1935, by Dr. Macy Ginsburg, of Canton, Ohio, with a chief complaint of "backache." During the previous two years, the patient had had almost continuous lumbar backache, which had become more severe during the past five months. Occasionally, the pain radiated down the back of the left thigh and into the left calf. The lower back was quite stiff and could not be moved without severe pain. The patient was unable to cough or sneeze without experiencing severe pain. There was no numbness, loss of control of the sphincter, loss of potency, or weakness of the legs. No history of trauma could be elicited.

Neurological examination revealed marked limitation of all movements in the lower back, increased lumbar lordosis, severe pain and restricted movement on straight leg raising, no weakness or atrophy of the legs, sluggish abdominal reflexes, active cremasteric and anal reflexes, hyperesthesia to pin-prick over the lower lumbar area and over the buttocks. There was no anesthesia. The patellar and Achilles reflexes were active and there was a questionable Babinski's sign bilaterally.

In the Orthopedic Department, a tentative diagnosis of early ankylosing arthritis of the lumbar spine and sacro-iliac joints was made. Certainly the clinical picture thus far warranted such a diagnosis. The diagnostic importance of lumbar puncture in such cases, however, was not forgotten. This procedure was carried out with some difficulty between the third and fourth lumbar vertebrae, and yellow, nonpulsating fluid was obtained at a pressure of 100 mm. of water (normal). Queckenstedt's test revealed a partial spinal

TUMORS OF THE SPINAL CORD

subarachnoid block and, after withdrawal of 6 cc. of fluid, the pressure fell to zero. The fluid coagulated on standing, thus signifying a high protein content. Examination of the fluid revealed 1 cell, globulin ++++, total protein 2000 mg. per 100 cc., negative Wassermann reaction, and negative colloidal gold curve.

A diagnosis of spinal cord tumor was made and, in order to locate it with accuracy, 1 cc. of lipiodol was introduced into the cisterna magna. Roentgen studies showed that its descent was arrested at the upper level of the body of the third lumbar vertebra.

On February 25, 1935, laminectomy of the second, third, and fourth lumbar vertebrae was performed and a neurofibroma of the cauda equina was found and removed (Fig. 1). The tumor was encapsulated and somewhat dumbbell

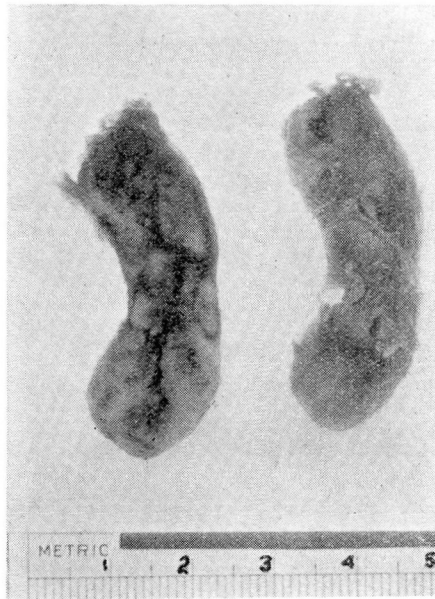


FIGURE 1: Cut surface of neurofibroma of the cauda equina.

shaped, with a moderate extradural extension through the intervertebral foramen between the fourth and fifth lumbar vertebrae on the left side.

After an uneventful recovery the patient was discharged from the hospital on the seventeenth day after operation. He was last observed on June 29, 1937, two years and four months following removal of the tumor. At that time, he had no pain in the back or legs and no difficulty in the movements of his spine. He had been working steadily. Examination revealed no neurological abnormality.

In this case a *tumor of the cauda equina simulated clinically an arthritic condition of the lumbar spine and sacro-iliac joints*. Lumbar puncture was the deciding factor in arriving at the true diagnosis. *In the following case, a spinal cord tumor simulated clinically a degenerative lesion of the cord*, and again lumbar puncture indicated the true nature of the condition.

A. T. BUNTS

Case 2: A 48 year old repair man was referred to the Clinic on November 13, 1933, by Dr. C. La Mont of Canton, Ohio. He complained chiefly of "numbness, burning, and drawing in the right leg." The lower back had been injured in an automobile accident in 1928. Roentgen films taken at that time showed no fracture of the spine. There was no paralysis. Two weeks later the patient returned to work. One year after the accident, he first noticed severe pain in the upper right lumbar region while coughing or while riding in his car over rough roads. In 1930, he began to have a burning sensation and numbness of the sole of the right foot and this gradually extended up to the right calf and to the anterior aspect of the right thigh during the next three years. Occasional, involuntary jerking movements of the right leg had occurred during the past six months, and the patient had walked with a limp, stumbling with the right foot during the past two years. He was unable to identify the position of the right foot without seeing it. During the month prior to examination at the Clinic, a sensation of numbness had developed in the sole of the left foot. There had been occasional incontinence of loose stools, but no incontinence of urine. Potency was good.

Neurological examination revealed diminished perception of all forms of sensation from the knees to the toes in both legs and feet. The right leg was weak and slightly spastic. Patellar and Achilles reflexes were hyperactive on both sides and Babinski's sign was positive bilaterally, but there was no clonus. The Romberg test gave a positive reaction. The gait was somewhat spastic.

In differential diagnosis the following conditions required consideration: multiple sclerosis, spinal cord tumor, subacute combined degeneration of the cord associated with pernicious anemia, and syphilis.

Routine blood examinations, including a Wassermann reaction, gave negative findings.

Roentgen examination of the spine was negative except for hypertrophic changes.

Lumbar puncture obtained clear, slightly yellow fluid at an initial pressure of 140 mm. of water (normal). There was a complete spinal subarachnoid block as shown by Queckenstedt's test. Examination of the cerebrospinal fluid thus obtained revealed 1 cell, a trace of globulin, total protein 200 mg. per 100 cc., negative Wassermann reaction, and negative colloidal gold curve.

It was then possible to make a diagnosis of spinal cord tumor by correlating the history, the neurological examination, the spinal subarachnoid block, and the high protein content of the cerebrospinal fluid. Inasmuch as the neurological examination failed to reveal a definite "sensory level" by which the tumor could be accurately localized, it was necessary to inject 1 cc. of lipiodol into the cisterna magna and then with the fluoroscope to follow its descent in the spinal canal. The lipiodol was arrested at the level of the ninth thoracic vertebra.

On November 23, 1933, laminectomy of the eighth, ninth, tenth, and eleventh thoracic vertebrae was carried out and a neurofibroma of a spinal nerve was found. The tumor was intradural and extramedullary, encapsulated, about 2 cm. long, compressing the right posterolateral aspect of the cord just beneath the lamina of the ninth thoracic vertebra. It was removed without great difficulty. Convalescence was uneventful except for a mild urinary infection which lasted for five days. The patient was in good condition when he was discharged from the hospital on the twenty-second postoperative day. At that

TUMORS OF THE SPINAL CORD

time he was walking without difficulty, sensation in the legs had returned to normal, and Babinski's sign had disappeared on both sides.

Two months after operation, the patient was working every day and walking without difficulty. Numbness had entirely disappeared and pain had not recurred. Neurological examination showed no abnormality five months after operation. On April 24, 1935, the patient again reported to the Clinic and expressed his good spirits and the normal motor function of his lower extremities by performing an intricate "tap dance" on the floor of the office. He last reported by mail on September 1, 1937, and stated that he was "feeling fine."

In the presence of a rapidly developing compression of the spinal cord, whether by fracture, by hemorrhage, or by tumor, the prognosis for return of normal motor function is usually poor. Such a condition existed in the following case which was the result of a solitary plasma cell myeloma of the spine. This type of lesion is somewhat rare and has been reported previously by Klemme³, Denker and Brock⁴, and Wakeley⁵.

Case 3: On July 4, 1936, a 42 year old man was seen in consultation with Dr. C. H. Hodgkinson and Dr. S. G. Foster at Oil City, Pennsylvania. The patient had enjoyed good general health until one month previously when he began to notice an intermittent, aching pain between the shoulder blades. One week prior to consultation, there had been a rapid development of weakness and numbness in both legs, and the patient was confined to bed because of inability to stand or walk. For one week, he had been unable to defecate and was obliged to resort to an enema.

Neurological examination revealed complete spastic paralysis of both legs, complete anesthesia caudal to the fifth rib, absent abdominal and cremasteric reflexes, and hyperactive patellar reflexes.

Lumbar puncture obtained clear, yellow fluid at an initial pressure of 90 mm. of water. Arterial pulsations were absent. There was a complete spinal subarachnoid block as shown by Queckenstedt's test. Examination of the fluid showed no cells, a marked trace of globulin, total protein 325 mg. per 100 cc., negative Wassermann reaction, and negative colloidal gold curve.

Roentgen examination of the spine in the lateral view showed erosion of the spinous process and laminae of the fourth thoracic vertebra (Fig. 2).

A diagnosis was made of neoplasm compressing the spinal cord at the level of the fourth thoracic vertebra. In this case it was possible to localize the level of the tumor exactly by the neurological examination and by the roentgen films of the spine so that lipiodol studies were not necessary.

At operation July 7, 1936, a soft, reddish-gray tumor mass was found to involve the spinous process and laminae of the fourth thoracic vertebra. The laminae had been completely destroyed and replaced by tumor tissue. The mass extended laterally to invade the muscles on each side. The tumor was removed as completely as possible and was found to be entirely extradural. A cleavage plane existed between the dura and the overlying tumor. The cord had been markedly compressed and, after removal of the tumor, the dura pulsed normally throughout the area of the exposure. The cavity from which the tumor was removed appeared to be as large as a golf ball. Where the neoplasm invaded the muscles on each side, it did not seem to be encapsulated. The cord was well decompressed and the wound was closed.

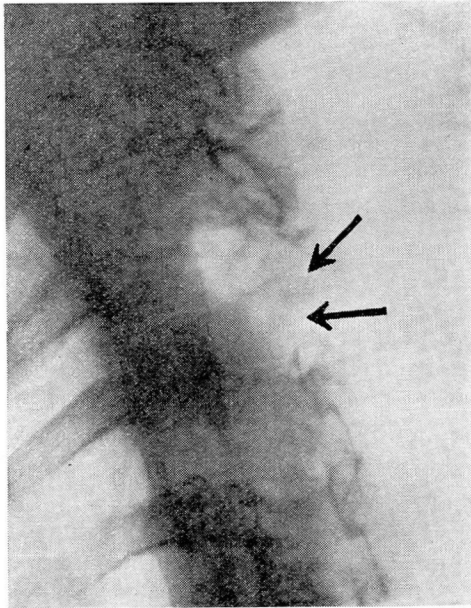


FIGURE 2: Lateral roentgenogram of spine showing erosion of spinous process and laminae of the fourth thoracic vertebra by plasma cell myeloma.

Microscopic examination of the tumor tissue revealed a very cellular structure of uniform type. The predominant cell was that of a plasma cell myeloma. The tumor was well vascularized and contained very little fibrous stroma or necrosis. The pathological diagnosis was plasma cell myeloma of the spine (Fig. 3).

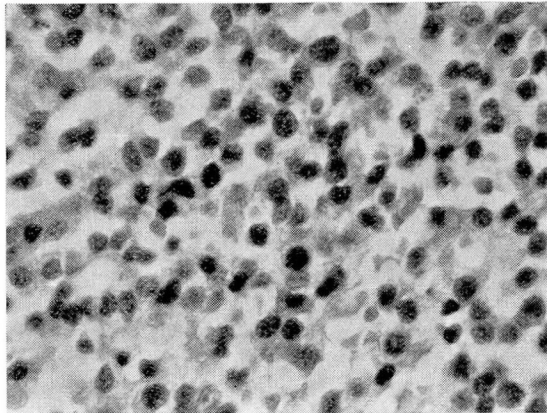


FIGURE 3: Photomicrograph of plasma cell myeloma (x 600).

Because of the nature of the tumor, the patient received a course of roentgen therapy before he left the hospital. Within a week following operation, he regained normal sensation in the lower half of the body. Motor function, as

TUMORS OF THE SPINAL CORD

usual in cases of rapid compression of the cord, failed to show improvement parallel to that of sensory function. The patient was able to flex and extend his legs slightly before leaving the hospital on the twenty-sixth day after operation.

When the nature of the tumor was known, a search for Bence-Jones protein in the urine was made on several occasions, but none was found.

The patient returned to the Clinic for further roentgen therapy in October 1936 and in March 1937. He was last seen at the Clinic on June 21, 1937, at which time he was able to walk slowly with the aid of crutches. Both legs were still spastic, but the left leg showed marked improvement in voluntary motion. Babinski's sign persisted on both sides. Sensation was normal. The patient had normal control of vesical and rectal function.

He has been asked to return every four months for observation and further roentgen therapy, if indicated. Thus far there has been no evidence of myeloma involving any bones of the body other than the fourth thoracic vertebra and there has been no evidence of local recurrence.

TREATMENT

At the present time the primary treatment of spinal cord tumors is surgical exposure, removal of the growth if possible, and decompression of the cord. A good prognosis attends the removal of benign extramedullary neoplasms, unless compression of the cord has been prolonged to the stage of permanent damage to the cord. The treatment of gliomas of the cord and of tumors causing rapid compression of the cord offers much less hope of good results. Since it is rarely possible to make a preoperative diagnosis of the type of tumor, surgical exploration is warranted in every case of tumor involving the spinal cord, unless there are other general contraindications to major surgery. If radio-sensitive tumors are encountered, roentgen therapy, of course, offers the best opportunity for improvement in the condition of the patient.

In conclusion, it may be worth while to emphasize again the importance of considering the possibility of spinal cord tumor in the differential diagnosis of certain conditions characterized by pain, by changes in motor function, or by changes in sensory function. In this regard, the inestimable value of lumbar puncture and Queckenstedt's test must not be forgotten.

REFERENCES

1. Bunts, A. T.: Spinal cord tumors; analytical review of 36 cases, *S. Clin. North America*, 15:1047-1062, (August) 1935.
2. Jones, O. W. Jr. and Naffziger, H. C.: Tumors on the spinal cord; their diagnosis; analysis of 59 cases, *California & West. Med.*, 45:17-20, (July) 1936.
3. Klemme, R. M.: Plasma cell myelomas causing cord compression; report of 5 cases, *South. M. J.*, 26:692-696, (August) 1933.
4. Denker, P. G. and Brock, S.: Generalized and vertebral forms of myeloma: their cerebral and spinal complications, *Brain*, 57:291-306, (October) 1934.
5. Wakeley, C. P. G.: Plasma-celled myelomatosis, *Proc. Roy. Soc. Med., (Clin. Sect.)*, 25:22, (December) 1931.