

Selective canine renal infarction

Anthony F. Lalli, M.D.
Carl H. Linge, M.D.*
Werner J. Friesen, M.D.*
Division of Radiology

Several procedures using radiologically-guided catheter techniques for the production of selective infarcts of the dog's kidney have been described.¹⁻³ Doppman et al⁴ have reported their experience with a silicone rubber preparation injected through a non-balloon type catheter. This method involves the obstruction of the main renal artery and several branches and has been proposed as a mode of control of angiomatous malformations. It is an extension of the work in the control of spinal cord arteriovenous malformations.⁵ Previous experience in the production of experimental renal infarctions using balloon and non-balloon type catheters and Sephadex* has been reported.^{2, 3} We believe that the potentially rich collateral blood supply of the kidney, as well as the primary blood supply, must be obstructed.⁶ For this reason we have chosen a method using a particulate material calculated to obstruct the smallest vessels, rather than the method of Doppman et al. In this way we hope to prevent the development of a collateral blood supply through capsular vessels. Recently, a commercially available balloon type catheter suitable for selective injections was made available to us, and we report our experience in the development of a clinically

* Fellow, Division of Radiology.

* Pharmacia Laboratories, Inc., Piscataway, New Jersey.

useful nonsurgical ablation of the kidney which might be applied in patients with unilateral renal disease.

Method

Ten anesthetized dogs were studied on a nonsurvival basis. Preoperative and postoperative abdominal films were obtained, and the femoral artery was exposed and cannulated by a double lumen, balloon-tipped No. 7 Fr. Wooley catheter.* The tip of the catheter can be controlled and shaped by a stainless steel wire. After the tip of the catheter was identified fluoroscopically in the right renal artery by injecting 1 or 2 ml of contrast medium, 2 ml of saline solution containing 0.25 g of tantalum pentoxide (particle size 50 to 150 μ) was injected through the catheter. The balloon of the catheter was inflated immediately before the injection of the tantalum and was kept inflated for 2 minutes after the injection. The catheter was then removed, and an additional abdominal roentgenogram was obtained. The dogs were then killed, the kidneys were removed, and roentgenograms were obtained.

An additional 10 large mongrel dogs were studied on a long-term basis. For 3 weeks before the procedure, blood pressure measurements were taken at random intervals through direct femoral artery cannulation. In the same manner as before, tantalum pentoxide was injected into the right kidney. The special balloon catheter was removed, a postoperative roentgenogram of the abdomen was obtained, and the femoral artery was ligated. The dogs were maintained for 11 weeks. During the last 3 weeks blood pressure meas-

urements were determined as described above. The dogs were killed at the end of 11 weeks after excretory urography. The kidneys were removed, x-ray films were made, the kidneys were weighed and measured.

Results

In the series of 10 dogs studied on a nonsurvival basis, 8 had an adequate distribution of tantalum in the right kidney. In two dogs opaque particles of tantalum were identified in extrarenal structures, including bowels and spinal cords.

The results in the dogs studied on a long-term basis are presented in the *Table*. One dog (no. 7) became paraplegic immediately after the procedure and was killed the next day. The paraplegia may have been the result of faulty function of the occluding balloon, allowing some of the tantalum to escape,⁷ and cause infarction of the spinal cord. An error in technique in dog no. 9 resulted in the injection of the tantalum into the superior mesenteric artery. There were no adverse effects and the dog was maintained as a control.

The desired result, a shrunken, functionless kidney, was found in each of two dogs; a significant reduction in kidney size occurred in three others. Renal infarction was slight in the remaining dogs (*Figs. 1A and B*).

Discussion

The variability of infarction results and response was related to several factors, including some lack of expertise in a new procedure, and incorrect estimates of the size of the renal arteries and the quantity of tantalum necessary to cause total infarction. Delivery of the tantalum in normal saline

* Edwards Laboratories, Santa Ana, California.

Table. Results in 10 dogs studied on long-term basis

Dog no.	Preop BP, average	Postop BP, average	Weight		Length		Result
			R, g	L, g	R, cm	L, cm	
1	136	136	42.8	57.3	6.3	6.9	Slight effect
2	140	142	10.5	63.0	4.1	7.0	Total infarct
3	135	146	16.4	67.8	4.8	6.9	Total infarct
4	135	143	39.8	66.1	7.0	7.8	Subtotal infarct
5	131	115	18.6	54.5	4.5	6.7	Subtotal infarct
6	119	131	32.6	54.3	5.8	6.9	Subtotal infarct
7	—	—	—	—	—	—	Paraplegic
8	124	129	58.2	79.5	7.2	8.1	Slight effect
9	126	136	64.8	66.8	7.4	7.8	Slight effect
10	116	117	45.1	43.6	6.4	6.6	Slight effect

solution also resulted occasionally in the retention of some of this mixture in the catheter. We concluded that the smaller the total volume of tantalum-saline mixture and the faster the injection, the better the result. In the less successful cases the cortical infarcts were predominantly on the dorsal aspect of the kidney. This may be the result of the fact that the heavy tantalum particles selectively entered the dorsal branches of the main renal artery.

The blood pressure changes were variable and slight with no correlation with the severity of renal infarct produced.

When we used a hand-built catheter composed of a No. 8 Foley balloon attached to an angiographic catheter, a more effective technique was possible.³ This may be explained in part by our use of a mixture of Sephadex and tantalum in the earlier experiment, and only tantalum in this experiment.

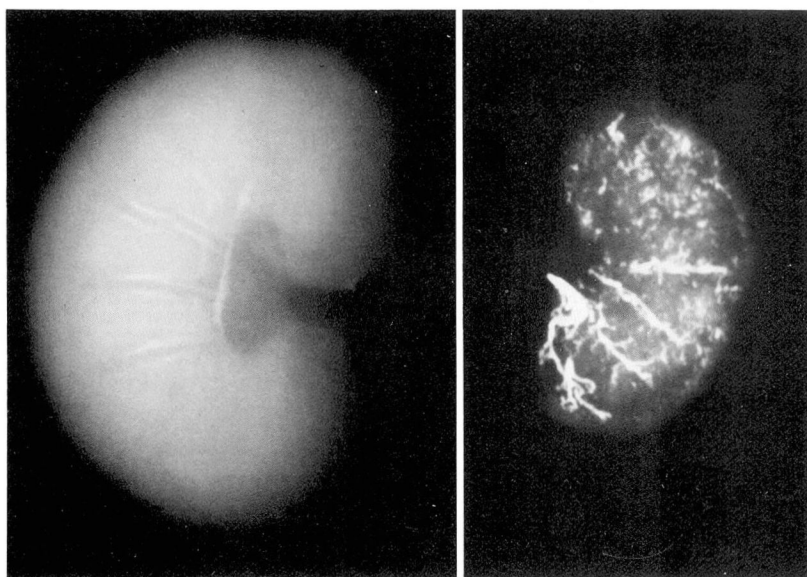
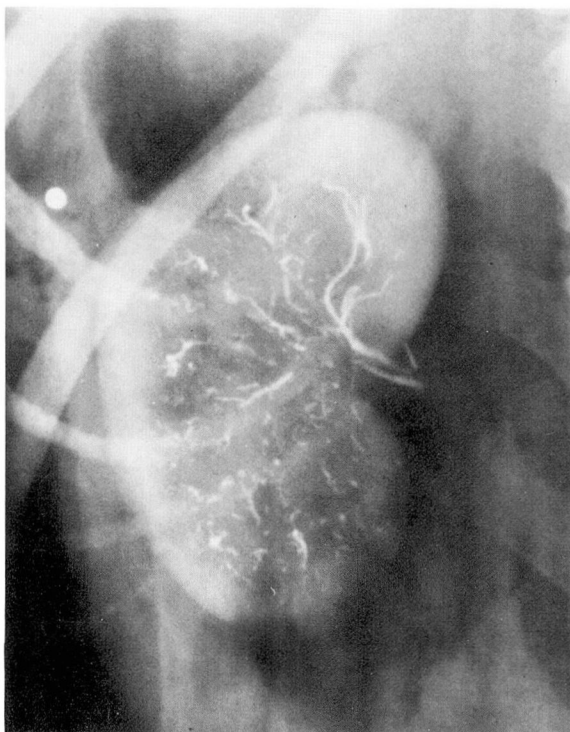
Other investigators have described the use of brine shrimp eggs, lobelia seeds, blood clots, and polystyrene microspheres.^{1, 7, 8} Their work did not seem to have a future clinical applica-

tion. With the rapid development of catheter techniques, particularly balloon catheters, it may be possible to use destructive agents such as intra-arterial barbiturates accompanied by main renal artery occlusion maintained with the balloon. This could avoid the risks involved in using a particulate material which could escape and cause infarctions in undesired locations. We shall explore this possibility in the future. Our results have encouraged us to consider extending our studies so that eventually this procedure could be justifiably applied to the patient with an amenable problem.

Summary

The results of experimental renal infarctions in 10 dogs studied on a nonsurvival basis and in 10 dogs studied on a long-term basis are reported. The technique of employing a balloon catheter under roentgenographic guidance and the injection of tantalum pentoxide into the right renal artery is described. Significant changes in blood pressure were not detected despite partial and total renal infarctions.

Fig. 1. Distribution of tantalum in the right kidney (dog no. 3) at the completion of the injection procedure. **A, top.** Metallic foreign body lateral to the kidney is the result of previously inflicted shotgun wound. **B, bottom.** Postmortem radiographs of kidneys showing total infarction 81 days later in the right kidney and compensatory hypertrophy of the left kidney.



References

1. Edling NPG, Ovenfors CO: Intentional embolism in selective renal arteriography; an experimental study in dogs. *Acta Radiol (Diagn)* 2: 316-320, 1964.
2. Lalli AF, Peterson N, Bookstein JJ: Roentgen-guided infarctions of kidneys and lungs, a potential therapeutic technic. *Radiology* 93: 434-435, 1969.
3. Lalli AF, Bookstein JJ, Lapides J: Experimental renal infarctions in dogs. *Invest Urol* 8: 516-520, 1971.
4. Doppman JL, Zapol W, Pierce J: Transcatheter embolization with a silicone rubber preparation; experimental observations. *Invest Radiol* 6: 304-309, 1971.
5. Newton TH, Adams JE: Angiographic demonstration and nonsurgical embolization of spinal cord angioma. *Radiology* 91: 873-876, 1968.
6. Eliska O: The collateral blood flow of the canine and human kidney. *Cor Vasa* 8: 68-75, 1966.
7. Alexander N, Heptinstall RH, Pickering GW: The effects of embolic obstruction of intrarenal arteries in the rabbit. *J Pathol Bacteriol* 81: 225-237, 1961.
8. Karsner HT, Austin JH: Studies in infarction; experimental bland infarction of the kidney and spleen. *JAMA* 57: 951-958, 1911.