

Endoscopic retrograde cholangiographic evaluation of sclerosing cholangitis

Harvey B. Lefton, M.D.*

Eugene I. Winkelman, M.D.

Department of Gastroenterology

Sclerosing cholangitis is a chronic inflammatory fibrosing process involving the septal and larger intrahepatic ducts. It has been described as occurring separately or in association with inflammatory bowel disease, retroperitoneal fibrosis, or Riedel's thyroiditis. Clinically, the patient may be asymptomatic or jaundiced. Microscopically, sclerosing cholangitis is identified by a nonspecific inflammatory infiltrate surrounding the ductal system with evidence of ductal fibrosis. The absence of ductal proliferation is a key feature in distinguishing it from primary biliary cirrhosis. The natural course of the disease is variable, and many patients eventually die of hepatic failure or portal hypertension. However, a number of reports indicate that the condition of patients with primary sclerosing cholangitis may stabilize for several years.

There is presently no definitive means of monitoring patients with sclerosing cholangitis. Although liver biopsy is the most accurate means of assessing the intrahepatic inflammatory process, biopsy supplies only indirect evidence of the status of extrahepatic sclerosis. In past reports^{1, 2} investigators have indicated a need for a second laparotomy in these patients, but others have sug-

*Fellow, Department of Gastroenterology.

gested the use of percutaneous transhepatic cholangiography³ in assessing the status of the extrahepatic ductal system prior to surgery. A less invasive technique would obviously be beneficial in following patients with primary sclerosing cholangitis.

This report outlines the progress of a patient with sclerosing cholangitis. The status of the extrahepatic ducts was reevaluated by endoscopic retrograde cholangiography. The value of this technique in assessing patients with primary sclerosing cholangitis is discussed.

Case report

A 37-year-old white man was referred to the Cleveland Clinic on May 3, 1973, for evaluation of persistently abnormal liver function studies. He had been well until March 1970, when he attempted to donate blood and was found to have an elevated serum bilirubin level. Liver function studies disclosed the following values: total serum bilirubin 1.2 mg/100 ml with 0.4 mg/100 ml direct reaction; alkaline phosphatase, 230 International units (IU) (normal 30 to 85); serum glutamic oxalo-

acetic transaminase (SGOT), 95 Karman units (normal 10 to 40). Other blood chemistry values were normal. The initial impression was viral hepatitis. Serum bilirubin levels during the next 3 months remained elevated. In June 1970 icterus became apparent and to evaluate the persistent hyperbilirubinemia, a laparotomy was performed on June 23, 1970. Operative findings included a large, dilated, thin-walled gallbladder which could not be made to empty through the cystic duct, marked dilatation of the distal cystic duct, and proximal fibrosis and narrowing of the common bile duct. With some difficulty, a small T-tube was inserted into the common duct and a T-tube cholangiogram was obtained (*Fig. 1*). This was interpreted as showing hypoplasia of the intrahepatic and extrahepatic duct system. Cholecystectomy was performed and an open wedge biopsy of the liver was obtained.

Microscopically, the liver tissue showed sinusoidal congestion, with an inflammatory infiltrate surrounding the bile ducts. The segment of extrahepatic bile duct showed severe inflammation involving the submucosal connective tissue and glands. There was a predominance of lymphocytes with scattered areas of polymorphonuclear leukocytes. The gallbladder showed moderately severe, chronic inflammation involving the mucosa and making a villous pattern. Numerous plasma cells and lymphoid follicles were identified in the gallbladder. There was no evidence of carcinoma or infectious agents in the pathology specimens.

Postoperatively, the total serum bilirubin fell from 3 mg/100 ml to 0.8 mg/100 ml. The T-tube was removed 3 weeks after surgery and the patient remained anicteric. During the next 2 years, the bilirubin fluctuated between 1 mg/100 ml and 3 mg/100 ml. Florantyrone (Zanchol), one tablet four times a day, was prescribed by the physician 6 months after surgery when the patient complained of malaise. This medication could not be discontinued without recurrence of malaise. One

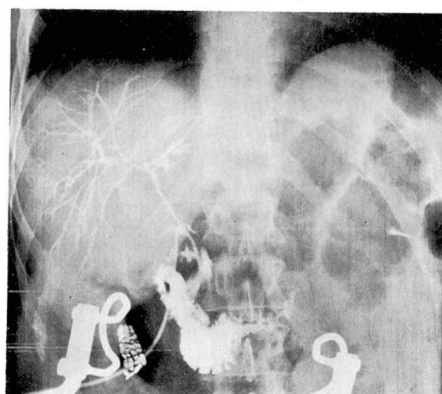


Fig. 1. Operative cholangiogram, June 1970, showing severe narrowing of the common bile duct, hepatic and intrahepatic ducts. Contrast material in the duodenum indicates patency of the narrowed common duct.

year before he was seen at the Clinic, persistent vesicles developed on the dorsum of his hands after exposure to sunlight. A skin biopsy was obtained and a diagnosis of porphyria cutanea tarda was made. In April 1973 the total serum bilirubin level was 2.1 mg/100 ml, bromosulphalein (BSP) retention was 26 mg/100 ml at 45 minutes, alkaline phosphatase was 270 IU and the SGOT was 115 Karman units.

When seen at the Cleveland Clinic on May 3, 1973, the patient complained of occasional malaise occurring at the end of the day. He stated that he had no history of jaundice, pleuritis, or recent change in the color of urine or stool. On physical examination he was a well-developed, well-nourished man in no acute distress. Scleras were normal. Abdominal examination revealed a liver span of 12 cm. There was no splenomegaly nor abdominal masses. Areas of scarring and small ulcerations were present on the dorsum of the hands. The remainder of the physical examination was normal.

The patient was admitted to the Cleveland Clinic Hospital on May 7, 1973. An intravenous cholangiogram gave inadequate visualization of the bile ductal system. On May 11, 1973, the patient underwent retrograde cannulation of the ampulla of Vater (Figs. 2 and 3). These films showed severe hypoplasia and beading of the biliary ducts and narrowing of the common bile duct; changes compatible with sclerosing cholangitis. The postcannulation course was complicated by gram-negative sepsis with *Enterobacter cloacae* which responded to treatment with cephaloridine and gentamicin. Before the patient's discharge from the hospital, a liver biopsy specimen showed minimal bile stasis with no evidence of acute inflammation. Biopsy specimens of the lesions on the dorsum of the hands showed dermal fibrosis and solar elastosis compatible with porphyria cutanea tarda. There was no evidence of gamma-A globulin (IgA), gamma-M globulin (IgM), or gamma-G globulin (IgG) on immunofluorescence

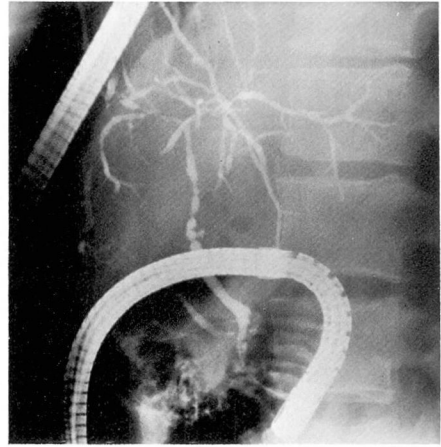


Fig. 2. Retrograde cholangiogram showing severe narrowing of the intrahepatic and common bile ducts. The duodenoscope is in the descending duodenum and the catheter is in the ampulla of Vater.

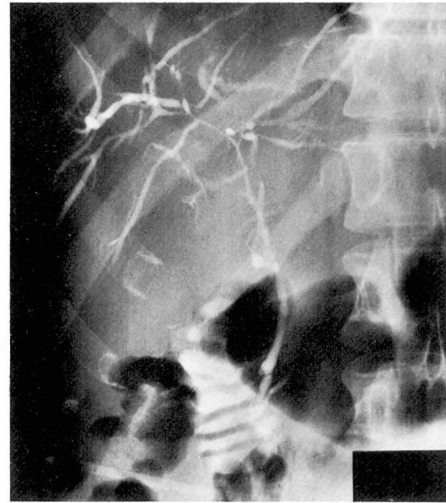

Fig. 3. Later film of narrowed biliary system. Contrast material is seen in the duodenum.

studies of the skin and liver biopsies. The patient was referred to his family physician for follow-up. In March 1974, without treatment, total serum bilirubin level was 2 mg/100 ml with a direct bilirubin of 0.3 mg/100 ml, and except for occasional malaise at the end of the day, he had no symptoms.

Discussion

Endoscopic retrograde cannulation is a useful technique in diagnosing disorders of the biliary and pancreatic ducts. Safrány et al⁴ emphasized the success of this procedure in diagnosing biliary disorders, i.e., gallstones obstructing the common duct, pancreatic tumors, pseudocysts and strictures of the bile ducts, and carcinoma of the bile ducts. Patients with obstructive lesions of the bile ducts often are unable to concentrate intravenous cholangiographic media, and views of the biliary system are unobtainable, whereas retrograde cholangiography can provide the clinician with adequate visualization of the biliary system. In addition, it is now also possible to view and biopsy lesions in the region of the papilla of Vater.

Until now the diagnosis of extrahepatic obstruction due to sclerosis of the biliary system was limited to intravenous or operative cholangiography. Roentgenograms show beading of the intrahepatic radicles, mainly those in the large ductal biliary system.⁵ This finding is not in itself diagnostic. Generalized narrowing of the biliary system described as a "pruned tree silhouette" is also seen in primary biliary cirrhosis. Endoscopic retrograde cholangiography provided adequate evaluation of the biliary ductal system in this patient. By comparing this cholangiogram with the cholangiogram done during his surgery in 1970, an estimate of the present status of the biliary system was obtained.

The major problem in sclerosing cholangitis is differentiation from carcinoma of the bile ducts, which can only be adequately done by long-term follow-up of the patient. Unfortu-

nately, even direct biopsy of the biliary system is not completely reliable in diagnosing bile duct carcinoma. At present we are unable to obtain adequate biopsy specimens of the biliary system without surgery, but with improved techniques endoscopic biopsies may also be possible.

It should be emphasized that when obstructive lesions of the biliary ducts are suspected, antibiotics should be given to the patients before retrograde cholangiography. If an unexpected obstruction is found during the procedure, the antibiotic should be given immediately. Ampicillin or the cephalosporins deliver a high concentration in the bile and seem well-suited for treating biliary infections in patients with obstruction. Bacteremia and cholangitis developed in this patient after the procedure. This might have been avoided if antibiotics had been started as a prophylactic measure prior to endoscopy.

A liver biopsy performed after recovery from the cholangitis allowed adequate evaluation of the current status of the intrahepatic process and suggested a degree of resolution of the hepatic inflammation. Hepatic inflammation had subsided leaving extrahepatic biliary fibrosis. By evaluating the results of liver biopsy and cholangiogram, surgery was avoided.

Retrograde endoscopic cholangiography appears to be an effective means of evaluating the biliary ductal system, and in this instance provides an insight into the status of a patient with a diagnosis of sclerosing cholangitis. Although it is not necessarily helpful in distinguishing between carcinoma and inflammatory lesions of the biliary ductal system, it is a safe means of

evaluating the ductal system in patients with an established diagnosis. Combined with liver biopsy and liver function tests, endoscopic cholangiography offers a meaningful picture of the activity of the patient's illness.

References

1. Glenn F, Whitsell JC II: Primary sclerosing cholangitis. *Surg Gynecol Obstet* **123**: 1037-1046, 1966.
2. Warren KW, Athanassiades S, Monge JI: Primary sclerosing cholangitis; a study of forty-two cases. *Am J Surg* **111**: 23-38, 1966.
3. Okuda K, Tanikawa K, Emura T, et al: Nonsurgical, percutaneous transhepatic cholangiography—diagnostic significance in medical problems of the liver. *Am J Dig Dis* **19**: 21-36, 1974.
4. Safrány L, Tari J, Barna L, et al: Endoscopic retrograde cholangiography. *Gastrointest Endosc* **19**: 163-168, 1973.
5. Rogers JV Jr, Copeland AJ Jr, Schroder JS, et al: Sclerosing cholangitis—roentgenographic features. *South Med J* **65**: 587-594, 1972.