

Pituitary apoplexy treated by stereotactic transphenoidal aspiration

Gustavo Berti, M.D.*
William G. Heisey, M.D.†
Donald F. Dohn, M.D.

*Department of Neurological
Surgery*

It is not surprising that a tumor of the pituitary, an organ so complex and important in its endocrine functions and anatomical relationship, can make its initial presence known in many different ways. Since the onset of symptoms is usually insidious and the progression slow, the tumor may have been present for a long time before it is discovered. Occasionally, the first symptom may be dramatic. There may be sudden necrosis or hemorrhage of the tumor, i.e., the syndrome of pituitary apoplexy.

Acute hemorrhagic necrosis of a pituitary adenoma was first described in a young, acromegalic patient by Bleibtreu,¹ in 1905, but this syndrome was largely unrecognized until 1950 when Brougham et al² reported the clinicopathologic features of five cases verified at autopsy and entitled this syndrome "pituitary apoplexy." In 1957, Uihlein et al³ collected 72 cases and added two of their own. Since then numerous reports have been published.

This report concerns 11 cases of pituitary apoplexy seen in the Department of Neurological Surgery of the Cleveland Clinic between 1950 and 1974. The most recent case will be reported in

* *Fellow, Department of Neurological Surgery.*

† *Present address: 300 Longwood Avenue, Boston, Massachusetts 02115.*

detail to emphasize a new method of surgical treatment.

Case report

A 55-year-old white man was seen in the Department of Internal Medicine in July 1972 with a 2-year history of non-progressive fatigue and mild, nonspecific weakness of his legs. The general physical examination demonstrated findings consistent with panhypopituitarism. A neurological consultant found a slightly unsteady gait, a positive snout reflex, bilateral Babinski signs, decreased vibratory sensation in the lower limbs, and high arched feet. A neuro-ophthalmological examination revealed normal visual fields. Laboratory studies disclosed the following values: hemoglobin level, 13.6 g/100 ml, hematocrit reading, 40.8%; plasma cortisol levels, 8.1 μ g/100 ml; protein bound iodine (PBI), 4.2 μ g/100 ml; blood glucose, 92 mg/100 ml; a 2-hour glucose tolerance test, 133 mg/100 ml the first hour and 112 mg/100 ml the second hour; serum calcium level, 9.2 mg/100 ml; serum phosphorus level 5.1 mg/100 ml. T_3 test was 29%, urinary 17-ketosteroids and urinary 17-hydroxycorticoids were 0.5 mg/24 hr.

Plain skull roentgenograms disclosed an enlarged sella turcica with erosion of the dorsum. The technetium 99 brain scan was normal. Bilateral carotid angiograms and pneumoencephalogram disclosed a small pituitary tumor with slight suprasellar extension and a parasellar extension toward the right and mild dilatation of the ventricular system. Since there were no visual symptoms, surgical treatment was not advised. The patient received radiation therapy: total midline dose of 4,060 rads delivered with a cobalt 60 source through a 6 \times 6 cm field over a 1-month period. An incidental clinical diagnosis of a spinocerebellar degeneration was also made by the neurological service.

The patient was seen periodically as an outpatient until March 1974, when he was admitted to the hospital because of diplopia, which had been present for 6

weeks, and increasing fatigue. The neurological examination at that time disclosed a slight ptosis of the right eye, a left Babinski sign and left foot drop with fasciculation of the left calf. He was seen by a neuro-ophthalmologist who found a right third nerve paresis with no pupillary abnormalities. Visual fields were again normal. A right carotid angiogram and pneumoencephalogram were repeated and these were essentially unchanged compared with those taken in 1972 (Figs. 1-3). A clinical diagnosis of diabetic neuropathy was made, the third nerve palsy receded, and no specific therapy was prescribed except for replacement hormones for panhypopituitarism. The patient was discharged on April 5, 1974.

He was next seen on April 26, 1974, with a main complaint of fatigue for 3 weeks and ptosis with decreased visual acuity in the right eye for 2 days, associated with generalized malaise. By the time the patient was admitted to the hospital a few hours later, he had noted further deterioration in vision. Examination of the right eye disclosed almost total loss of vision and no extraocular movement; the left eye was normal. An EMI scan done the evening of admission disclosed a parasellar mass with no change in the ventricular system as compared with a previous EMI scan in March 1974.

The same evening, the patient was taken to the Operating Room where, under endotracheal anesthesia and using a stereotactic apparatus, a transnasal-transphenoidal aspiration of the enlarged sella was performed under image intensification control (Fig. 4). This yielded 12 to 15 cc of dark hemorrhagic fluid in which clusters of chromophobe cells were later identified microscopically. The patient tolerated the procedure well and upon awakening in the Recovery Room reported a marked improvement in visual acuity. Visual fields done 3 days after surgery were normal. He was discharged on the 4th postoperative day. When seen again in the Department of Ophthalmol-

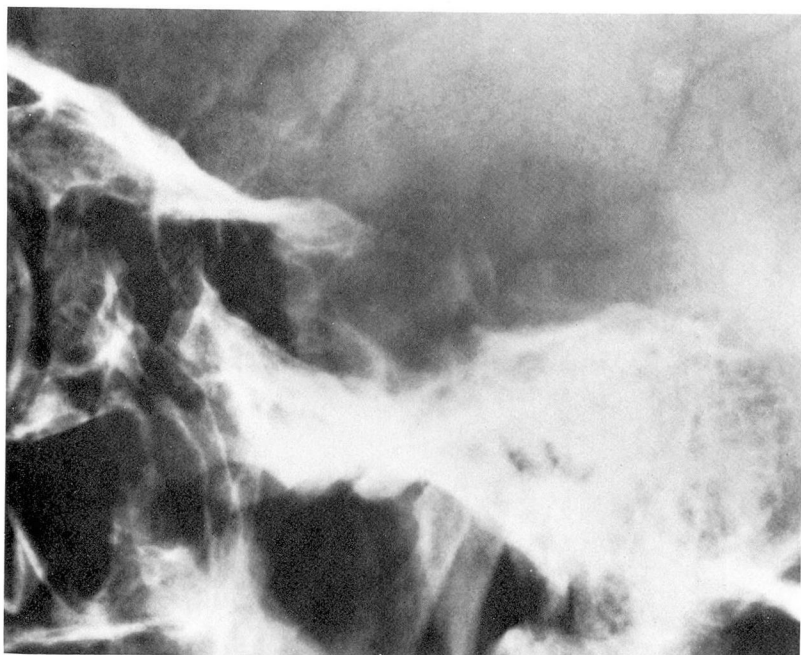


Fig. 1. Lateral skull roentgenogram showing enlarged sella turcica with erosion of dorsum.

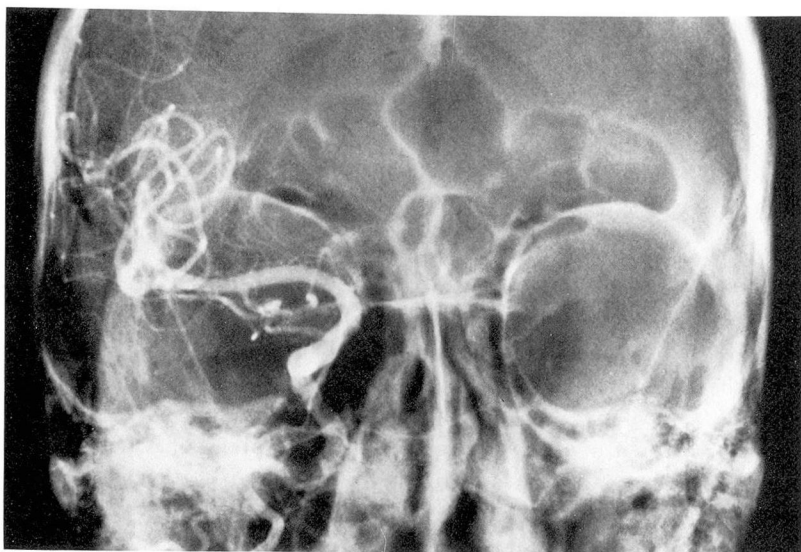


Fig. 2. Right carotid angiogram. AP (reverse) Caldwell view showing lateral displacement of intracavernous segment of internal carotid artery. Both anterior cerebral arteries fill from left side.

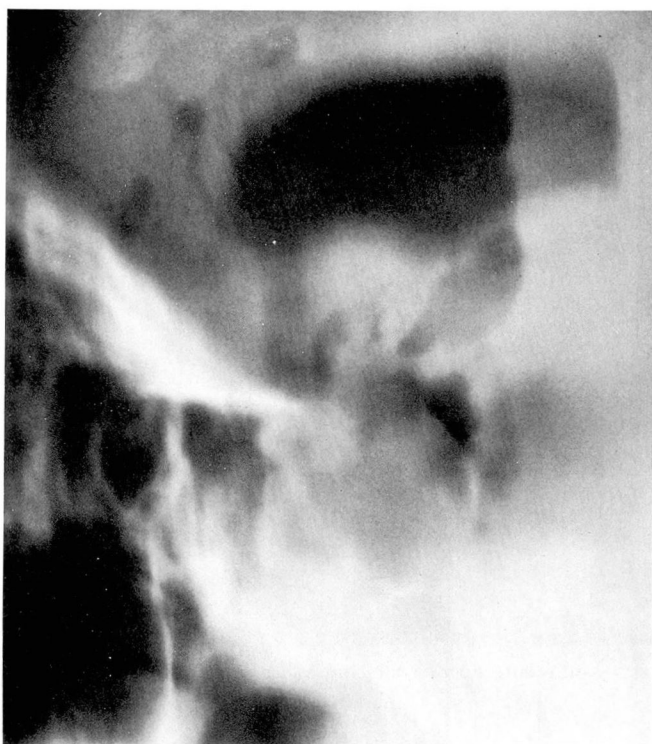

Fig. 3. Midline tomogram during pneumoencephalography showing small suprasellar extension.

ogy a month later, his fields were again normal; he had only a residual mild paresis of the muscles supplied by third, fourth, and sixth nerves on the right. His examination 5 months postoperatively revealed normal vision and only slight sixth nerve paresis.

Analysis of cases (see *Table*)

Sex and age. There were six men and five women, ranging in age from 30 to 66 years (average 47 years). In our series, the women were younger than the men.

Headache. Sudden, excruciating headache was the first symptom in all but one of the patients. In seven patients the headache was primarily bifrontal and, in three cases, localized to one eye—the same eye which later developed either extraocular muscle

palsy or amblyopia. The headache preceded hospital admission by 1 day to 1 month. In one patient (case 8) the first indication of pituitary apoplexy was sudden, bilateral loss of vision. This occurred 2 weeks following transthoracic ligation of esophageal varices for intractable hematemesis.

Extraocular muscle involvement. Three patients had complete unilateral ophthalmoplegia and four patients had unilateral third nerve involvement (two complete and two partial with ptosis only). In three patients there was no compromise of the third, fourth, or sixth cranial nerves.

Visual acuity fields. Only one patient had no visual field deficit. Three patients had bitemporal hemianopsia and one patient had homonymous

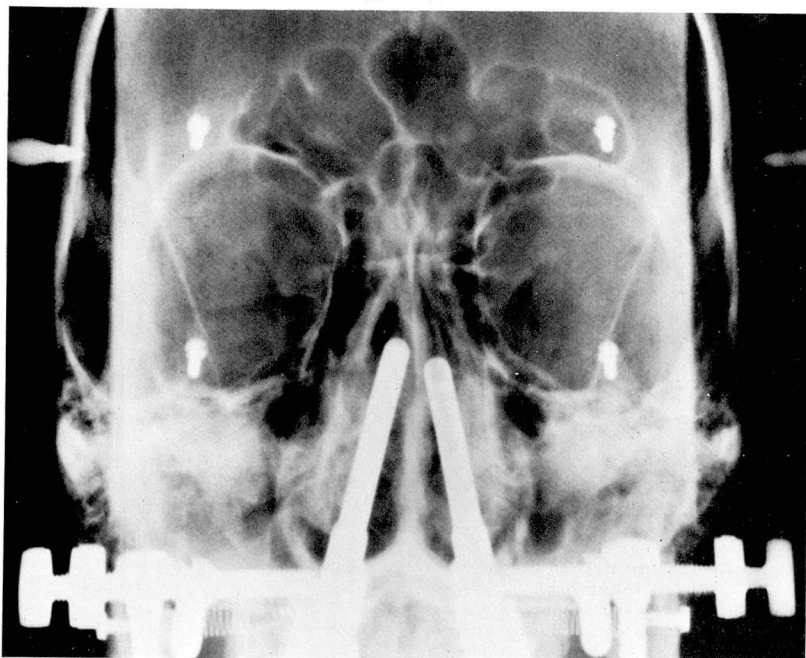


Fig. 4. Stereotactic needle guide for pituitary aspiration. Longer guide is on right side.

hemianopsia. Six patients were completely blind in one eye with varying degrees of vision in the opposite eye.

Fundusoscopic examination. There was bilateral papilledema in one patient. Optic atrophy was present in five patients.

Alteration of level of consciousness. An altered state of consciousness occurred in five of the patients. Three patients were drowsy, lethargic, and mentally confused; two became stuporous. One of these patients (case 1), who was febrile, uncooperative, and acutely ill, also had bilateral papilledema. At surgery a large suprasellar mass indenting the hypothalamus was found. The remaining patients were alert and had no acute distress. No definite correlation was found between any specific neurological finding and the state of consciousness; however, lethargy, fever, and neck stiffness were

more common among those patients who had complete ophthalmoplegia or proptosis or both.

Meningeal irritation. Neck stiffness was present in three patients. One of these (case 2) was also lethargic and had a left third nerve palsy with no visual field defect. Lumbar puncture yielded xanthochromic fluid with high pressure, and initially a diagnosis of left internal carotid aneurysm was suspected. A second patient (case 3) had neck stiffness, a left Babinski sign, and was also lethargic. A third patient (case 4) was also nauseated and febrile.

Symptoms and signs of preexistent pituitary dysfunction. Symptoms of endocrine dysfunction were not particularly prominent, nor of much help diagnostically. One patient (case 3) had been amenorrheic for 9 years and was taking thyroid extract. Two patients had clinical evidence of hypopitui-

Table. Analysis of 11 cases of pituitary apoplexy

Case	Age, sex	Clinical symptoms	Neurological examination	Eye examination
1	52 M	Frontal headaches several mo; worse 4 days before admission; associated visual loss and fever	Lethargy, mildly uncooperative	R, 3rd, 4th, 6th nerve paresis, ptosis, proptosis, blind L, finger vision; bilateral papilledema
2	42 F	Transient blurring of vision of left eye 2 wk before admission; acute left frontal headaches; decreased visual acuity of left eye; nausea, vomiting and photophobia 1 wk before admission	Lethargy, neck stiffness	R, normal L, 3rd nerve paresis
3	33 F	Mild decrease in peripheral vision 4 yr; acute bifrontal headaches 8 days before admission; blurred vision and photophobia 1 day before admission	Neck stiffness, febrile, drowsy, left Babinski sign	R, ptosis Bitemporal hemianopsia Bilateral optic pallor
4	45 F	Bifrontal headaches several years; worse 4 days before admission; associated nausea, vomiting, fever	Lethargy, neck stiffness	R, dense temporal defect L, blind, proptosis
5	66 M	Impotence, endocrinopathy 3 yr; bifrontal headaches 3 mo; progressive weakness, fatigue, vomiting	Hypopituitarism, right Babinski sign	Bilateral optic atrophy Right homonymous hemianopsia
6	48 M	Headaches several years; worse 4 days before admission; diplopia and ptosis of left eye 2 days after	Alert, awake, neck supple	L, 3rd nerve palsy Superior bitemporal quadrantsia
7	37 F	Spontaneous CSF rhinorrhea and bitemporal hemianopsia to color objects 9 yr; no lesion found at craniotomy 9 yr before; sudden right frontal headaches 1 day before admission	Alert, awake, neck supple	R, ptosis Bilateral optic atrophy Bitemporal hemianopsia
8	30 F	Chromophobe adenoma transfrontally removed 4 mo previously; postoperatively, visual fields showed mild bitemporal hemianopsia; no postoperative radiation. Sudden bilateral visual loss 14 days after transthoracic ligation of bleeding esophageal varices	Acromegaly	R, only central vision L, blind optic atrophy
9	50 M	Chromophobe adenoma removed transfrontally 15 yr previously; total recovery of vision; sudden onset left frontal headaches followed by decreased visual acuity of left eye 5 days before admission	Alert, awake, no signs of hypopituitarism	R, temporal field defect L, blind, pupil unreactive Bilateral optic atrophy
10	62 M	Sudden bifrontal headaches, decreased visual acuity right eye 4 wk; progressed to blindness in 8 days; ptosis and decreased visual acuity of left eye 2 wk	Alert, awake	R, blind, optic atrophy; 3rd, 4th, 6th nerve paresis L, temporal field defect
11	55 M	Known pituitary adenoma in 1972; no field deficit; treated with Co 60; admitted March 1974 with diplopia which receded spontaneously; readmitted April 1974 with severe bifrontal headaches 3 days; diplopia and decreased visual acuity of right eye 24 hr	Lethargy, nauseated, hypopituitarism	R, blind, 3rd, 4th, 6th nerve paresis L, normal

tarism. Another was acromegalic, although the pathologic findings of the surgical specimen were compatible with a chromophobe adenoma rather

than an eosinophilic adenoma. In seven of our patients the presence of pituitary adenoma was unknown at the time of the apoplectic episode.

CSF	Sella turcica	Treatment		Pathologic diagnosis	Results
0	Completely eroded	RFC	pituitary decompression	Chromophobe; hemorrhage	Improved
Xanthochromia; pressure 380 cm	Enlarged	LFC	pituitary decompression	Chromophobe; hemorrhage	Total recovery
Xanthochromia	Enlarged; thin dorsum	RFC	pituitary decompression	Chromophobe; hemorrhage	Improved
Xanthochromia; protein 102 mg/100 ml	Normal	LFC	pituitary decompression	Chromophobe; hemorrhage	Improved, left optic nerve sacrificed at surgery
0	Enlarged; eroded dorsum	RFC	pituitary decompression	Chromophobe; hemorrhage	Improved left eye; blind right eye
0	Enlarged; erosion posterior clinoids	RFC	pituitary decompression	Chromophobe; hemorrhage	Died 5 mo postoperatively; regional ileitis
0	Enlarged; thin posterior clinoids	LFC	pituitary decompression	Chromophobe; necrosis	Total recovery
0	Enlarged; thin posterior clinoids	LFC	pituitary decompression	Chromophobe; hemorrhage	Death 2 wk postoperatively; massive hematemeses
Xanthochromia; protein 50 mg/100 ml	Enlarged	LFC	pituitary decompression	Chromophobe; hemorrhage	Improved
0	Enlarged	RFC	pituitary decompression	Chromophobe; hemorrhage	Improved
0	Enlarged	Endonasal	transsphenoidal decompression	Chromophobe; hemorrhage	Total recovery

Only one patient of those known to have a pituitary tumor had irradiation prior to the apoplectic episode.

Roentgenographic examination.

Skull roentgenograms showed enlargement of the sella turcica in 10 cases. Thinning of the dorsum sellae or erosion of the posterior clinoids or both

were present in all but one of our patients.

Cerebrospinal fluid. The cerebrospinal fluid was examined in four patients prior to surgery and in each the fluid was xanthochromic (cases 2, 3, 4, and 9). The CSF protein in one patient (case 9) was 50 mg/100 ml and in another (case 4) was 102 mg/100 ml.

Contrast studies. Carotid angiography was performed in eight patients, two of whom also had pneumoencephalography. The findings in these studies were consistent with the diagnosis of an expanding intrasellar mass with varying degrees of suprasellar or parasellar extension or both. One patient (case 11) also had evidence of ventricular enlargement with no evidence of air over the convexity. Although there was no history of a similar episode previously, it is quite possible that he had had an unrecognized subarachnoid hemorrhage leading to the development of the so-called "normal pressure hydrocephalus." Lateral or parasellar extension of the tumor was determined by the lateral displacement of the intracavernous portion of internal carotid artery as determined on the carotid arteriogram.

Pathology. Pathologic specimens were obtained at surgery in all cases. A diagnosis of chromophobe adenoma was made in each instance, although in one patient (case 9) there was also a small oxyphilic component. In five patients there was microscopic evidence of necrosis, and in six patients hemorrhage of varying degrees.

Treatment and results. All of our patients but one were surgically treated by a transcranial approach. In the patient whose case history has been described (case 11), the pituitary was decompressed by stereotactic trans-

phenoidal aspiration. Three patients (cases 1, 2, and 5) received radiation therapy following surgery. There were two deaths in the series, neither of which were surgical. One patient (case 6) died 5 months postoperatively from complications of an unrelated regional ileitis. Another patient (case 8) died 2 weeks postoperatively from massive bleeding of the gastrointestinal tract secondary to esophageal varices.

Of the 10 patients who could be evaluated, all were improved following surgical decompression. Recovery of ocular motor deficit was more predictable and occurred earlier than recovery of visual field deficit. One patient (case 2) had presented as an internal carotid aneurysm of the left side with the only deficit being a left third nerve palsy which cleared completely following surgery. A second patient (case 7) who had ptosis OD and bitemporal hemianopsia, recovered completely after pituitary decompression. A third patient (case 11) also recovered completely.

Discussion

Definition. The term apoplexy implies a sudden catastrophe. There are problems in defining which cases should be called pituitary apoplexy, since occasionally similar symptoms may be present in uncomplicated pituitary adenomas. There is also some confusion from the standpoint of pathologic findings, since pituitary tumors are often vascular and may show hemorrhagic cystic areas and chronic degenerative changes. We agree with Rushworth⁴ that it is reasonable to include any patient with a known or unknown pituitary tumor in whom typical headaches, loss of vision, or ophthalmoplegia suddenly develop. It

should be recognized that hemorrhage may occur without apoplexy and apoplexy without hemorrhage. Using these criteria the few reported cases of abscesses within pituitary adenomas, presenting in an abrupt form with the previously mentioned symptoms, should also be included.⁵

Incidence. Henderson⁶ reviewed Harvey Cushing's series of 338 pituitary adenomas and noted that 45 (17%) of 260 chromophobe adenomas and 4 (6%) of 67 eosinophilic adenomas were largely cystic tumors with a large proportion of hemorrhagic cysts. Lopez,⁷ in 1970, collected 2,205 cases of pituitary tumors from the literature and found that 135 were cases of pituitary apoplexy, an incidence of 6%. In other reports, the incidence has varied from 7%⁸ to 20%.⁹

Sex and age. From a review of the literature it would appear that men are affected more often than women, although this is not statistically significant. In our patients we were impressed by the significantly younger age of the women at the time of the apoplectic episode. In a random review of the literature^{2, 4, 7, 9-27} we studied the age and sex of 73 cases including our 11 cases. There were 44 men and 29 women; the mean age at onset was 50.9 years for men and 39.0 years for women. In contrast, when age and sex were studied in 153 patients with consecutive uncomplicated pituitary adenomas seen at the Cleveland Clinic, the mean age for 82 men was 45.88 years, and for 71 women it was 45.96 years. Women when affected are significantly younger than men.²⁸ In future cases it should be interesting to evaluate the relationship, if any, of the onset of pituitary apoplexy to pregnancy or time of the menstrual cycle,

particularly since previous reports have emphasized the role of estrogen therapy as a predisposing factor for pituitary apoplexy.²⁸

Histology. Pituitary apoplexy has been reported in cases of chromophobe adenomas, eosinophilic adenomas, basophilic adenomas, mixed cell adenomas, meningiomas and malignant tumors.⁷ Review of the literature disclosed conflicting opinions. Some investigators have suggested that the incidence of pituitary adenomas is proportionally higher in patients with pituitary adenomas who have acromegaly or Cushing's syndrome, compared to those with nonsecreting chromophobe adenomas.^{2, 10, 18, 24} Others have felt that there is predominance in chromophobe adenomas.¹⁹ All of our patients except perhaps one (case 8) had nonsecreting chromophobe adenomas.

Predisposing factors. There have been many predisposing factors in the development of pituitary apoplexy, such as trauma,^{7, 29} hypertension,² radiotherapy,^{2, 3, 8, 15, 20, 25, 30} and estrogen therapy.²⁸ In addition, a typical clinical picture of pituitary apoplexy with an abscess in a pituitary adenoma has been reported.⁵ Probably, the only undisputed cause or factor is the previous use of anticoagulants in two patients.^{25, 31} In a recent report on five patients in whom pituitary apoplexy developed following a common cold, it has been postulated that an increased venous pressure in the tumor, secondary to chronic coughing and sneezing, could account for the apoplexy in those cases.¹³ In this respect, it is interesting that pituitary apoplexy developed in one patient (case 8) following repeated bouts of coughing and

vomiting caused by bleeding from the upper gastrointestinal tract.

Whatever the manifestation, i.e., hemorrhage or necrosis or both, the apoplectic event may be related to ischemic necrosis because the growing adenoma outstrips its blood supply.^{2, 3, 15, 20} Others have postulated a primary abnormality of the adenomatous blood vessels as a cause.³⁰ Undoubtedly, in some cases expansion of the tumor in its confined cavity aggravates the compressive ischemia.

In our experience it has been rare to find extensive hemorrhagic necrosis in adenomas with large suprasellar extension. We believe that two factors, namely rapid tumor growth and confinement within the dura bone boundaries of the pituitary fossa, particularly in cases when a small diaphragma sellae is present, play a leading role in the development of pituitary apoplexy. Once infarction has occurred, the tumor becomes a necrotic or hemorrhagic mass which rapidly expands beyond the size of the original adenoma. This extension may be purely intracapsular, in which case the prognosis is certainly better. An example of this is the patient (case 5) in whom the apoplectic episode could be traced back 3 months before surgery when he was seen with homonymous hemianopsia.

The apoplectic adenoma may also extend in a suprasellar fashion, with the resultant spillage of blood into the subarachnoid space occasionally simulating subarachnoid hemorrhage from a ruptured intracranial aneurysm. A third pathway of extension could be into the cavernous sinus with the production of either a cavernous sinus syndrome, or a syndrome of parasellar venous tamponade. In such a

case, the appearance of paralysis of the ocular nerves may be the first evidence of a pituitary tumor as first reported by Foix.³² He described a case in which a pituitary adenoma manifested itself by severe, unilateral pain in the forehead (trigeminal, first division) and then by rapidly progressive ipsilateral paralysis of the third nerve and later of the fourth and sixth nerves. Although not described as such he probably was describing a case of pituitary apoplexy. In 1940 Weinberger et al³³ reported 14 cases of pituitary adenoma producing a cavernous sinus syndrome. Reading their description and operative findings in these patients, we have the impression that six of them (cases 1, 4, 7, 8, 9, and 12) could have been cases of pituitary apoplexy. Furthermore, two of the patients (cases 1 and 4) had proptosis. The occurrence of proptosis in pituitary apoplexy has not been emphasized; furthermore, its presence in cases of uncomplicated pituitary adenomas has received only scant mention. In a series of 50 cases of pituitary adenomas reported by Walsh,²⁶ two patients had proptosis. In our series of 11 patients two (cases 1 and 4) had proptosis. We are aware that a patient with a third nerve paralysis, regardless of the cause, may have as much as 3 mm of exophthalmia, secondary to relaxation of the paralyzed muscles. This would probably be even larger in cases of total ophthalmoplegia. This condition, i.e., total ophthalmoplegia as well as proptosis, was present in one patient (case 1). We postulate that the sudden expansion of the tumor into the cavernous sinus could conceivably occlude its multiple venous channels, thus producing a syndrome of parasellar venous tamponade with attendant

proptosis. Symptoms and signs referable to involvement of the fifth nerve in the cavernous sinus have been reported in only a few cases.^{18, 21}

Roentgenographic studies

Angiography is indicated in every case, since aneurysms of the internal carotid artery may occasionally produce similar changes on plain roentgenograms and a similar clinical picture. These roentgenographic changes include enlargement of the sella, displacement or erosion of the anterior clinoid and occasionally the optic strut, and enlargement of the superior orbital fissure. It is interesting that in two reports of pituitary apoplexy, spasm of the intracranial internal carotid artery was noted preoperatively. It has been postulated that this may be due to blood in the cerebrospinal fluid or to local irritation of the intracavernous portion of the internal carotid artery.^{17, 24}

Symptoms and signs. Pituitary apoplexy may be the first indication that a patient has a pituitary adenoma or it may be a startling culmination of a previously known clinical syndrome of endocrinopathy or visual disturbance. Symptoms may be grouped as follows: (1) Acute headaches which are usually bifrontal. They may be lateralized to one eye and occasionally even located in the vertex or suboccipital region. Headaches may be due to meningeal irritation by escape of blood into the subarachnoid space or by acute distention of the adenoma stretching the dura coverings of the pituitary gland. (2) Compression of optic pathways. (3) Cavernous sinus involvement with ophthalmoplegia. (4) Alterations of the level of consciousness. (5) Endocrinopathy.

Therapy. Analysis of the early literature suggests that some patients surviving the initial apoplectic episode may show improvement of vision either spontaneously or following delayed intervention. Krueger et al.³⁴ collected 36 conservatively treated cases from the literature; 22 of those patients died within a few hours to a month after the onset of the insult. Of those who survived, improvement of vision or ocular movements or both were noted in at least nine patients.

In a recent report, delay of up to 10 days before surgery was not harmful in three of five patients, and visual improvement had occurred preoperatively in two patients.¹³ Spontaneous improvement has also been observed by other authors.^{2, 16, 27}

With the introduction of clinical use of corticosteroids in neurosurgery the management of these patients has certainly improved. Although visual loss secondary to compression of the optic chiasm is still an indication for emergency surgery, surgical intervention in other cases may now be considered less urgent when the patient is receiving protective cover of steroids, thus giving the surgeon time to correct metabolic and electrolytic imbalance. The patient should receive replacement hormones, and it is our practice to use large doses of dexamethasone parenterally.

Most of the surgically treated cases reported in the literature have undergone either a right or left frontal craniotomy, according to the side of greater extension of the adenoma. For the past few years, we have been approaching the sellar region exclusively from the right side, regardless of the side of greater visual deficit.

Recently, two cases have been re-

ported in which pituitary decompression was accomplished through a trans-septal transphenoidal approach.^{17, 24} We have used a stereotactic transphenoidal approach with a guide and image intensifier monitor for the decompression of pituitary tumors and intrasellar biopsy. We think this approach, as used in one patient (case 11), is advantageous in patients with pituitary apoplexy because of its simplicity and low morbidity.

Summary

Eleven cases of pituitary apoplexy are reported. The pituitary tumor was previously undiagnosed in seven patients. The clinical picture of sudden headache, ophthalmoplegia, visual defect, and alteration in consciousness is described. The presence of exophthalmos in two patients is noted. In this series and in a review of the literature it is apparent that women when affected are significantly younger than men.

All of these 11 cases were treated surgically, and in each a chromophobe adenoma which had undergone varying degrees of hemorrhage or necrosis or both was revealed. A new method of successful treatment by stereotactic transphenoidal aspiration is described.

References

1. Bleibtreu L: Ein Fall von Akromegalie (Zerstörung der Hypophysis durch Blutung). *München Med Wchnschr* 41: 2079, 1905.
2. Brougham M, Heusner AP, Adams RD: Acute degenerative changes in adenomas of the pituitary body—with special reference to pituitary apoplexy. *J Neurosurg* 7: 421-439, 1950.
3. Uihlein A, Balfour WM, Donovan PF: Acute hemorrhage into pituitary adenomas. *J Neurosurg* 14: 140-151, 1957.
4. Rushworth RG: Pituitary apoplexy. *Med J Aust* 1: 251-254, 1971.
5. deVilliers Hammann H: Abscess formation in the pituitary fossa associated with a pituitary adenoma. *J Neurosurg* 13: 208-210, 1956.
6. Henderson WR: The pituitary adenomata; a follow-up study of the surgical results in 338 cases (Dr. Harvey Cushing's series). *Br J Surg* 26: 811-921, 1939.
7. Lopez IA: Pituitary apoplexy. *J Oslo City Hosp* 20: 17-27, 1970.
8. Fager CA: Intrasellar surgical lesions, cystic and hemorrhagic adenomas requiring surgery after x-ray therapy. In, *Surgical Practice of the Lahey Clinic*. Philadelphia, WB Saunders, 1960, pp 26-35.
9. Dastur HM, Pandya SK: Haemorrhagic adenomas of the pituitary gland; their clinical and radiological presentations and treatment. *Neurol India* 19: 4-12, 1971.
10. Argires JP, Nelson J: Pituitary apoplexy; review of the literature and two case reports. *South Med J* 59: 785-789, 1966.
11. Benjamin JE: Pituitary tumor with fulminating symptoms. *JAMA* 92: 1755-1758, 1929.
12. Coxon RV: A case of haemorrhage into a pituitary tumour simulating rupture of an intracranial aneurysm. *Guy's Hosp Rep* 92: 89-93, 1943.
13. Dawson BH, Kothandaram P: Acute massive infarction of pituitary adenomas. A study of five patients. *J Neurosurg* 37: 275-279, 1972.
14. Dingley LA: Sudden death due to a tumour of the pituitary gland. *Lancet* 2: 183-184, 1932.
15. Epstein S, Pimstone BL, de Villiers JC, et al: Pituitary apoplexy in five patients with pituitary tumours. *Br Med J* 2: 267-270, 1971.
16. Fountain EM, Baird WC, Poppen JL: Pituitary apoplexy; a report of 3 cases with recovery. *Lahey Clin Bull* 7: 117-122, 1951.
17. Goodman JM, Gilson M, Shapiro B: Pituitary apoplexy—a cause of sudden blindness. *J Indiana State Med Assoc* 66: 320-321, 1973.
18. Guarnaschelli JJ, Talalla A: Pituitary apoplexy; a case report. *Bull Los Angeles Neurol Soc* 37: 12-18, 1972.
19. Jefferson M, Rosenthal FD: Spontaneous

- necrosis in pituitary tumours (pituitary apoplexy). *Lancet* **1**: 342-344, 1959.
20. List CF, Williams JR, Balyeat GW: Vascular lesions in pituitary adenomas. *J Neurosurg* **9**: 177-187, 1952.
 21. Locke S, Tyler HR: Pituitary apoplexy; report of two cases with pathological verification. *Am J Med* **30**: 643-648, 1961.
 22. Rigolosi RS, Schwartz E, Glick SM: Occurrence of growth-hormone deficiency in acromegaly as a result of pituitary apoplexy. *N Engl J Med* **279**: 362-364, 1968.
 23. Robinson JL: Sudden blindness with pituitary tumors; report of three cases. *J Neurosurg* **36**: 83-85, 1972.
 24. Rovit RL, Fein JM: Pituitary apoplexy; a review and reappraisal. *J Neurosurg* **37**: 280-288, 1972.
 25. Shenkin HA: Relief of amblyopia in pituitary apoplexy by prompt surgical intervention. *JAMA* **159**: 1622-1624, 1955.
 26. Walsh FB: Bilateral total ophthalmoplegia with adenoma of the pituitary gland; report of two cases; an anatomic study. *Arch Ophthalmol* **42**: 646-654, 1949.
 27. Wright RL, Ojemann RG, Drew JH: Hemorrhage into pituitary adenomata; report of two cases with spontaneous recovery. *Arch Neurol* **12**: 326-331, 1965.
 28. David M, Philippon J, Bernard-Weil E: Les formes hémorragiques des adénomes hypophysaires. Aspects cliniques et étiologiques. *Presse Med* **77**: 1887-1889, 1969.
 29. Van Wageningen WP: Hemorrhage into pituitary tumor following trauma. *Ann Surg* **95**: 625-628, 1932.
 30. Müller W, Pia HW: Zur Klinik und Ätiologie der Massenblutungen in Hypophysenadenome. *Deut Zschr Nervenhe* **170**: 326-336, 1953.
 31. Nourizadeh AR, Pitts FW: Hemorrhage into pituitary adenoma during anticoagulant therapy. *JAMA* **193**: 623-625, 1965.
 32. Foix C: Syndrome de paroi externe du sinus caverneux. (Ophthalmoplégie unilatérale à marche rapidement progressive. Algie du territoire de l'ophtalmique). Amélioration considérable par le traitement radiothérapique. *Rev Neurol Par* **29**: 827-832, 1922.
 33. Weinberger LM, Adler FH, Grant FC: Primary pituitary adenoma and the syndrome of the cavernous sinus; a clinical and anatomic study. *Arch Ophthalmol* **24**: 1197-1235, 1940.
 34. Krueger EG, Unger SM, Roswit B: Hemorrhage into pituitary adenoma with spontaneous recovery and reossification of the sella turcica. *Neurology (Minneapolis)* **10**: 691-696, 1960.